



Variant position of the medial plantar nerve

Published online January 14th, 2011 © <http://www.ijav.org>

Rajesh B. ASTIK ⁺
 Urvi H. DAVE
 Krishna Swami GAJENDRA

Department of Anatomy, GSL Medical College, Rajahmundry, District- East Godavari,
 Andhra Pradesh, INDIA.



⁺ Dr. Rajesh B. Astik
 Associate Professor
 Department of Anatomy
 GSL Medical College
 NH-5, Rajahmundry
 District- East Godavari,
 Andhra Pradesh, 533206, INDIA.
 ☎ +91 883 2484989
 ✉ astikrajesh@yahoo.co.in

Received July 13th, 2010; accepted December 31st, 2010

ABSTRACT

Knowledge of variation of position of the medial plantar nerve is important for the forefoot surgeon for plantar reconstruction, local injection therapy and an excision of interdigital neuroma. During routine dissection of 50-year-old female cadaver, we found the medial plantar nerve and vessels variably located between plantar aponeurosis and the muscles of the first layer of the sole of the right foot. Due to this variant position, the medial plantar nerve and vessels lose their protection from the muscles of the first layer of the sole of the foot and became vulnerable for compression. © IJAV. 2011; 4: 1–2.

Key words [medial plantar nerve] [plantar aponeurosis] [abductor hallucis] [entrapment neuropathy]

Introduction

The divisions of the tibial nerve and posterior tibial artery take place in the tarsal tunnel and this neurovascular bundle lies between the first and the second layer of the sole of the foot upon the long tendons of the foot [1].

The variant position of the lateral plantar nerve and vessels in the sole of the foot is documented in the past. The present paper refers to variant position of the medial plantar nerve and vessels.

Case Report

We described a rare variation in the position of the medial plantar nerve and vessels in the right foot during routine educational dissection of a 50-year-old female cadaver in the Department of Anatomy, GSL Medical College.

The medial plantar nerve and vessels were located superficial to the first layer of the sole between the plantar aponeurosis and abductor hallucis muscle. The muscular branches to the abductor hallucis from the medial plantar nerve entered into the muscle from its superficial surface instead of its deep surface (Figure 1).

The distribution and remaining branches of the medial plantar nerve were as per described in the standard textbooks of anatomy.

Discussion

The tarsal tunnel rarely extended anteriorly under the fascia of the abductor hallucis. In a cadaveric study, Heimkes et al. found two distinctly separated narrow tunnels in abductor hallucis fascia for the individual plantar nerves. They named this the distal tarsal tunnel with the proximal tarsal tunnel under the flexor retinaculum [2].

Govsa et al. demonstrated the vulnerable position of the medial plantar nerve and its muscular branches in the distal tarsal tunnel. They suggested that entrapment of these nerves may be involved in medial heel pain including plantar fasciitis, heel pain syndrome and fat pad disorders [3].

Katirji et al. stated that compression in the distal tarsal tunnel results into ischemia of the medial plantar nerve and its branches, and leads to distal tarsal tunnel syndrome. Extrinsic compression or local factors include abductor hallucis hypertrophy, tumors, ganglia or hemorrhage from trauma. They reported that patients present with an insidious onset of sensory and motor symptoms. Burning foot pain worse on walking is characteristic. Treatment depends on the etiology. Non-surgical treatment included anti-inflammatory medicines or orthotics. Resistant idiopathic cases may be treated by decompression of the distal tarsal tunnel around the abductor hallucis fascia [4].

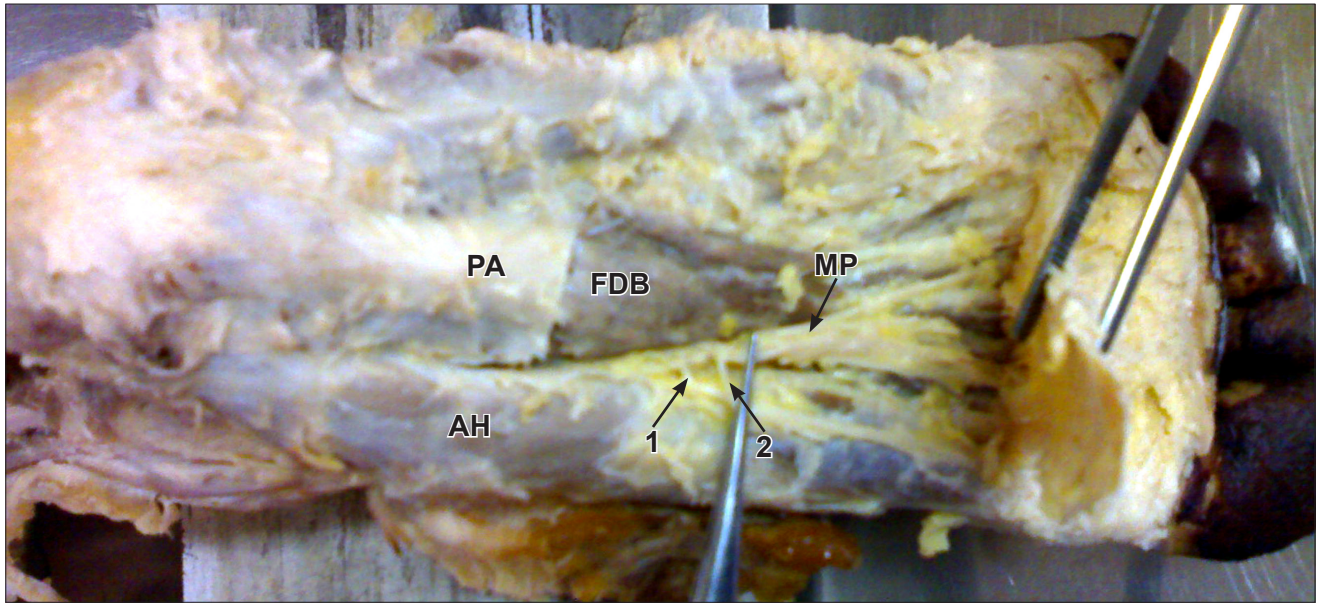


Figure 1. Medial plantar vessels and nerve lying between plantar aponeurosis and first layer muscle of the sole of the right foot. (*1 & 2: muscular branches to abductor hallucis; FDB: flexor digitorum brevis muscle; PA: plantar aponeurosis; AH: abductor hallucis; MP: medial plantar nerve & vessels*)

The medial plantar nerve may be compressed in the distal tarsal tunnel. So this case report is an example of a rare variation in the position of the medial plantar nerve in the sole of the foot. The knowledge of the entrapment is important for the forefoot and plastic surgeons.

Conclusion

Knowledge of the variation in the position of the medial plantar nerve may prevent neuroma formation during surgery, provide insight into the variability of the heel symptoms associated with the entrapment neuropathy in the

distal tarsal tunnel and neurovascular island flaps from the large, second and third toes used for the resurfacing defects on the plantar aspect of the foot.

Acknowledgements

Our sincere thanks to all the people who helped and supported during the writing of this manuscript. We would thank our institution for allowing us to dissect cadavers and faculty members without whom this manuscript would have been a distant reality.

References

- [1] McMinn RMH. *Last's Anatomy: Regional and applied*. 8th Ed., London, ELBS, Churchill Livingstone. 1990; 202.
- [2] Heimkes B, Posel P, Stotz S, Wolf K. The proximal and distal tarsal tunnel syndromes. *Int Orthop*. 1987; 11: 193–196.
- [3] Govsa F, Bilge O, Ozer MA. Variations in the origin of medial and inferior calcaneal nerves. *Arch Orthop Trauma Surg*. 2006; 126: 6–14.
- [4] Katirji B, Wilbourne AJ, Dyck PJ, Thomas PK. *Peripheral Neuropathy*. 4th Ed., Philadelphia, Elsevier Saunders. 2005; 1487–1511.