

Variant origin and course of the left colic artery: An embryological perspective

Vivek Mishra, Mrinal Barua, Brijendra Singh, Vandana Sharm

Mishra V, Barua M, Singh B, et al. Variant origin and course of the left colic artery: An embryological perspective. *Int J Anat Var.* 2018;11(1): 24-25.

ABSTARCT

The Variations in branching pattern of abdominal arteries are common. These variations are usually due to the changes occurring during the development of vessels. Although the blood supply of the gut is segmental in nature and is genetically regulated, there are other factors determining the final fate of the course and origin of a blood vessel. In this case report the left colic artery was observed to arise anomalously from superior mesenteric artery; 4 cm

distal to the origin of superior mesenteric artery from the abdominal aorta – a rare anomaly. The utmost care and proper attention is much needed while doing various diagnostic techniques, operative procedures and angiographic examinations of abdominal organs rather than merely the knowledge of all reported or unreported variations of the abdominal arteries. It should be kept in mind that variations in the abdominal blood vessels are a proof of concept of vascular development.

Key Words: Variations; Abdominal arteries; Left colic artery; Angiogenesis; Anastomosis

Abbreviations: LCA: Left Colic Artery.

INTRODUCTION

Variations in branching pattern of abdominal vessels are common. Many factors regulate the final course and distribution pattern of blood vessels of gut, so utmost care and attention is needed while performing operative procedures, angiographic examination and other diagnostic techniques in abdomen. Here we have described anomalous origin and course of left colic artery during routine dissection at department of anatomy.

CASE REPORT

We describe a variation in the origin and course of the left colic artery (LCA) observed during routine dissection of a 45 year old male cadaver received in department of anatomy, All India Institute of Medical Sciences, Rishikesh. Cadaver was of North India Punjab region obtained through voluntary body donation programme and was formalin fixed for routine undergraduate dissection for teaching. During dissection LCA was observed to arise anomalously from superior mesenteric artery; 4 cm after the latter's origin from the abdominal aorta. In its course to supply the descending colon, the LCA crossed the abdominal aorta from the right to left (Figure 1). The left colic artery then divided in to ascending and descending branches. There was no separate left colic artery from the inferior mesenteric artery. The superior mesenteric artery and its branches were unremarkable in its distribution and supply. No other remarkable vascular anomaly was noted.

DISCUSSION

The variations in the origin of abdominal blood vessels are very common observation. Among the reported variations, the variations of the left colic artery are however, extremely rare. The left colic artery (LCA) usually arise from Inferior mesenteric artery and divides into ascending and descending branches to supply left one third of transverse colon, upper part of descending colon and lower part of descending colon respectively (1). Rusu MC has reported the presence of an aberrant accessory left colic artery (2). It originated from the superior mesenteric artery about 3 cm proximal to the middle colic artery. It reached the colon by passing over the Treitz's muscle. Jiji PJ observed a case of anastomosis between the left colic artery and dorsal pancreatic artery (3). Origin of the left colic artery as a branch of celiacomesenteric trunk has also been reported recently (4). Origin of the left colic artery from superior mesenteric artery is seen in less than 1% of cases. Kim DH has reported such a case from Korea (5).

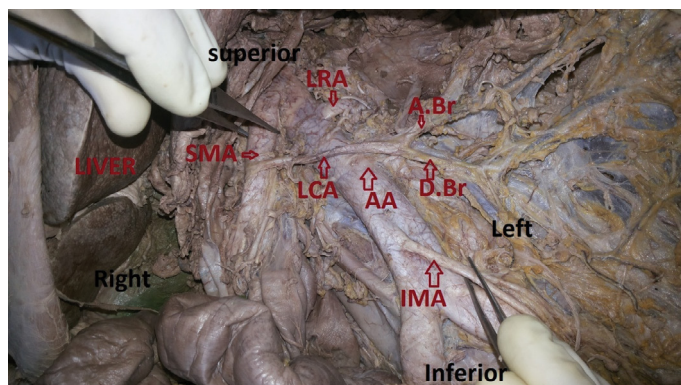


Figure 1) The superior mesenteric artery and its branches

At the early stage of human development, the cells are arranged into inner cell mass called embryoblast forming the intraembryonic tissues and another surrounding cell called trophoblast constituting extraembryonic tissues. The earliest blood vessels of the embryo are derived by vasculogenesis in both intra- and extra embryonic tissues (6). These blood vessels are the heart tubes, dorsal aortae, umbilical vessels and the vitelline vessels (7). Subsequent developments of blood vessels are by a process of angiogenesis in which endothelial sprouts form in the splanchno-pleuric mesoderm (8). As a result of this the initial supply of any abdominal organ is by a plexus of blood vessels or capillaries and the source of blood supply could be determined by proximity of the structure to already established blood vessels which have developed by vasculogenesis.

The segmental nature of blood supply to the gut is a known feature. During intrauterine life, mesenteric blood vessels develop as multiple paired ventral segmental arteries arising from the right and left dorsal aortae which are interconnected by longitudinal anastomoses. Fusion of aortae to form a single vessel result in formation of three unpaired vessels i.e., celiac trunk, superior mesenteric artery and longitudinal anastomoses between these vessels disappear (9). The presence of the LCA as in this case may result from persistence of these primitive longitudinal anastomoses. Whether the final fate of the course and origin of blood vessels in the abdomen is genetically

Anatomy Department, All India Institute of Medical Sciences, Rishikesh, Uttarakhand 249201, India.

Correspondence: Dr. Vivek Mishra, Associate Professor, Anatomy Department, All India Institute of Medical Sciences, Rishikesh, Uttarakhand 249201, India, Tel: 918958285555; e-mail: vivmishraek@yahoo.co.in

Received: January 06, 2018, Accepted: February 13, 2018, Published: February 24, 2018



This open-access article is distributed under the terms of the Creative Commons Attribution Non-Commercial License (CC BY-NC) (<http://creativecommons.org/licenses/by-nc/4.0/>), which permits reuse, distribution and reproduction of the article, provided that the original work is properly cited and the reuse is restricted to noncommercial purposes. For commercial reuse, contact reprints@pulsus.com

determined or it is secondary to the position of abdominal viscera during the process of angiogenesis and after that, is a matter of speculation (10). The enormous number of variations in the course and origin of the gut arteries could be due to the fact that as the gut is mobile throughout intrauterine life, the final preferential course and origin of the arteries could be determined by a lot of factors of which position of the viscera seems most plausible.

CONCLUSION

Variation in abdominal vessels is a frequently encountered feature. Superior mesenteric artery and its branches is most commonly used vessel in many surgical and radiological procedures. Left colic artery may arise from superior mesenteric artery, as in this case. Variations in the branching pattern or position and course of blood vessels can affect routine clinical procedures like laparoscopic interventions. The key to a good surgical practice and diagnostic procedures is not to be guided by specific reported variations but rather exercise utmost care during dissection keeping in mind that variations in the abdominal blood vessels are a proof of concept of vascular development in humans.

REFERENCES

1. Standring S. The anatomical basis of clinical practice, gastrointestinal tract. Gray's anatomy. 1146-9.
2. Rusu MC, Vlad M, Voinea LM, et al. Detailed anatomy of a left accessory aberrant colic artery. Surg Rad Anat. 2008;30:595-9.
3. Jiji PJ, Nayak SR, Costa SD, et al. A variant of Buhler's arc formed by the unusually long dorsal pancreatic artery. Bratislavské Lekárske Listy. 2008;109:283-4.
4. Hideki K, Koichiro I, Tatsuo S. A case of celiaco-mesenteric trunk with some other arterial anomalies in a Japanese woman. Anat Sci Int. 2007;82:53-8.
5. Kim DH, Jin C, Jung YW, et al. The accessory left colic artery arising from the superior mesenteric artery- A case report. Korean J Anat. 2009;42:209-12.
6. Hegazy A. Clinical Embryology for medical students and postgraduate doctors. LAP Lambert Academic Publishing, Berlin.
7. Risau W. Mechanisms of angiogenesis. Nature. 1997;17; 386:671-4.
8. Selvaraj L, Sundaramurthi. Study of Normal Branching Pattern of the Coeliac Trunk and its Variations Using CT Angiography. JCDR. 2015;9:1-4.
9. Lucitti JL, Jones EA, Huang C, et al. Vascular remodeling of the mouse yolk sac requires hemodynamic force. Development. 2007;134:3317-26.
10. Jones EA, le Noble F, Eichmann A. What determines blood vessel structure? Genetic pre specification vs. hemodynamics. Physiology (Bethesda). 2006;21:388-95.