



## Unusual origin of the radial artery

Published online June 2nd, 2011 © <http://www.ijav.org>Balachandra N <sup>+</sup>

Prakash BS

Padmalatha K

BR Ramesh

Department of Anatomy, Dr. B. R. Ambedkar Medical College, Bengaluru, Karnataka, INDIA.



<sup>+</sup> Dr. Balachandra N, MBBS, MD  
Assistant Professor  
Department of Anatomy  
Dr. B.R. Ambedkar Medical College  
Bengaluru, Karnataka, INDIA.  
☎ +91 80 9886592995  
✉ chandu1984@hotmail.com

Received August 19th, 2010; accepted May 21st, 2011

### ABSTRACT

Knowledge of the variations in the origin of the radial artery is important as they are used in various clinical procedures like vascular and reconstructive surgeries. Moreover, superficial course of this artery makes it vulnerable to accidental injuries as it may be mistaken as a vein and intravenous injections to it can be disastrous. Here we described a variation in the origin of the radial artery from the third part of the axillary artery. During routine dissection of a male cadaver aged about fifty years by the undergraduate students of our college, the radial artery was seen to be arising from the third part of the radial artery in the left upper limb. It was passing between the two roots of the median nerve superficial to biceps brachii muscle. In the cubital fossa it communicated with the ulnar artery. It traversed superficially in the forearm and terminated in the hand by forming the deep palmar arch with the deep branch of the ulnar artery. © IJAV. 2011; 4: 101–103.

**Key words** [brachioradial artery] [radial artery] [axillary artery] [median nerve] [ulnar artery]

### Introduction

Radial artery is one of the terminal branches of the brachial artery arising in the cubital fossa; the other being the ulnar artery. Radial artery usually begins in the cubital fossa about 1 cm below the bend of the elbow at the level of the neck of the radius just medial to the tendon of biceps brachii muscle, and terminates in the hand by forming the deep palmar arch after anastomosing with the deep branch of the ulnar artery [1].

### Case Report

In one cadaver the radial artery was seen arising from the third part of the axillary artery proximal to the union of the two roots of the median nerve (Figure 1). From there it was seen passing between the two roots of the median nerve superficial to both the median nerve and the brachial artery. It then crossed over from medial to the lateral side of the arm superficial to biceps brachii muscle (Figure 2). In the cubital fossa it communicated with ulnar artery via a communicating branch (Figure 3). In the forearm, it descended superficially in the lateral part and entered the hand superficial to the flexor retinaculum and entered the anatomical snuffbox (Figure 4). Finally it terminated by forming the deep palmar arch completed by the deep branch of ulnar artery.

### Discussion

Variations in the origin of the radial artery have been reported widely. They arise from the brachial artery very frequently but their origin from the axillary artery are less frequent, comparatively.

Quain reported high origin of radial artery in 1 out of 8 cases. Among these, the artery arose more commonly from the axillary than from the brachial artery [2].

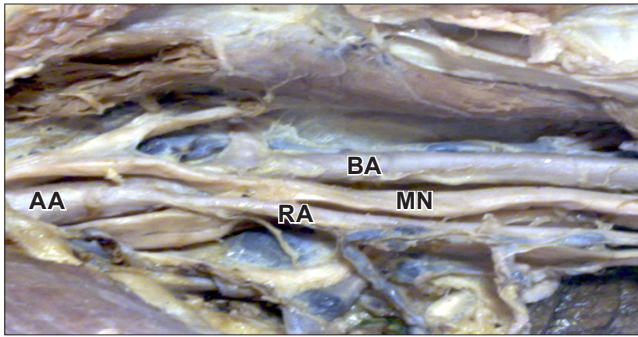
Giacomini studied 270 dissected cases, out of which 148 cases showed high origin of the radial artery. Among these 148 cases, he reported 43 cases with radial artery arising from axillary artery [2].

Similarly, Dubreuil and Chamberdel reported 72 cases of high origin of radial artery out of 136 cases and among these 19 were arising from the axillary artery [2].

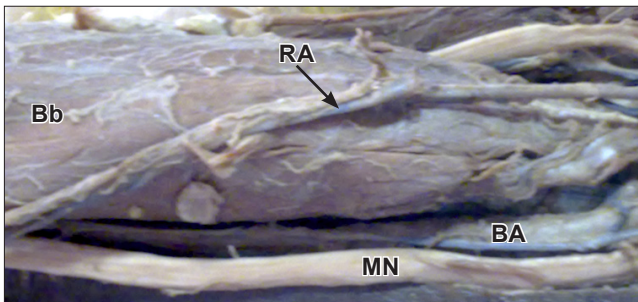
Gonzalez-Compta reported vascular variations of the hand in association with radial artery arising from the axillary artery [3].

Icten et al. found the radial artery arising from the axillary artery bilaterally in a cadaver [4].

Rodriguez-Niedenfuhr et al. named the radial artery arising in the arm as the brachioradial artery and reported 12 upper limbs showing the radial artery arising from the axillary artery among 192 upper limbs [5].



**Figure 1.** Radial artery at its origin from third part of axillary artery. (AA: axillary artery; RA: radial artery; BA: brachial artery; MN: median nerve)



**Figure 2.** Radial artery in the arm. (RA: radial artery; BA: brachial artery; MN: median nerve; Bb: biceps brachii muscle)

Okoro and Jiburum have reported an incidence of radial artery arising from the axillary artery bilaterally in an adult Nigerian cadaver [6].

Loukas et al. have reported a case of radial artery arising from the thoracoacromial trunk [7].

Konarik et al. have reported an incidence of 3% in the origin of the radial artery from the axillary artery [8].

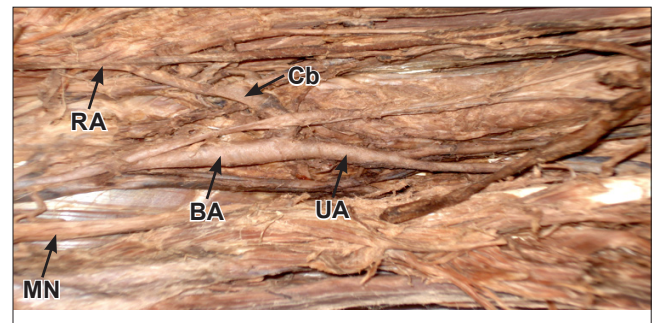
Manners-Smith classified the variants of the radial artery into 2 groups. ( According to them human development is similar to that of the primates.) The type 1 variant is more common and involves a single dorsal division. In the second type, the dorsal branch of the superficial brachial artery divides during the embryonic period into 2 terminal branches, superficial and deep. The superficial brachial artery has 2 anastomoses during its development, one at the level of the elbow with the brachial artery, the other in the forearm with the median artery. The superficial branch regresses and disappears whereas the deep branch enlarges and takes over the territory of the superficial branch to become the normal adult human radial artery. Persistence of the superficial branch gives rise to anomalies. The presence of these variants poses problems, (1) with radial forearm free

flaps and (2) due to their proximity to intravenous infusion sites [9].

Accidental puncture of superficially placed arteries may occur while attempting venipuncture. They are also susceptible to damage in orthopedic and plastic surgery operations [10]. Unusual origin of the radial artery may cause the failure of the radial approach of the coronary angiography and in the reconstructive surgery of the upper limb, it can be ligated or cut considering it as a vein leading to disorder in circulation of the hand. When the superficial artery persists it is more vulnerable to the accidental injuries, it can be easily mistaken as a vein and intravenous injections into it can be disastrous [10].

### Conclusion

Radial artery arising from the third part of the axillary artery has a superficial course in the arm as well as the forearm. This is due to persistent superficial branch of the brachial artery during development. The knowledge of variations in the origin of the radial artery is of importance in vascular and reconstructive surgeries. It is used as a useful vascular conduit for coronary bypass grafting with a very good midterm patency rate. Unusual origin of the radial artery may cause the failure of the radial approach of the coronary angiography and in the reconstructive surgery of the upper limb. These variations have to be kept in mind during orthopedic surgeries. Intravenous injections to a superficial artery can be disastrous as these arteries can be confused for veins.



**Figure 3.** Radial artery in cubital fossa. (RA: radial artery; BA: brachial artery; Cb: communicating branch; UA: ulnar artery; MN: median nerve)



**Figure 4.** Radial artery in forearm. (RA: radial artery; UA: ulnar artery)

## References

- [1] Standring S. *Gray's Anatomy: Anatomical Basis of Clinical Practice*. 39th Ed., London, Elsevier Churchill-Livingstone. 2005; 863.
- [2] Bergman RA, Thomson SA, Afifi AK, Saadeh FA. *Compendium of Human Anatomic Variation*. Baltimore, Urban & Schwarzenberg. 1988; 109.
- [3] Gonzalez-Compta X. Origin of the radial artery from the axillary artery and associated hand vascular anomalies. *J Hand Surg Am*. 1981; 16: 293–296.
- [4] Icten N, Sullu Y, Tuncer I. Variant high-origin radial artery: a bilateral case. *Surg Radiol Anat*. 1996; 18: 63–66.
- [5] Rodriguez-Niedenfuhr M, Vazquez T, Nearn L, Ferreira B, Parkin I, Sanudo JR. Variations of the arterial pattern in the upper limb revisited: a morphological and statistical study, with a review of the literature. *J Anat*. 2001; 199: 547–566.
- [6] Okoro IO, Jiburum BC. Rare high origin of the radial artery: a bilateral, symmetrical case. *Nig J Surg Res*. 2003; 5: 70–72.
- [7] Loukas M, Louis RG Jr, Almond J, Armstrong T. A case of an anomalous radial artery arising from the thoracoacromial trunk. *Surg Radiol Anat*. 2005; 27: 463–466.
- [8] Konarik M, Knize J, Baca V, Kachlik D. Superficial brachioradial artery (radial artery originating from the axillary artery): a case-report and its embryological background. *Folia Morphol (Warsz)*. 2008; 68: 174–178.
- [9] Wood SJ, Abrahams PH, Sanudo JR, Ferreira BJ. Bilateral superficial radial artery at the wrist associated with a radial origin of a unilateral median artery. *J Anat*. 1996; 188: 691–693.
- [10] Waghmare JE, Tarnekar AM, Sonatake BR, Bokariya P, Ingole IV. A high origin of radial artery with asymmetrical vasculature of upper limbs: a case report. *Nepal Med Coll J*. 2008; 11: 284–286.