

## Unusual looping of the internal carotid artery in relation to an enlarged lymph node

Published online June 16th, 2010 © <http://www.ijav.org>

Satheesha NAYAK B. †

### ABSTRACT

Knowledge of variations of internal carotid artery is important to surgeons doing head and neck surgery as well as to radiologists doing imaging and invasive techniques. In the current case, the right internal carotid artery showed a characteristic loop at its beginning. An abnormal, enlarged lymph node was found at the carotid bifurcation, which was projecting into the loop. The left internal carotid artery was normal. The unusual looping of internal carotid artery at its beginning might result in altered blood flow to the brain and may lead to confusions in surgical, imaging and invasive techniques. © IJAV. 2010; 3: 84–85.

Department of Anatomy, Melaka Manipal Medical College (Manipal Campus) Manipal, INDIA.



† Satheesha Nayak B., MSc, PhD  
 Professor of Anatomy  
 Melaka Manipal Medical College (Manipal Campus)  
 International Centre for Health Sciences  
 Madhav Nagar, Manipal  
 Udupi District, Karnataka State, 576 104, INDIA.  
 ☎ +91 820 2922519  
 ☎ +91 820 2571905  
 ✉ [nayaksathish@yahoo.com](mailto:nayaksathish@yahoo.com)

Received October 30th, 2009; accepted June 8th, 2010

**Key words** [variation] [artery] [internal carotid artery] [deep cervical lymph node]

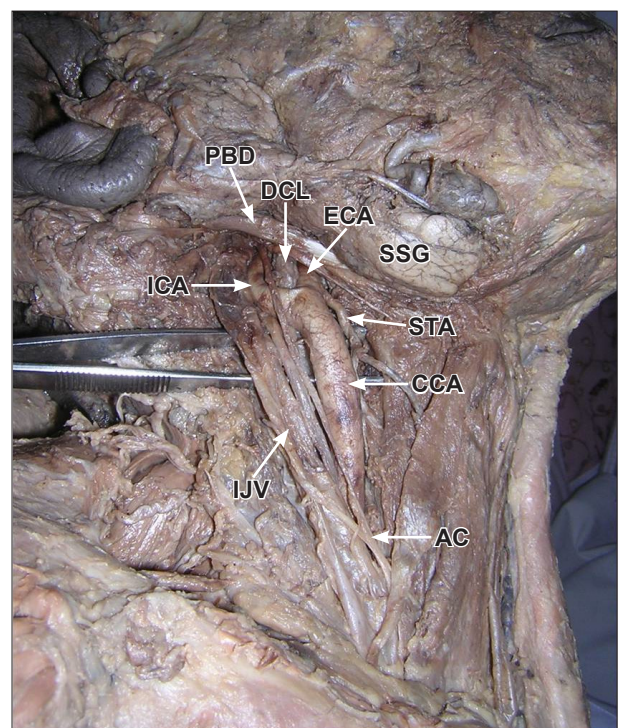
### Introduction

The internal carotid artery is the larger terminal branch of common carotid artery. It originates at the level of upper border of the lamina of thyroid cartilage and ascends vertically in the carotid sheath and enters the carotid canal at the base of the skull. In the cranial cavity it passes through the cavernous sinus. After coming out of the cavernous sinus, it divides into anterior and middle cerebral arteries at the base of the brain. It is the major artery of the brain, eye and the internal ear. It has a straight course in the neck. Kink in its course in the neck may result in hindrance in the blood flow to the above regions and can cause serious problems.

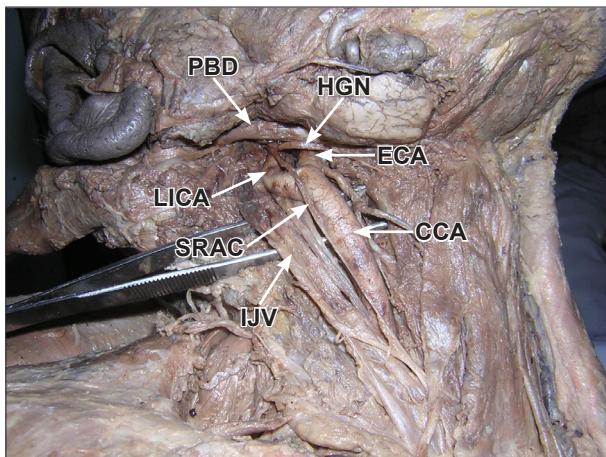
### Case Report

The study involved the dissection of the neck of an adult South Indian male cadaver aged approximately 50 years. The dissection was carried out at the Melaka Manipal Medical College (Manipal Campus). The dissection was carried out in the year 2008. The body was preserved in 10% formalin at a temperature of 4°C.

During the dissection, we observed a loop formed by the internal carotid artery near the carotid bifurcation (Figures 1, 2). The artery on the left side of the neck was normal. An abnormal, enlarged lymph node was situated at the carotid bifurcation. This node was pushing into the loop of internal carotid artery (Figure 1). During the initial part of the dissection, the loop of the artery also looked like another lymph node. Careful dissection



**Figure 1.** Dissection demonstrating the right side of the neck. (PBD: posterior belly of digastric; ECA: external carotid artery; SSG: submandibular salivary gland; ICA: internal carotid artery; CCA: common carotid artery; AC: ansa cervicalis; IJV: internal jugular vein; DCL: deep cervical lymph node; STA: superior thyroid artery)



**Figure 2.** Dissection demonstrating loop of the right internal carotid artery. (*PBD*: posterior belly of digastric; *ECA*: external carotid artery; *LICA*: loop of internal carotid artery; *HGN*: hypoglossal nerve; *CCA*: common carotid artery; *SRAC*: superior root of ansa cervicalis; *IJV*: internal jugular vein)

revealed the loop of the artery. The superior root of the ansa cervicalis crossed the loop formed by the internal carotid artery. There were no other variations in the right side of the neck.

### Discussion

Looping or kinking of internal carotid artery is not uncommon. Although incidence of coiling and kinking of internal carotid artery has been estimated to be from 10% to 16% in general population, respective clinical significance still remains the ground of controversy. The internal carotid artery may take a sinuous course with

a pronounced curve or a horseshoe shape, or may even form a complete loop in the upper cervical part of the vessel. This kinking of the artery may be due, however, to cardiovascular disease [1]. The looping of the lower part of the vessel has not been reported yet. During the neck dissection, Ogretmenoglu [2] found a sigmoid looping of internal carotid artery, which resembled a lymph node, rather than the artery itself. Looping of the artery in the lateral pharyngeal space has also been noted. The artery is particularly dangerous when it is in contact with the tonsillar fossa [3].

The other reported variations of the internal carotid artery include its medial position in relation to external carotid artery at the carotid bifurcation [4–8], its unilateral or bilateral absence [1] and an unusual artery connecting it with the external carotid artery [9].

The lymph node that we observed at carotid bifurcation is a “surprise” node for a surgeon as it is not a usual position for a lymph node. The enlarged node must be one of the deep cervical nodes, which has been displaced from its other group members that lie along the internal jugular vein. The loop of carotid artery also resembled a lymph node during early stages of the dissection. The looping of the artery, resemblance of the loop to a node and the presence of a node in the loop are very important for a surgeon who does cervical lymph node removal. The artery might be damaged during this procedure. The loop might mislead or cause confusions to radiologists who do imaging or invasive techniques. This type of loop at the bifurcation might cause problems at old age as the vessel becomes atherosclerotic or degenerative. It might also result in decreased blood supply to the brain.

### References

- [1] Bergman RA, Thompson SA, Aififi AK, Saadeh FA. *Compendium of human anatomic variations*. Baltimore-Munich, Urban & Schwarzenberg. 1988; 65.
- [2] Ogretmenoglu O. Asymptomatic looping of the internal carotid artery: a case report. *Kulak Burun Bogaz Ihtis Derg*. 2004; 12: 144–146.
- [3] Tillmann B, Christofides C. The “dangerous loop” of the internal carotid artery. *An anatomic study*. *HNO*. 1995; 43: 601–604.
- [4] Handa J, Matsuda M, Handa H. Lateral position of the external carotid artery. Report of a case. *Radiology*. 1972; 102: 361–362.
- [5] Braeuer NR, Mallamo JT, Lynch RD. Anomalous lateral and inferior position of the external carotid artery: case report. *J Can Assoc Radiol*. 1975; 26: 210–211.
- [6] Prendes JL, McKinney WM, Buonanno FS, Jones AM. Anatomic variations of the carotid bifurcation affecting doppler scan interpretation. *J Clin Ultrasound*. 1980; 8: 147–150.
- [7] Bussaka H, Sato N, Ogumi T, Korogi M, Yameshita Y, Takahashi M. Lateral position of the external carotid artery. *Rhinsho Hoshasen*. 1990; 35: 1061–1063.
- [8] Rao SB, Volla VR, Rao M, Samuel VP, Deepthiath, Nayak S, Pamidi N. Unusual position of external carotid artery: a case report. *Indian J Plast Surg*. 2005; 38: 170–171.
- [9] Suzuki T, Moriyama T, Moriwaki H, Yegihashi A, Yajima N, Takahashi G. Anomalous artery directly connecting the external and internal carotid arteries. *Ann Anat*. 2000; 182: 59–63.