



## Unusual course of the median nerve

Published online December 28th, 2010 © http://www.ijav.org

Kuntal VASHISHTHA<sup>[1]</sup> †  
 Subhash KAUSHAL<sup>[2]</sup>  
 Usha CHHABRA<sup>[2]</sup>

Department of Anatomy, Government Medical College, Chandigarh [1], and Department of Anatomy, Government Medical College, Patiala [2], INDIA.



† Kuntal Vashishtha, MS Anatomy  
 Demonstrator  
 Department of Anatomy  
 Government Medical College  
 Chandigarh, INDIA.  
 ☎ +91 987 8398058  
 ✉ kuntalvashishtha@ymail.com

Received June 17th, 2010; accepted December 18th, 2010

### ABSTRACT

One extremely unusual observation has been reported in this case report. During dissection of left hand of an adult human cadaver we found median nerve passing through the substance of flexor retinaculum. Median nerve coursed through the entire extent of flexor retinaculum in a fascial canal. No other structure was found along with nerve in the fascial canal. After emerging from the flexor retinaculum median nerve took its usual course in the hand. To the best of our knowledge this kind of variant median nerve course has not been described in published literature. © IJAV. 2010; 3: 216–217.

**Key words** [median nerve] [flexor retinaculum] [fascial canal]

### Introduction

Median nerve passes through the carpal tunnel to enter into the hand. The nerve courses beneath the flexor retinaculum and gives motor and sensory branches in the hand. There are several anatomic variations in the branching pattern of the median nerve in the forearm and hand [1]. Thenar branch is usually given off at the level of the distal margin of flexor retinaculum. Most of the published variations of median nerve relate to the thenar branch. One very unusual observation relating to variant course of median nerve, which to the best of our knowledge has not been published so far, is being reported in this case report. Variant course of the median nerve as described below was seen during cadaveric dissection of the hand.

### Case Report

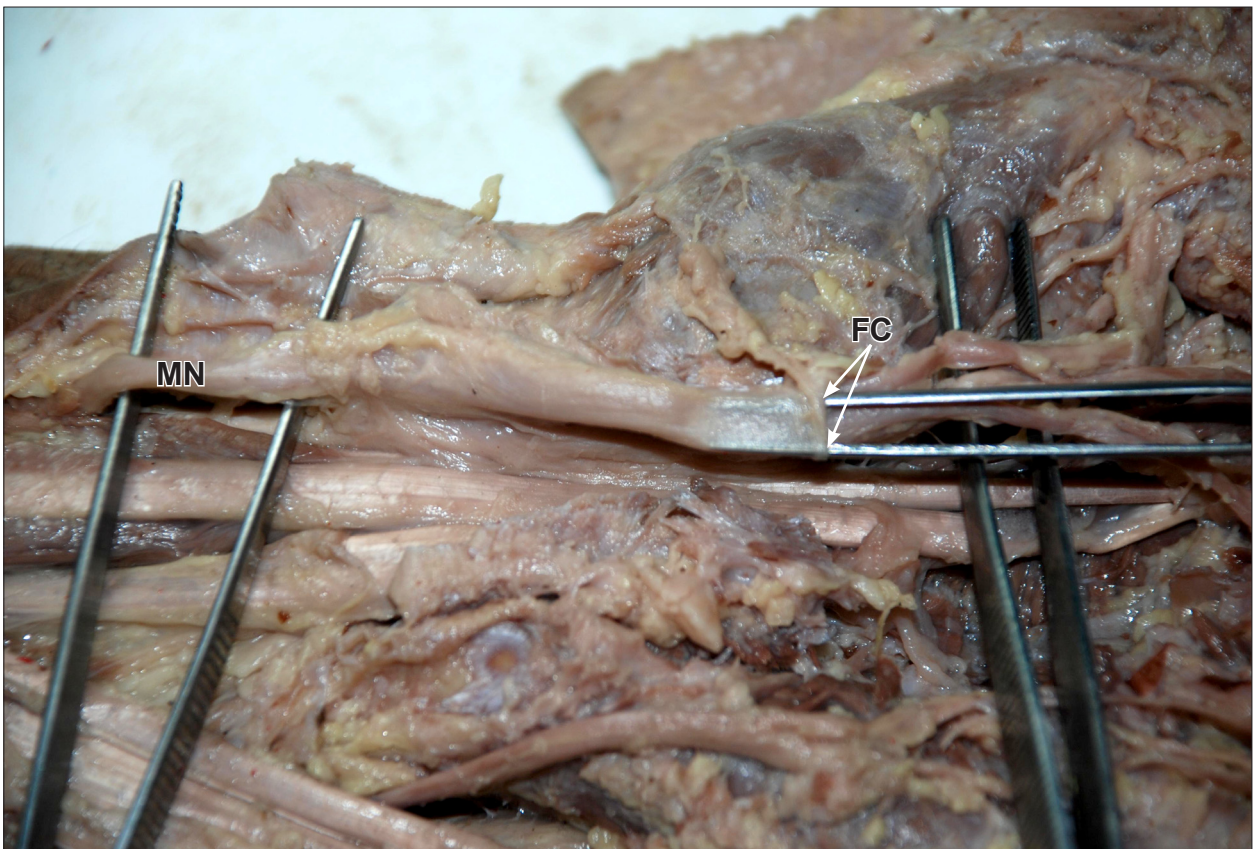
During dissection of the left hand of an adult human cadaver we found a variant course of median nerve (Figure 1). After traversing the forearm, median nerve entered into the flexor retinaculum and passed through the substance of the retinaculum in a fascial canal which was six centimeters long in its entire extent. On giving a sagittal incision in the flexor retinaculum the nerve got lifted in one of its edges. The fascial canal then could be identified starting distal to the origin of palmar cutaneous branch and extending upto the division of median nerve

into lateral and medial divisions. The fascial canal was then split to separate the median nerve. No other structure was found along with nerve in the fascial canal. After emerging from the flexor retinaculum median nerve took its usual course in the hand and gave motor and sensory branches.

### Discussion

The present report is unique in that we found median nerve traversing through and through the flexor retinaculum. Variations in the origin, course and number of thenar branch of median nerve have been well described in the published literature [1,2]. Lanz observed variations in the course of motor branch specially relating to its origin, which was either subligamentous, extraligamentous or transligamentous [1]. In addition, Lanz reported accessory branches at the distal portion of the carpal tunnel in 18 out of 246 hands. Falconer and Spinner studied ten specimens and observed transligamentous passage of the thenar branch of the median nerve in six dissections [2]. Out of six transligamentous thenar branches, one more extraligamentous motor branch to the flexor pollicis brevis was observed in two specimens. Takami et al. reported a variant of the median nerve in which there was a division of median nerve into two branches (ulnar and radial) at the level of the distal third of the forearm, and the ulnar branch of the median nerve passed through a separate compartment within the transverse carpal ligament and it was necessary to decompress both branches of the nerve when releasing the carpal canal

\* Presented at Annual Meeting of North States Chapter of Anatomical Society of India at M. Medical College Mullana, Ambala, INDIA (October 2009).



**Figure 1.** Photograph showing median nerve passing through the substance of flexor retinaculum in a fascial canal. (*MN: median nerve; FC: fascial canal*)

[3]. Variations in course and branching pattern of median nerve have fundamental clinical importance to prevent injuries, especially during limited open or endoscopic surgical procedures. Unusual median nerve course as described in this report makes the nerve especially vulnerable to damage during surgery causing permanent disability if one is not aware of such variation.

#### References

- [1] Lanz U. Anatomical variations of the median nerve in the carpal tunnel. *J Hand Surg Am.* 1977; 2: 44–53.
- [2] Falconer D, Spinner M. Anatomic variations in the motor and sensory supply of the thumb. *Clin Orthop Relat Res.* 1985; 195: 83–86.
- [3] Takami H, Takahashi S, Ando M. Bipartite median nerve with a double compartment within the transverse carpal canal. *Arch Orthop Trauma Surg.* 2001; 121: 230–231.