



Case Report

Unusual course of accessory renal artery and its clinical significance: a case report

Published online December 15th, 2011 © <http://www.ijav.org>

T. Ramesh RAO^[1]
Prakashchandra SHETTY^[1]
Suresh RAO^[2]✉

Department of Anatomy and Cell Biology Histology, American University of Antigua, Manjap Campus, KMC International Center, Manipal University, Manipal, Karnataka, INDIA [1], Department of Preclinical Sciences, Faculty of Medical Sciences, The University of West Indies, St. Augustine, Trinidad, WEST INDIES [2].



✉ Dr. Suresh Rao
Department of Anatomy and Cell Biology Histology
Department of Preclinical Sciences
Faculty of Medical Sciences
The University of West Indies
St. Augustine, TRINIDAD, WEST INDIES.
☎ +1 (868) 645-2848, ext. 4827
✉ s4chavan@yahoo.co.in

Received June 13th, 2011; accepted November 13th, 2011

ABSTRACT

The increasing use of invasive diagnostic and interventional procedures in cardiovascular diseases makes it important that the type and frequency of vascular variations are well documented and understood. With the advent of laparoscopic renal surgeries and donor nephrectomies, it becomes mandatory for the surgeon to understand the abnormality or variations in the renal vasculature. Otherwise renal transplant may be jeopardized by the presence of accessory and aberrant renal vessels. Existence of the accessory and aberrant renal arteries is accountable in cases of renal pathologies, radiological interventions, renal transplants, and other surgical approach on them. Therefore this case report would serve as ray of light for knowing the possible anatomical variations associated with the renal vasculature. During routine dissection we observed an unusual variation in the vascular supply to the kidney on the right side of a 63-year-old male cadaver. However such variation was not found on the opposite side. Patients with such variations may be asymptomatic.

© IJAV. 2011; 4: 197-199.

Key words [renal artery] [accessory renal artery] [aberrant renal artery]

Introduction

The renal arteries are a pair of lateral branches arising from the abdominal aorta below the level of superior mesenteric artery at the upper lumbar level (L1–L3). These arteries carry about 20% of the cardiac output to supply the organ that is about 1/100 of the total body weight. The right renal artery is longer in its course owing to the location of the abdominal aorta more towards the left side of midline. Each renal artery divides into anterior and posterior divisions at or very close to the hilum of the kidney. Further it divides into segmental arteries to supply the respective segments of the kidney being themselves the end arteries.

Variation in the number, source, branching and course of the renal arteries are very common. These accessory renal arteries or the aberrant arteries account for about 30% of existence, while 70% owes for the normal type. Further there is a difference in terminologies related to an aberrant renal artery and an accessory renal artery. An accessory renal artery is the one that is accessory to the main artery accompanying the same towards the hilum and entering the kidney through the hilum to supply it, while the aberrant artery supplies the kidney without entering its hilum.

Existence of the accessory and aberrant arteries is accountable in cases of renal pathologies, radiological interventions, renal transplants, and other surgical approach

on them. Altered state of hemodynamics was thought of in cases of multiple arteries supplying it.

In the present study we reported the unusual course of accessory renal artery and associated clinical significance of the same.

Case Report

Using conventional dissecting techniques, the posterior abdominal wall was dissected in a 63-year-old embalmed male cadaver, with a purpose of preparation of the teaching and museum anatomical specimens. The medical history of the cadaver was not available. In the present case we report a rare case of unusual course of accessory renal artery arising from the abdominal aorta on the right side. Following the fine dissection, the accessory renal artery was photographed. However, such variation was not found on the opposite side of the same cadaver.

In the present case we encountered a rare case of unusual course of accessory renal artery arising from the abdominal aorta approximately 1.3 cm above the normal renal artery on the right side. From this origin the accessory renal artery was found running downwards and to the right between the main renal artery and inferior vena cava to enter the kidney through the hilum below the main renal artery and in front of the renal pelvis. Following the fine dissection, the accessory

renal artery was photographed. However, such variation was not found on the opposite side and the cadaver did not have any other observable unusual feature in the other parts of the body (Figure 1).

Discussion

Accessory renal arteries arise from the aorta above or below the main renal artery and follow it to the renal hilum. They are regarded as persistent embryonic lateral splanchnic arteries. Accessory vessels to the inferior pole cross anterior to the ureter and may, by obstructing the ureter, cause hydronephrosis. Rarely, accessory renal arteries arise from the celiac or superior mesenteric arteries near the aortic bifurcation or from the common iliac arteries. Broadly around 70% of cases showed a single renal artery while 30% showed accessory renal arteries supplying the kidney [1].

Variation in the number, source and course of the renal arteries are common. Accessory renal arteries varying in size and generally derived from the aorta, are common (25%), and may enter the kidney almost at any point. Very rarely, the lower renal artery arises near the aortic bifurcation or from the common iliac artery. Sometimes one of the arteries passes in front of or behind the renal pelvis; the upper may cross the lower renal and the ureteropelvic junction to enter the inferior pole of the kidney. The presence of four renal hilar arteries derived from the aorta is rare. This pattern arises from the aorta between the superior and inferior mesenteric arteries. The upper two vessels may have a postcaval course and the lower may pass in front of the renal pelvis and the lower two behind it. There are no reported sex or race related differences [2].

Supernumerary renal vessels occur in about 30% of kidneys. Two to four in number and of equal frequency as to sides, they disperse along the aorta from the eleventh thoracic to the fourth lumbar vertebra. Usually parallel, they enter the hilum in sequence and may be precaval or postcaval in position. These are renal segmented arteries whose origin is more proximal than the normal [3].

Incidence of the multiple arteries has been reported to be about 20.2% on the right side and 19% on the left side [4].

These mesonephric arteries extend from C6 to L3 during the development. Most cranial vessels disappear while the caudal arteries form a network, the rete arteriosum urogenitale that supplies in future the metanephros [5]. Eventually some roots degenerate while persistent roots of the network form these segmental arteries of the adult kidney having variations at their point of origin [6].

Different origins of the renal arteries and its frequent variations are explained in various literatures owing to the development of mesonephric arteries [7].

The difference in the diameter of the main renal artery is accountable when additional artery/arteries were present. The presence of an additional renal artery is very probable when the main renal artery has a diameter less than 4.15 mm, which was observed in the study conducted on the Caucasian population. Also the variability in the renal irrigation was

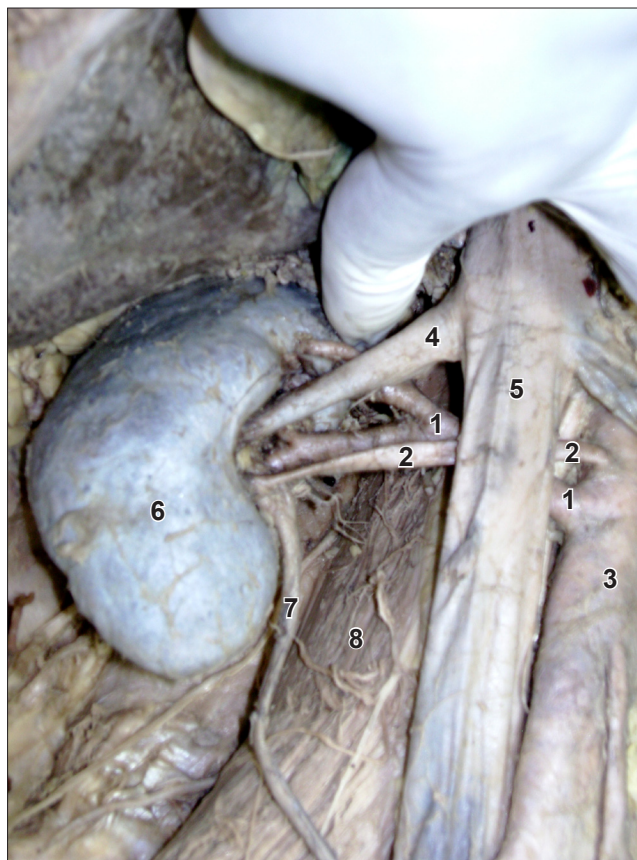


Figure 1. Anterior view of the right kidney with the unusual course of accessory renal artery on the dissected posterior abdominal wall. (1: renal artery; 2: accessory renal artery; 3: abdominal aorta; 4: renal vein; 5: inferior vena cava; 6: right kidney; 7: ureter; 8: psoas major)

more influenced by the ethnic factors and less so by gender was noticed [8].

If an accessory renal artery originates from the inferior mesenteric artery, it is likely to pass anterior to the ureter en route to the kidney. It could thus lead obstruction of the ureter, causing hydronephrosis. Failure to recognize this variation could be significant in procedures such as endoscopy, surgery on the lower colon, and kidney excision or transplantation. Clinicians need to be aware of the possibility of an accessory renal artery associated with the inferior mesenteric artery despite normal kidney development and location. So it is important to know such variations both from surgical and diagnostic points of view [9].

Conclusion

Familiarity about the possible variations in the renal arterial pattern is especially important for the personnel dealing with kidney retrieval and transplantation, various endourologic procedures and numerous interventional techniques. In such situations, it is the comprehensive knowledge of the renal arterial pattern which remains as the key issue in determining the technical feasibility of surgical interventions

as well as the post-operative management. In preparation for surgical interventions like, living renal donation, vascular reconstruction, renovascular hypertension, or radical nephrectomy, preoperative renal imaging is essential. In addition, the operative techniques with attention to the prehilum multiple branches of renal arteries should also be considered.

Our observations in the present case about the unusual course of the accessory renal artery will add more knowledge to

the variations in the renal arteries, which should be quite useful in renal surgeries. The variations of renal arteries are considered critical issues that surgeons should have thorough envision and appreciation of the condition. Variations of these vessels may influence urological, renal transplantation and laparoscopic surgeries

radiologists and oncologists who are dealing with this region.

References

- [1] Standring S, ed. *Gray's Anatomy. The Anatomical basis of clinical practice.* 40th Ed., Edinburg, Churchill & Livingstone. 2008; 1231–1233.
- [2] Bergman RA, Thomson SA, Afifi AK, Saadeh FA. *Compendium of Human Anatomic Variation.* Baltimore, Urban & Schwarzenberg. 1988; 81–83.
- [3] Anson BJ, Morris' *Human Anatomy.* 12th Ed., New York, Mc Graw-Hill Book Company. 1966; 746–747.
- [4] Das S. Anomalous renal arteries and its clinical implications. *Bratisl Lek Listy.* 2008; 09: 182–184.
- [5] Graves FT. The aberrant renal artery. *J Anat.* 1956; 90: 553–558.
- [6] Sinnatamby CS. *Last's Anatomy, Regional & Applied.* 10th Ed., Edinburgh, Churchill Livingstone. 1999; 276–278.
- [7] Ozkan U, Oguzkurt L, Tercan F, Kizilkilic O, Koc Z, Koca N. Renal artery origins and variations: Angiographic evaluation of 855 consecutive patients. *Diagn Interv Radiol.* 2006; 12: 183–186.
- [8] Saldarriaga B, Pinto SA, Ballesteros LE. Morphological expression of the renal artery. A direct anatomical study in Columbian half-caste population. *Int J Morphol.* 2008; 26: 31–38.
- [9] Loukas M, Aparicio S, Beck A, Calderon R, Kennedy M. Rare case of right accessory renal artery originating as a common trunk with the inferior mesenteric artery: a case report. *Clin Anat.* 2005; 18: 530–535.