



## Case Report

# Third head of sternocleidomastoid muscle

Published online December 21st, 2011 © <http://www.ijav.org>

Archana RANI +

Ajay Kumar SRIVASTAVA

Anita RANI

Jyoti CHOPRA

Department of Anatomy, Chhatrapati Shahuji Maharaj Medical University, Lucknow, Uttar Pradesh State, INDIA.



+ Archana Rani  
Associate Professor  
Department of Anatomy  
C.S.M. Medical University  
(Upgraded King George's Medical College)  
Lucknow, 226003, U.P., INDIA.  
☎ +91 945 1950798  
✉ [archana71gupta@yahoo.co.in](mailto:archana71gupta@yahoo.co.in)

Received April 5th, 2011; accepted November 20th, 2011

## ABSTRACT

During the routine cadaveric dissection, a third origin of sternocleidomastoid muscle was noted; i.e., an additional belly of its clavicular head was observed on the left side of the neck of a 65-year-old female. This additional slip was innervated by the spinal accessory nerve and vascularized by a branch of suprascapular artery. However, the sternal head on the left side and both the heads on the right side were as usual. This additional slip could have been formed due to unusual splitting in the mesoderm of post-sixth branchial arch during organogenesis.

The awareness of variations of sternocleidomastoid muscle is important for surgeons as the additional slips can be used as myocutaneous flaps in head and neck surgeries. This type of variation is also important for radiologists while interpreting MR images of this region. © IJAV. 2011; 4: 204–206.

**Key words** [sternocleidomastoid muscle] [variation]

## Introduction

The sternocleidomastoid, a prominent landmark of neck, offers protection to the major blood vessels and the nerves of this region. In recent era, this muscle has received a great attention of oncologists, general surgeons and plastic surgeons as it can be used as an excellent myocutaneous flap in reconstructive surgeries of head and neck region.

The sternocleidomastoid is the key muscle of the side of the neck which divides this quadrilateral region into anterior and posterior triangular areas. Arising by a cord-like tendinous sternal head from the anterior surface of the manubrium sterni and a broader partly aponeurotic clavicular head from the upper surface of the medial third of the clavicle, the fleshy belly of the sternocleidomastoid curves round the side of the neck to be inserted into the lateral surface of the mastoid process and adjoining part of the superior nuchal line of the occipital bone [1]. The two heads are separated from one another at their origins by a triangular interval, which corresponds to a surface depression, the lesser supraclavicular fossa. The muscle is vascularized by the branches of suprascapular, superior thyroid and occipital arteries and innervated by accessory nerve along with branches from ventral rami of C2-3 spinal nerves.

The present case reports an interesting and rare unilateral variation in the clavicular head of sternocleidomastoid

muscle. The surgeons should be aware of the presence of such additional slips while performing surgeries in head and neck regions as these can be used as myocutaneous flaps without disturbing the normal morphology of muscle.

## Case Report

During the gross dissection of neck region of a 65-year-old female cadaver, it was observed that the sternocleidomastoid muscle of left side was arising by a tendinous head from the front of the manubrium sterni and by a broad aponeurotic head from the medial part of the upper surface of clavicle, 1.2 cm lateral to its medial end. Additionally, an unusual prominent muscular slip was also arising from the upper surface of clavicle 3.8 cm lateral to its medial end. The fibers of both the clavicular heads were directed vertically upwards and backwards. The fibers of the usual or medial clavicular head were fusing with the sternal fibers at a distance of 5 cm from the clavicle, while the distance of fusion of additional clavicular fibers with the usual clavicular fibers was 5.5 cm. The sternal, usual clavicular and additional clavicular heads were blending into a thick, rounded muscle belly which was inserted by a tendon onto the lateral surface of the mastoid process and the superior nuchal line of the occipital bone. The two clavicular heads were separated by a wider triangular interval compared to the lesser supraclavicular fossa, which was formed between

the sternal and usual clavicular heads of origin. The usual as well as the additional slip were supplied by a branch from the spinal part of the accessory nerve. The additional head received its blood supply from an independent branch of suprascapular artery (Figure 1).

### Discussion

The complexity of the sequential development of any region can give rise to countless variations. These morphological variants, when encountered by the clinicians who are not well versed with it, may become the cause of diagnostic errors or surgical complications.

Knowledge of human embryology is a valuable asset in understanding anatomic variations. The sternocleidomastoid and trapezius develop from a common premuscle mass from last two occipital and upper cervical myotomes. At 9 mm stage this common mass splits and separates. The two divisions grow independently along the upper limb bud. At 14 mm stage the mass destined to form sternocleidomastoid becomes fixed first to the clavicle and later to the sternum, occipital bone and mastoid process [2].

Variations of sternocleidomastoid at clavicular origin are much common. The sternocleidomastoid and trapezius muscle could be fused with each other; the clavicular origin could be as broad as 7.5 cm and when it is broad in

origin it could be subdivided into several slips, separated by narrow intervals [3]. Some authors reported a case with such multiple slips [4, 5].

Comparative studies in mammals have shown that the sternocleidomastoid is composed of five parts which are arranged in two layers. In a superficial layer, a superficial sternomastoid, sterno-occipital and cleido-occipital while in the deep layer, a deep sternomastoid and cleidomastoid parts. There is considerable variation in the extent of independence of the main fasciculi of the muscle. In many of the lower animals the cleidomastoid portion of the muscle is quite distinct from the sternomastoid portion, and this condition is frequently found in man [6].

Coskun et al. reported a case, in which they found sternocleido-occipital and sternomastoid muscle in superficial layer and cleidomastoid muscle in deep layer [7]. Sarikcioglu et al. observed an unusual muscle deep to sternocleidomastoid and termed it cleido-occipital muscle [8]. The additional muscle mass observed in the present case was different from those reported by above authors as it was separated from the usual clavicular head by an additional triangular gap. Moreover, this additional clavicular head did not have any independent attachment on the mastoid process or occipital bone; instead the muscle fibers were merging with the main muscle belly. A similar case of additional clavicular head of sternocleidomastoid was reported by Ramesh et al., but it was bilateral [9].

The additional slip in the clavicular origin of sternocleidomastoid muscle may be due to unusual splitting in the mesoderm of post-sixth branchial arch [9].

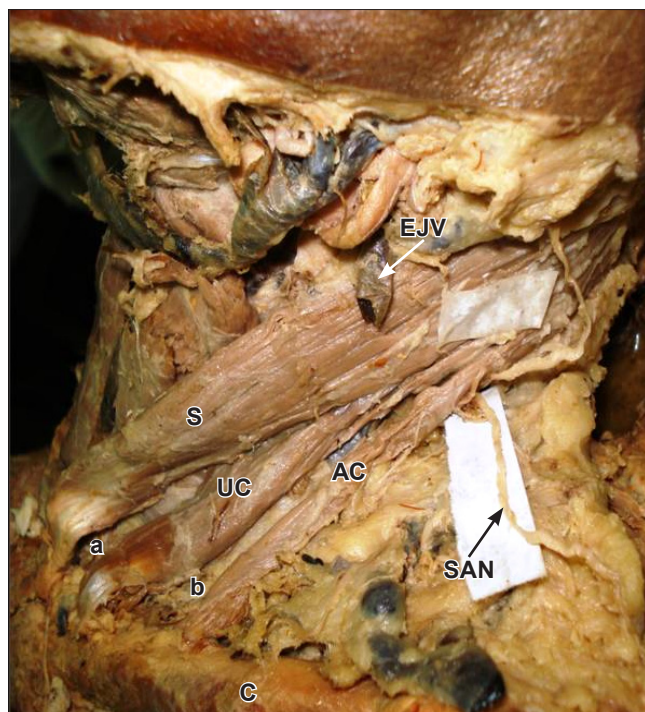
Sternocleidomastoid muscle can be used as myocutaneous flap for facial defects, parotid surgery, carotid artery protection and repair of oral cavity defects [10,11]. It is essential for the surgeons to be aware of possible variations during routine head and neck surgeries and during MR imaging observations of the neck region. The additional triangular interval between two clavicular heads should be kept in mind while approaching internal jugular vein for venous catheterization.

Recently, radiological parameters have been outlined to identify boundaries between various neck levels. Among them the posterior border of sternocleidomastoid muscle is an important landmark [12]. Awareness of additional clavicular head should be kept in mind while adjudging the various levels in CT and MR images.

The patients receiving radiotherapy for cancers in the neck sometimes develop radiation induced cervical muscle spasm. The painful tightness of the neck is relieved by botulinum toxin A injection in the sternocleidomastoid muscle. Individuals having additional muscle mass of sternocleidomastoid, may need a larger dose of medication [13].

### Conclusion

The unusual muscle mass found in the present case is an accessory clavicular head of sternocleidomastoid muscle



**Figure 1.** Photograph showing third origin of sternocleidomastoid muscle. (*S*: sternal origin of sternocleidomastoid; *UC*: usual clavicular origin of sternocleidomastoid; *AC*: additional clavicular origin of sternocleidomastoid; *SAN*: spinal accessory nerve; *EJV*: external jugular vein; *C*: clavicle; *a*: lesser supraclavicular fossa; *b*: additional lesser supraclavicular fossa)

thus giving it a third origin. The accessory head was supplied by the spinal accessory nerve. An additional larger lesser supraclavicular fossa was separating this clavicular

head from the usual one. The knowledge of such variation is a matter of concern to general surgeons, radiologists and oncologists who are dealing with this region.

## References

- [1] Lockhart RD, Hamilton GF, Fyfe FW. *Anatomy of the Human Body*. 1st Ed., London, Faber and Faber Limited. 1959; 166.
- [2] Schafer ES, Symington J, Bryce TH. *Quain's Elements of Anatomy*. 11th Ed., New York, Longman's Green and Co. 1923; 67–70.
- [3] Bergman R, Thompson SA, Afifi AK, Saadeh FA. *Compendium of human anatomical variation*. Baltimore, Urban & Schwarzenberg. 1988; 32–33, 40–41.
- [4] Goss CM. *Anatomy of the human body*. Philadelphia, Lea and Febiger. 1973; 372–396.
- [5] Boaro SN, Fragoso Neto RA. Topographic variation of the sternocleidomastoid muscle in a just been born children. *Int J Morphol*. 2003; 21: 281–284.
- [6] Schaeffer JP. *Morris' Human Anatomy: A Complete Systematic Treatise*. 10th Ed., Philadelphia, Toronto, The Blakiston Company. 1942; 412–414.
- [7] Coskun N, Yildirim FB, Ozkan O. Multiple muscular variations in the neck region – case study. *Folia Morphol (Warsz)*. 2002; 61: 317–319.
- [8] Sarikcioglu L, Donmez BO, Ozkan O. Cleidocranial muscle: an anomalous muscle in the neck region. *Folia Morphol (Warsz)*. 2001; 60: 347–349.
- [9] Rao TR, Vishnumaya G, Prekashchandra SK, Suresh R. Variation in the origin of sternocleidomastoid muscle. A case report. *Int J Morphol*. 2007; 25: 621–623.
- [10] Charles GA, Hamaker RC, Singer MI. Sternocleidomastoid myocutaneous flap. *Laryngoscope*. 1987; 97: 970–974.
- [11] Alvi A, Stegnajic A. Sternocleidomastoid myofascial flap for head and neck reconstruction. *Head Neck*. 1994; 16: 326–330.
- [12] Hamoir M, Desuter G, Gregoire V, Reyckier H, Rombaux P, Lengele B. A proposal for redefining the boundaries of level V in the neck: is the dissection of the apex level V necessary in mucosal squamous cell carcinoma of the head and neck? *Arch Otolaryngol Head Neck Surg*. 2002; 128: 1381–1383.
- [13] Van Daele DJ, Finnegan EM, Rodnitzky RL, Zhen W, McCulloch TM, Hoffman HT. Head and neck muscle spasm after radiotherapy: management with botulinum toxin A injection. *Arch Otolaryngol Head Neck Surg*. 2002; 128: 958–959.