

The Anatomy of the Fabela Bone and its Clinical Importance

Sóstenes S. Oliveira^{1*}, Wellington J. S. F. Oliveira²

Oliveira SS, Oliveira WJSF. The Anatomy of the Fabela Bone and its Clinical Importance. *Int J Anat Var.* 2021;14(3):59-65.

ABSTRACT

The fabella bone is characterized as a sesamoid that is located in the posterior region of the knee, precisely in the tendon of the lateral head of the gastrocnemius muscle, behind the lateral femoral condyle. During routine

physical therapy visits, pain was found in the functional evaluation of the posterior region of the knee during flexion-extension movements of the right knee. A radiograph of the right knee in the lateral plane was requested and the fabella bone was evidenced. Patients with fabella may be asymptomatic. However, here we find a case in which the fabella bone may be associated with pain in the lateral aspect of the knee.

Key Words: Human anatomy, Knee pain, Fabela

INTRODUCTION

The fabella bone is characterized as a sesamoid-type bone that is located in the posterior region of the knee, precisely in the tendon of the lateral head of the gastrocnemius muscle, behind the lateral femoral condyle [1].

Fabellar Syndrome (SF) is related to knee pain, synovial irritation and degeneration of the joint surface. The presence of fabella can be examined by palpation or by complementary exams, such as radiographs, ultrasounds and magnetic resonance. However, Fabela is very neglected by many professionals and can be one of the factors for such errors in clinical and kinetic-functional diagnoses [2].

CASE REPORT

A 62-year-old patient presented to the Physiotherapy Department of the Unified Health System in the city of Bento Fernandes, Rio Grande do Norte, Brazil, with a history of knee pain, specifically in the posterolateral compartment of the knee after being diagnosed with osteoarthritis on the right knee. There was no history of knee problems previously. On physical examination, she presented joint effusion and pain on palpation in the popliteal region, but no muscle defect was noted.

During the functional evaluation, crackling sounds were noticed during the knee flexion-extension movements, reporting painful signs at 40 ° of knee flexion. During the entire knee extension movement, no pain symptoms were noted. She reports that she feels a lot of pain when climbing stairs and performing the movements of sitting and getting up from a chair, for example.

The examination requested by the physiotherapist was an X-ray of the right knee in the sagittal plane with lateral view. Upon receipt of the report, the diagnosis of arthrosis in the knee joint was closed. However, in the evaluation of the radiography, now, being more careful, the fabella bone was noticed by the physiotherapist (Figure 1).

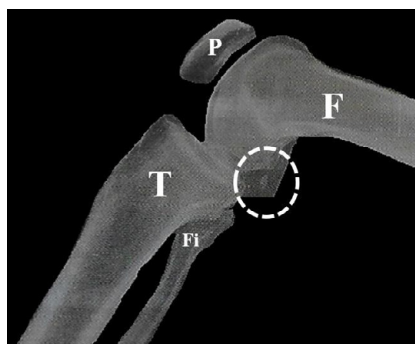


Figure 1) Radiograph of the right knee. F: femur; P: Patella; T: Tibia; Fi: fibula; White circle in strokes: Bone fabella.

DISCUSSION

The case report published here supports that fabella bone can be detected in routine radiographic examinations and that it will lead to a more careful search for physiotherapeutic approaches to be performed on the patient in order to reduce the pain, improve the range of motion and increase the strength of the limb without feeling pain at the moment of the evaluated movements and that will be used in daily life.

Fabella bone is present more in men than in women and the fabella prevalence rate increases with age, they can ossify in the beginning of life, at 12 years old, or later, until the mid-70s. In most cases the fabella is present on both knees; however, in the unilateral cases of the fabella, it is present more on the right knee. We can say that it is present on average 36.8% of the knees worldwide, being more prevalent in the population of Asia, Oceania and South America than in Europe, the Middle East, North America and Africa [3].

It is worth noting that the fabella is more evident in studies that use cadaveric dissection as a method than for those based on imaging tests, for example radiography. This is due to the fact that studies with dissections of the fabella bone may be presented in a more cartilaginous or ossified form, but less dense [1,3]. Here in this case studied, we have more evidence that the fabella can be seen in routine radiographic examinations.

We do not have many studies in the scientific literature that have investigated the function of fabella [3]. Some studies have described that the fabella may be related to the development of the fabelofibular ligament [4], which may help to improve the stability of the posterolateral knee complex [5] and finally suggested until then that the fabella may be acting as an advantage mechanics for the inserted muscle [6].

CONCLUSION

The knowledge on the part of health professionals of the existence of fabella bone is of great importance for the daily practice of the professional who performs the activities in the operating room or in the outpatient clinic. The fabella can trigger SF and cause pain in the posterolateral region of the knee. However, there are several types of diagnosis that can be considered during the evaluation of the patient who presents the fabella bone, because at the time of the evaluation, a more careful evaluation that will designate a more specific conduct for these cases is extremely important.

CONFLICTS OF INTEREST

The authors declare no conflicts of interest.

ACKNOWLEDGEMENT

None.

¹Department of Morphology, Federal University of Rio Grande do Norte, Natal-RN, Brazil; ²Department of Physiotherapy, Faculty Mauricio de Nassau, Natal-RN, Brazil

Correspondence: Dr. Sostenes Silva de Oliveira, Department of Morphology, Federal University of Rio Grande do Norte, Natal-RN, Brazil. Telephone +84994588645; E-mail: sostenesfisio@gmail.com

Received: Dec 26, 2020, Accepted: Mar 05, 2021, Published: Mar12, 2021



This open-access article is distributed under the terms of the Creative Commons Attribution Non-Commercial License (CC BY-NC) (<http://creativecommons.org/licenses/by-nc/4.0/>), which permits reuse, distribution and reproduction of the article, provided that the original work is properly cited and the reuse is restricted to noncommercial purposes. For commercial reuse, contact reprints@pulsus.com

REFERENCES

1. Adukia V, Ricks M, Colquhoun K, et al. An anomalous band originating from the fabella causing semimembranosus impingement presenting as knee pain: a case report. *J Med Case Rep.* 2019;13:1-4.
 2. Pop TS, Pop AM, Olah P, et al. Prevalence of the fabella and its association with pain in the posterolateral corner of the knee: A cross-sectional study in a Romanian population. *Medicine.* 2018;97:47.
 3. Berthaume MA, BULL AMJ. Human biological variation in sesamoid bone prevalence: the curious case of the fabella. *J Anat.* 2020;236:228-42.
 4. Minowa T, Murakami G, Kura H, et al. Does the fabella contribute to the reinforcement of the posterolateral corner of the knee by inducing the development of associated ligaments?. *J Orthop Sci.* 2004;9:59-65.
 5. Eyal S, Rubin S, Krief S, et al. Common cellular origin and diverging developmental programs for different sesamoid bones. *Development.* 2019;146:4.
 6. Driessen A, Balke M, Offerhaus C, et al. The fabella syndrome-a rare cause of posterolateral knee pain: a review of the literature and two case reports. *BMC Musculoskeletal Disorders.* 2014;15:100.
-