



Subcutaneous superficial palmar arch — an unusual variant

Published online November 30th, 2015 © <http://www.ijav.org>

Sushama Kalidas CHAVAN †
Rajendra Namdeo WABALE

Department of Anatomy, Rural Medical College, Pravara
Institute of Medical Sciences, Loni, Ahmednagar, INDIA.



† Dr. Mrs. Sushama Kalidas Chavan
Department of Anatomy
Rural Medical College Loni
Ahmednagar (M) INDIA.
☎ +91 9552033318
✉ sushama_chavan1980@yahoo.com

Received January 30th, 2014; accepted August 9th, 2014

Abstract

Superficial palmar arch is the source of blood supply to hand. Formed by continuation of ulnar artery and completed usually by superficial branch of radial artery. The arch lies deep to the palmar aponeurosis. In our routine dissection for students, we came across an unusual variant of superficial palmar arch in the right hand. It was present in a plane. The branching pattern was also variable showing four common palmar digital branches. The case along with its embryological basis and clinical relevance is discussed.

© *Int J Anat Var (IJAV)*. 2015; 8: 26–29.

Key words [superficial palmar arch] [palmar aponeurosis] [common palmar digital arteries]

Introduction

Arterial arches of hand are the major blood supply to the structures in the hand. The two arches, superficial and deep palmar arches make an important anastomose between the radial and ulnar arteries. Superficial palmar arch (SPA) is formed by direct continuation of ulnar artery, i.e. superficial palmar branch, completed on lateral side by one of the three branches of radial artery [1]. It usually is deep to the palmar aponeurosis, which is formed by deep fascia and palmaris longus tendon. Like the arterial variations in the other parts of body, the variations in arterial arches of hand are also common. These variations are found in formation of arch or in branching pattern of arch. A study of 200 hands by Loukas et al. showed complete SPA in 90% of cases and divided into five types, while the remaining 10% possessed an incomplete palmar arch [2]. Patterned variations are quite common in SPA [3]. A study of the superficial palmar arteries by Al-Turk et al. using the Doppler ultrasonic flowmeter on 50 hands revealed a complete arch in 84% of the cases [4]. Thus high incidence of anatomical variations in the arterial pattern of the hand has been the subject of many anatomical studies. All these variations recorded in the literature are regarding the source arteries for the formation of SPA and the variability of

branching pattern. We have come across a variation of SPA not recorded till date and we considered it as important to put in the record of literature.

Case Report

A variation in fascial location of SPA was noticed in the male cadaver during routine dissection class in the Department of Anatomy. After reflecting the skin of palm of hand, we came across an arterial arch confirmed later, to be SPA present in the superficial fascia of hand. The arch was formed by direct continuation of ulnar artery beyond the flexor retinaculum. The arch was completed on lateral side by superficial palmar branch that arose on lateral side of wrist from the radial artery. Ulnar artery was larger in caliber and the branch from the radial artery was thin. The superficial palmar branch of radial artery ran forward, passed beneath the muscles of ball of thumb and joined the ulnar artery to complete the superficial palmar arch. The arch was superficial to the palmar aponeurosis; its convex border was directed towards the fingers and situated at the level of distal border of the fully extended thumb. The median nerve and its digital branches were deep to palmar aponeurosis. The palmar digital branches ran superficial to palmar aponeurosis but deep to

superficial transverse ligament (Figure 1a). There was also variation in branching pattern of SPA. The branches from SPA were five in number. The proper digital artery arose for ulnar side of little finger. The middle three were common palmar digital branches that originated from the arch and passed to second, third and fourth web spaces (Figure 1a). The lateral most was a common digital branch for first web space. This artery divided into radialis indicis artery for the radial side of index finger and the princeps pollicis for thumb (Figure 1a, b).

Discussion

Variations in the arterial pattern of the hand have been the subject of many studies; these variations can be of substantial interest to orthopedic surgeons, plastic surgeons, radiologists, and anatomists. These variations are in mode of origin or branching pattern, unexpected relationship with surrounding structures and occupation of unusual tissue planes [1]. Anatomic variations in the major arteries of the upper extremities have been reported in 11-24.4% of

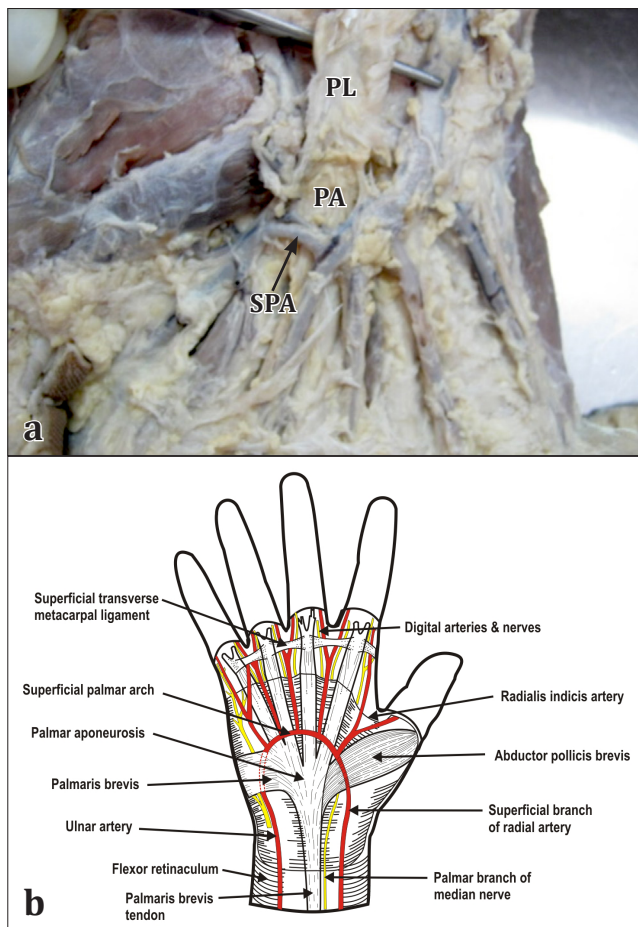


Figure 1. a) Subcutaneous superficial palmar arch. (*PA*: palmar aponeurosis; *SPA*: subcutaneous superficial palmar arch; *PL*: palmaris longus tendon) **b)** Diagrammatic representation of subcutaneous superficial palmar arch.

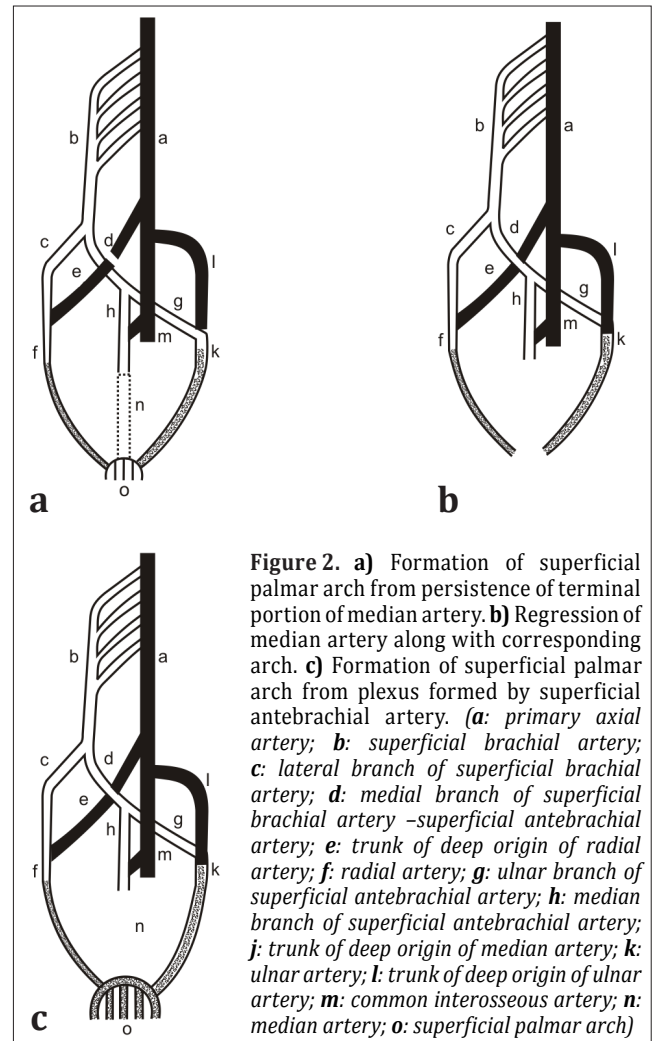


Figure 2. a) Formation of superficial palmar arch from persistence of terminal portion of median artery. **b)** Regression of median artery along with corresponding arch. **c)** Formation of superficial palmar arch from plexus formed by superficial antebrachial artery. (*a*: primary axial artery; *b*: superficial brachial artery; *c*: lateral branch of superficial brachial artery; *d*: medial branch of superficial brachial artery -superficial antebrachial artery; *e*: trunk of deep origin of radial artery; *f*: radial artery; *g*: ulnar branch of superficial antebrachial artery; *h*: median branch of superficial antebrachial artery; *j*: trunk of deep origin of median artery; *k*: ulnar artery; *l*: trunk of deep origin of ulnar artery; *m*: common interosseous artery; *n*: median artery; *o*: superficial palmar arch)

individuals [5]. The incidence of superficial brachio-ulno-radial arteries in adults has been found ranging from 0.14-1.3% [6]. Superficial course of brachial artery with superficial ulnar artery passing superficial to flexor muscles of forearm have also been reported [7]. High origin of ulnar artery from brachial artery coursing superficial to bicipital aponeurosis, superficial to the flexor muscles of forearm and terminating as SPA is also on record [8]. Though number of cases has been reported about the superficial course of brachial, ulnar, and radial artery, no one has reported about the superficial course and subcutaneous location of SPA till date. In the present case, brachial, radial, and ulnar arteries were coursing normally but the SPA was superficial to the palmar aponeurosis.

The arterial system develops from a multiple and a plexiform source, by sequential pattern of development, and functional dominance followed by regression of some path. Developmentally lateral branch of seventh intersegmental artery communicates with axis artery developing in situ in upper limb bud. This axis artery is represented by axillary,

brachial, and interosseous arteries. The interosseous artery continues into hand plexus, and forms deep palmar arch. The ulnar, median, and radial arteries sprout from axial artery. Median arteries that sprout from axis artery usually accompany median nerve in hand and forms superficial capillary plexus (Figure 2). Median artery regresses, loses its distal connection and superficial palmar plexus is fed by communication of the ulnar artery with the plexus to form the superficial palmar arch [1]. In the present case, the distal communication of median artery along with superficial capillary plexus may have regressed completely (Figure 2). The present variant may be due to persistence of hemodynamic of superficial system over deep system in the hand. The SPA in the present case probably is formed by the superficial ante-brachial vessel continuing into the palm to form a plexus that is joined on lateral side by the superficial palmar branch of radial artery (Figure 2). The superficial ante-brachial artery is the medial branch of superficial brachial artery an embryonic vessel that divides into median and ulnar artery. These join with the corresponding deep arteries that sprout from axis artery [6]. The ulnar artery is formed by persistence of deep artery at its origin and the rest is persistence of superficial ante-brachial vessel [6]. The usual list of reasons for such an occurrence include genetic factors, local tissue development dynamics and external factors such as positioning of the limb in utero.

Other reason may be the presence of superficial median artery that formed superficial capillary plexus in hand and coursed in superficial plane while the rest of the artery in the forearm regressed. The plexus is joined by ulnar artery to form SPA. The superficial median artery had been reported with an incidence of 1% [9], but was not found in previous studies on large samples [10] or human embryos [11]. Rodriguez-Niedenführ et al. proposed that the arterial pattern of the upper limb develops from an initial capillary plexus by a proximal to distal differentiation (in the forearm with a posterior anterior polarity) due to the maintenance, enlargement, and differentiation of certain capillary vessels, and the regression of others. It is suggested that the initial capillary plexus, which would normally remain in a capillary state or even regress, persists and gives rise to variations in the definitive arterial pattern [11]. The comparative study of arteries of hands in primates confirmed that the variations noted in man represent a retention or reappearance of primitive pattern [12].

SPA gives four palmar digital arteries; the medial most supplies the medial side of little finger and is termed as the proper palmar digital artery. The other three are common palmar digital arteries which pass to the middle three inter digital clefts [13]. The common digital branch for first web was given by SPA; it branched into radialis indicis artery and princeps pollicis; these arteries arise from the radial artery as per the usual morphological occurrence. In a comprehensive study of the arterial pattern of 750 hands, McCormack et al. did not find an origin of the princeps pollicis and radialis indicis arteries from the SPA [11]. Al-Turk and Metcalf

reported in a Doppler study of the SPA and variations in pattern of the arteriae digitalis palmares communes, radialis indicis, and princeps pollicis. In all his cases, the radial indicis and princeps pollicis was a branch from radial artery and none was from SPA [4]. But Ruengsakulrach et al. reported that, in 66% of the hands all the fingers were supplied by the SPA [14]. Ikeda et al. termed the artery which supplies the first web space and coming from the superficial arch as the first common palmar digital artery [5]. The similar case was observed by Vollala et al., who reported that superficial arch gave origin to four common palmar digital arteries instead of three. The first common palmar digital artery divided into radialis indicis and princeps pollicis arteries [8]. The arteries arising from the SPA that supply the first web space acquire great importance in case of absence of arterial supply from the deep arch to that region [8]. This case showed the predominance of the superficial arch over the deep arch in supplying the thumb and index finger. This carries even more significance, since the arch is being placed superficial to and outside the protection given by palmar aponeurosis. Thus making it more vulnerable.

Clinically SPA is more important than deep palmar arch as the risk of trauma is very high. In reconstructive surgeries of hand that are increasingly becoming common, such superficial course of SPA may pose difficulties. There is increase chance of rupture leading to profuse bleeding. The knowledge of such occurrence is also important for hand surgeons while performing skin flaps so that accidental devascularization does not occur. Injury to the SPA or ulnar artery can compromise the arterial supply of the fingers, especially if there is insufficient anastomosis between the superficial and deep palmar arches [15]. During surgical procedures on the thumb in cases similar to ours, ligation of the radial artery may not be sufficient to stop profuse bleeding since the major blood supply comes from the superficial palmar arch. Hence, it is mandatory to conduct the investigations like Allen test, angiography and color Doppler studies of the hand before starting any invasive procedures including the vascular surgeries. The Doppler and angiographic studies allow visualization of vessels of the hand, but do not accurately assess the small connecting vessels [4, 5]. The recent advances in microsurgical techniques for the reconstruction of hand and upper extremity after trauma and congenital deformities have necessitated better understanding of the vascular patterns. Arterial variation is common but the presence of SPA superficial to the palmar aponeurosis is rare entity. Significance becomes more pronounced on knowing that SPA and not the radial artery is the primary source of blood supply to the first web space associated with the thumb and therefore occurrence of variations such as these should be at the back of mind of every vascular and hand surgeon.

Acknowledgement

Authors are thankful to artist cum modeler Mr. S. S. Sarangdhar for his help in artistic work in preparation of this manuscript.

References

- [11] Standring S, ed. *Gray's Anatomy*. 40th Ed., New York, Churchill Livingstone. 2008; 905.
- [12] Loukas M, Holdman D, Holdman S. Anatomical variations of the superficial and deep palmar arches. *Folia Morphol (Warsz)* 2005; 64: 78–83.
- [13] Jelicic N, Gajisin S, Zbrodowski A. Arcus palmaris superficialis. *Acta Anat (Basel)*.1988; 132:187–190.
- [14] Al-Turk M, Metcalf WK. A study of superficial palmar arch arteries using the Doppler ultrasonic flowmeter. *J Anat*. 1984; 138: 27–32.
- [15] Uglietta JB, Kadir S. Arteriographic study of variant arterial anatomy of the upper extremities. *Cardiovascular Intervent Radiol*.1989;12:145–148.
- [16] Rodriguez-Baeza A, Nebot J, Ferreira B, Reina F, Pérez J, Sanudo JR, Roig M. An anatomical study and ontogenic explanation of 23 cases with variations in the main pattern of the human brachio-ante-brachial arteries. *J Anat*. 1995; 187:473–479.
- [17] Cherian SB, Nayak SB, Somayaji N. Superficial course of brachial and ulnar arteries and high origin of common interosseous artery. *Int J Anat Var (IJAV)*. 2009; 2: 4–6.
- [18] Vollala VR, Nagabhooshana S, Bhat SM, Rodrigues V, Rao M, Pamidi N, Surendran S. Rare anatomical variant: Arterial circle in palm and at the base of the thumb. *Rom J Morphol Embryol*. 2008; 49:585-587.
- [19] Nakatani T, Izumi A, Tanaka S. Bilateral superficial median arteries. *J Anat*, 1999; 194: 475–477.
- [10] McCormack LJ, Cauldwell EW, Anson BJ. Brachial and ante-brachial arterial patterns; a study of 750 extremities. *Surg Gynecol Obstet*. 1953; 96:43–54.
- [11] Rodríguez-Niedenführ M, Vázquez T, Parkin IG, Sañudo JR. Arterial patterns of the human upper limb: Update of anatomical variations and embryological development. *Eur J Anat*. 2003; 7 Suppl 1: 21–28.
- [12] Manners-Smith T. The limb arteries of primates. *Anat Physiol*. 1910; 45: 23–64.
- [13] Romanes GJ. *Cunningham's Manual of Practical Anatomy*. Vol. 1, 15th Ed., Oxford, Oxford University Press. 2012; 74–104.
- [14] Ruengsakulrach P, Eizenberg N, Fahrer, C, Fahrer M, Buxton BF. Surgical Implications of variations in hand collateral circulation: Anatomy revisited. *J Thorac Cardiovasc Surg*. 2001; 122: 682–686.
- [15] Calenoff L. Angiography of the hand: Guidelines for interpretation. *Radiology*.1972; 102: 331–335.

