



## Sacrum with five pairs of sacral foramina

Published online August 10th, 2011 © <http://www.ijav.org>

Rajani SINGH †

Department of Anatomy, Chhatrapati Shahuji Maharaj Medical University, Lucknow, UP, INDIA.



† Dr. Rajani Singh  
Department of Anatomy  
Chhatrapati Shahuji Maharaj Medical University  
Lucknow, UP, INDIA.  
☎ +91 945 3193859  
✉ nani\_sahayal@rediffmail.com

Received September 25th, 2010; accepted June 14th, 2011

### ABSTRACT

Sacrum is wedged between two iliac bones at sacroiliac joint forming posterior wall of pelvis. Normally, there are five sacral vertebrae between cranially, fifth lumbar vertebra and caudally, first coccygeal vertebra forming four pairs of sacral foramina. But during osteology demonstration class of undergraduate MBBS students a sacrum with five pairs of sacral foramina was detected. This is a new anatomical variant.

The fifth pair of sacral foramina is generated either due to fusion of first coccygeal vertebra to apex of sacrum or fifth lumbar vertebra with first sacral vertebra. However, in the sacrum under study, the fifth pair of sacral foramina was developed due to sacralization of first coccyx with the fifth sacral vertebra. This pair of foramina gives passage to fifth pair of sacral nerve and coccygeal nerve. The variant is of paramount importance to surgeons and obstetricians dealing with these nerves. © IJAV. 2011; 4: 139-140.

**Key words** [coccyx] [vertebra] [foramina] [sacrum] [sacralization]

### Introduction

Sacrum is wedge shaped bone between two iliac bones forming posterior wall of pelvis. Normally, sacrum is generated by fusion of five sacral vertebrae constituting four pairs of sacral foramina [1]. At the cranial end of sacrum, there is fifth lumbar vertebra which when fused with the first sacral vertebra is known as sacralization of lumbar vertebra. Similarly at the caudal end, first coccygeal vertebra when fuses with the apex of sacrum, this process is known as sacralization of coccygeal vertebra. Both processes described above may generate additional fifth pair of sacral foramina [2].

The author came across a sacrum with five pairs of sacral foramina due to fusion of coccyx to the apex of sacrum. Case is reported for the variation in the anatomy of sacrum and its clinical implications among Indian population as it is less known variant.

### Case Report

During osteology demonstration class of undergraduate MBBS students of CSM Medical University, Lucknow, India, the author came across a sacrum with five pairs of sacral foramina. Dorsal surface also presented with five pairs of foramina (Figure 1). The transverse process of first coccygeal vertebra was fused with inferior lateral angle of

sacrum on both sides, coccygeal cornua of first coccygeal vertebra was also fused with sacral cornua. Body of coccygeal vertebra was also fused with the apex of sacrum. This complete fusion of coccygeal vertebra with the sacrum resulted in formation of an additional fifth pair of sacral foramina.

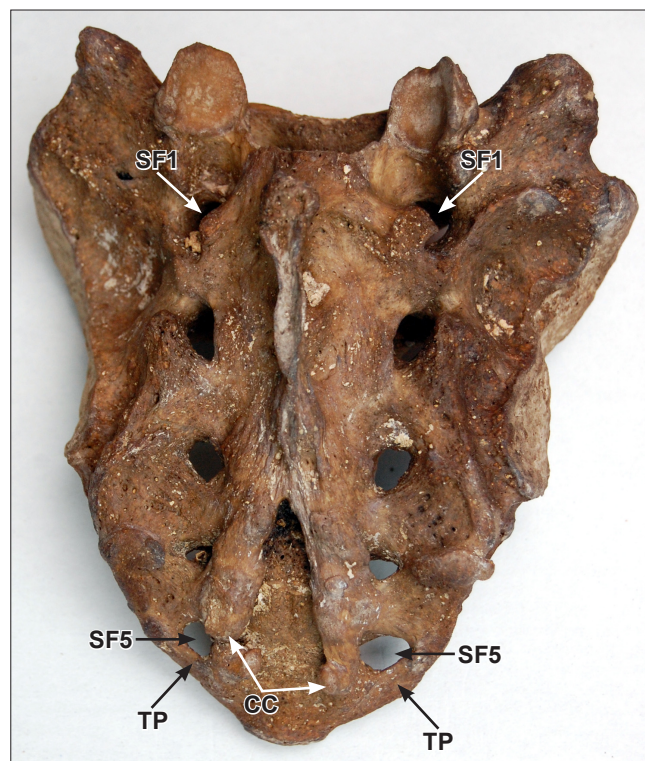
Ventral surface exhibited no unusual feature except that instead of four pairs of sacral foramina there were five pairs of sacral foramina (Figure 2).

### Discussion


Normally sacrum is formed by fusion of five sacral vertebrae and it contains four pairs of sacral foramina [1]. Sometimes fifth lumbar vertebra may fuse with the first sacral vertebra or first coccygeal vertebra may fuse with the apex of sacrum. This condition is known as sacralization of lumbar and coccygeal vertebra, respectively. Both conditions lead to formation of five pairs of sacral foramina [2]. Sacrum with six pairs of sacral foramina which are formed by fusion of fifth lumbar vertebra with the first sacral vertebra at the cranial end and that of first coccygeal vertebra with the apex of sacrum at the caudal end simultaneously [3].

### Causes of sacralization of coccygeal vertebra

The vast majority of people affected by this spinal abnormality are born with it, i.e., it is congenital. As HOX



**Figure 1.** Figure shows dorsal aspect of sacrum with five pair of sacral foramina. (SF1: first pair of sacral foramina; SF5: fifth pair of sacral foramina; TP: transverse process of coccyx; CC: coccygeal cornua)



**Figure 2.** Figure shows the ventral aspect of sacrum. (SF1: first pair of sacral foramina; SF5: fifth pair of sacral foramina; TP: transverse process of coccyx)

gene is responsible for patterning of shapes of vertebra [4]. So probably mutation in this gene could lead to sacralization of coccygeal vertebra. Exact cause is not known although genetics may play an important role. Less common reasons could be traumatic injury, extreme arthritic changes and purposeful spinal fusion surgery.

Normally fifth sacral nerve and coccygeal nerve pass through sacral hiatus. With the formation of fifth pair of sacral foramina above mentioned structures pass through fifth pair of sacral foramina.

#### *Clinical Significance*

The sacrum is clinically important for caudal epidural block which is performed for the diagnosis and treatment of lumbar spine disorders [5]. Caudal anesthesia is given in different surgical procedures like hernia repairs, lower limb surgery, surgery below umbilicus, etc. In this procedure, sacral cornua are identified. However, in case of sacralization of coccygeal vertebra, it will be difficult to mark the landmark and this may lead to caudal block failure. In addition to it, this route is also used for giving postoperative analgesia in children. Due to this variant there may be insufficient analgesia.

Normally coccyx is mobile and during second stage of labor it is pushed backwards, thus increasing the antero-posterior diameter of pelvic outlet, which facilitates delivery. Due to fusion, coccyx becomes fixed and there is no increase in antero-posterior diameter of pelvic outlet. This may lead to prolonged second stage of labor and perineal tears.

Thus clinically, the sacralization of coccygeal vertebra is of paramount importance to surgeons especially pediatric surgeons and obstetricians.

#### **References**

- [1] Standring S, ed. *Gray's Anatomy: Anatomical Basis of Clinical Practice*. 39th Ed., London, Churchill Livingstone. 2005; 749–750.
- [2] Platzer W. *Color Atlas of Human Anatomy. Volume 1: Locomotor System*. 6th Ed., Stuttgart, Thieme. 2008; 11.
- [3] Bergman RA, Afifi AK, Miyauchi R. *Illustrated Encyclopedia of Human Anatomic Variation: Opus V: Skeletal System: Sacrum and Coccyx*. <http://www.anatomyatlases.org/AnatomicVariants/SkeletalSystem/Text/SacrumCoccyx.shtml> (accessed August, 2011).
- [4] Sadler TW. *Langman's Medical Embryology*. 8th Ed., Chapel Hill, North Carolina, Lippincott Williams and Wilkins. 2000; 183.
- [5] Sekiguchi M, Yabuki S, Satoh K. An anatomic study of the sacral hiatus: a basis for successful caudal epidural block. *Clin J Pain*. 2004; 20: 51–54.