

## Right bronchial artery embolization in a patient with Kartagener syndrome

Shunyao Liu<sup>1</sup>, Yanyan Heng<sup>2</sup>, Liang Zhao<sup>1</sup>, Feifei Wang<sup>2</sup>

Liu S, Heng Y, Zhao L, et al. Right bronchial artery embolization in a patient with Kartagener syndrome. *J Clin Diag Treat* 2018;1[2]: 48-9.

**ABSTRACT:** We report the case of Kartagener syndrome accompanied by hemoptysis in a 42-year-old man. Bronchiectasis leads to the rupture of

the distal right bronchial artery, which causes hemoptysis. The hemoptysis stopped after the right bronchial artery embolization.

**Key Words:** Kartagener syndrome; Bronchial artery embolization; Treatment; Prognosis

Kartagener syndrome (KS) is an autosomal recessive genetic disease with an incidence of about (1-2)/3 million (1,2). It is a subtype of primary ciliary dyskinesia (PCD) (1) and about 55% of PCD patients with KS. KS is characterized by dextrocardia or total visceral transposition, bronchiectasis, and paranasal sinusitis (3). Here, we reported the right bronchial artery embolization for one KS patient with bronchopulmonary artery rupture.

A 42-year-old man was admitted to Changzhi people's Hospital (Changzhi, China) because of exacerbated cough, expectoration and hemoptysis, which had occurred intermittently for 4 years. It was diagnosed as pulmonary hypertension and bronchiectasis in Zhongshan Hospital (Guangzhou, China) in 2013 and symptoms were improved after symptomatic treatment. Four hours ago, the patient appeared hemoptysis again when he was climbing stairs. The hemoptysis was bright red, about two hundred milliliters. He had no asthma, chest tightness, palpitation, dizziness, headache, nausea and vomiting. The hemoptysis was not relieved after resting at home, and then he came to our hospital. Further inquiring revealed that the patient used to suffer from sinusitis in the past 15 years. Besides, the patient acknowledged that he had undergone surgery for congenital heart disease in Zhongshan Hospital (Guangzhou, China) in 1995. He has not the history of hypertension, coronary heart disease, diabetes, hepatitis B, tuberculosis, but loves smoking and drinking. His family was healthy.

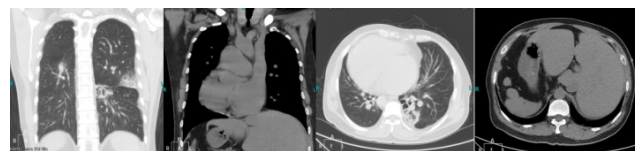
On physical examination, the patient had no fever, no external nasal deformity, no nasal flap, mild tenderness in bilateral paranasal sinus, and blood pressure was 153/98 mmHg in the right arm, but there were secretions and obstructions in the nasal cavity. He breathed regularly, and had no enhancement of language fibrillation weakened lungs coarse, no obvious and wet rales, voice transmission was normal. No abnormal uplift on the area before the heart, cardiac impulse was located on the right fifth intercostal space about 0.5 centimeter away from sternum, palpation without lifting type pulsation and pericardial friction feeling, but pulmonary valvular area can be heard diastolic murmur. The other physical and systemic examinations were normal.

After hospitalization, chest and abdominal computed tomography (CT) scan revealed lower left bronchiectasis with infection, multiple double pulmonary segmental inflammation, dextrocardia and right aortic arch, thoracic aorta and abdominal visceral inversion (Figure 1). Paranasal sinus CT scan revealed sinusitis, and nasal polyps could not except (Figure 2). Electrocardiogram showed dextrocardia and sinus tachycardia (Figure 3). Echocardiogram revealed dextrocardia, atrium and right ventricle enlargement, three tricuspid little regurgitation and pulmonary hypertension (severe), pulmonary artery diameter widening and pulmonary valve regurgitation in less amount. Hemogram revealed a total leukocyte count of  $11.43 \times 10^9/L$ , a neutrophil percentage of 64.2%, and a hemoglobin of 183 g/L. Liver function revealed a total protein of 55.7 g/L, an albumin of 36.2 g/L. Renal function, electrolyte, and blood transfusion before the examination were normal.

According to the clinical symptoms and examinations, the patient was considered Kartagener syndrome, which caused bronchial artery bleeding. The patient was treated with bronchial pulmonary artery embolization under local anesthesia (Figure 4). The 5F artery sheath was inserted into the right femoral artery by the right femoral artery puncture, and the right bronchial arteriography was selected along the 5F-Cobr catheter. Arteriography showed that Right bronchial artery thickening, tortuous, distal vascular disorders, contrast agent spilling. It was confirmed no spinal artery after the further superselective angiography with 2.7F micro catheter. The Bronchial artery was embolized by 300  $\mu$ m PVA. The following angiography showed that the distal branch of the right bronchial artery disappeared and the main trunk displayed. The puncture point compressed and bandaged after unsheathing. The patient felt no obvious discomfort during the treatment and transported to ward safely. After monitored by an electrocardiograph and anti-infection, expectorant pain relieving snuff treatment with cefazolin, ambroxol, ketorolac tromethamine, momison nasal spray, the patient recovered and left hospital.

### DISCUSSION

KS features ciliated dyskinesia. Cilia distribute throughout the body (such as respiratory tract, tympanic cavity and fallopian tube, sperm flagella etc.), so KS can be accompanied by nasal polyps, hydrocephalus, infertility or sterility symptoms (4), but the patient has one son. At the same time, because of condition limit, the sperm analysis, No screening test, gene detection and other related inspection were not carry out. KS patients with bronchial artery rupture are still rare. The hemoptysis of the patient is considered as a bronchial artery rupture caused by bronchiectasis, and the bleeding stops after emergency bronchial artery embolization, and he had no symptoms of hemoptysis during follow-up. However, there is an irreversible bronchiectasis and the pulmonary or lobectomy is feasible in severe hemoptysis. KS is a rare clinical disease, and most clinicians are not aware of the disease, so it is missed easily. For patients with recurrent respiratory tract infection, they should be highly vigilant. The related examination of chest CT and paranasal sinus CT should be supplemented in time in order to reduce the rate of missed diagnosis and the rate of misdiagnosis.



**Figure 1** The chest and abdominal CT revealed dilated bronchiectasis in the left lower lung, uneven growth of double lung with a grit-like density, heart shadow on the right side, and ascending aorta, aortic arch, liver, gastric lumen, spleen all in transposition.

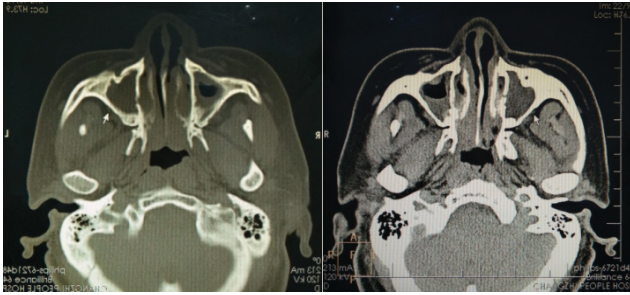
<sup>1</sup>Changzhi people's Hospital Affiliated to Changzhi Medical College, China, <sup>2</sup>Heping Hospital affiliated to Changzhi Medical College, China.

Correspondence: Shunyao Liu, Changzhi people's Hospital Affiliated to Changzhi Medical College, China. e-mail 1690525415@qq.com

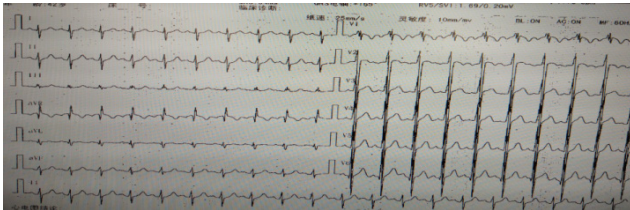
Received: May 30, 2018, Accepted: July 10, 2018, Published: July 16, 2018



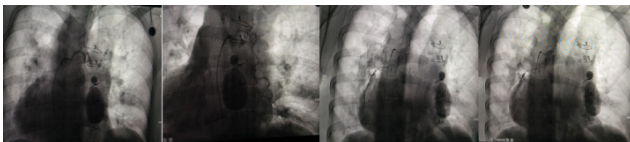This open-access article is distributed under the terms of the Creative Commons Attribution Non-Commercial License (CC BY-NC) (<http://creativecommons.org/licenses/by-nc/4.0/>), which permits reuse, distribution and reproduction of the article, provided that the original work is properly cited and the reuse is restricted to noncommercial purposes. For commercial reuse, contact [reprints@pulsus.com](mailto:reprints@pulsus.com)



**Figure 2)** The paranasal sinus CT revealed the soft tissue density was found in the bilateral maxillary sinus.



**Figure 3)** The electrocardiogram revealed sinus rhythm, electrocardio axis right deviation and right ventricular high voltage.



**Figure 4)** The Arteriography showed that Right bronchial artery thickening, tortuous, distal vascular disorders, contrast agent spilling. After embolized the bronchial artery, the angiography showed that the distal branch of the right bronchial artery disappeared and the main trunk displayed.

**CONCLUSION**

KS is a congenital disease, and there is no specific treatment at present. For severe KS, cases of successful lung transplantation and cardiopulmonary transplantation in foreign countries have been reported (5-6), but it is rare in clinical practice. At present, the prevention is primarily to avoid marriage between close relatives, prevent infection, and symptomatic treat when there are clinical symptoms.

**Compliance with ethical standards**

The authors have not conflict of interest. All procedures performed in studies involving human participants were in accordance with the ethical standards of the institutional and/or national research committee and with the 1964 Helsinki declaration and its later amendments or comparable ethical standards. Written informed consent was obtained from the patient for publication of this Case report and any related images.

**REFERENCES**

1. Blouin JL, Meeks M, Radhakrishna U, et al. Primary ciliary dyskinesia: a genome-wide linkage analysis reveals extensive locus heterogeneity. *Eur J Hum Genet.* 2000;8:109-18.
2. Leigh MW, Pittman JE, Carson JL, et al. Clinical and genetic aspects of primary ciliary dyskinesia/Kartagener syndrome. *Genet Med.* 2009;11:473-87.
3. Pandit S, Choudhury S, Das A, et al. A rare case of Kartagener's syndrome. *J Nat Sci Biol Med.* 2014;5:175-77.
4. Ortega HA, Vega Nde A, Santos BQ, et al. Primary ciliary dyskinesia: considerations regarding six cases of Kartagener syndrome. *J Bras Pneumol.* 2007;33:602-08.
5. Örgün I, Karnak I, Tanyel FC, et al. Surgical treatment of bronchiectasis in children. *J Pediatr Surg.* 2004;39:1532-536.
6. Deuse T, Reitz BZ. Heart-lung transplantation in situs inversus totalis. *Ann Thorac Surg.* 2009;88:1002-003.