ORIGINAL ARTICLE

Redefined endovascular trends in management of Budd Chiari syndrome to achieve better mid-term patency and survival rates

Arun G, Ajit Y, Mishra N, Gaurav G

Arun G, Ajit Y, Mishra N, et al. Redefined endovascular trends in management of Budd Chiari syndrome to achieve better mid-term patency and survival rates. J Hepato Gastroenterol. 2019;3(1):1-5.

BACKGROUND: Endovascular interventions have become the treatment of choice in patients with Budd Chiari Syndrome who are refractory to medical management alone. We studied the long-term stent patency and survival at a tertiary care center in north India.

METHODS: Single-center retrospective analysis was done in 46 patients of primary Budd Chiari Syndrome, who underwent endovascular intervention. Patency rates and survival analysis was done for median duration of 19.9 months (range 12 days to 78.4 months).

RESULTS: Patients underwent hepatic vein/inferior vena cava recanalization and/or Transjugular intrahepatic portosystemic shunt. Hepatic vein occlusion was present in 47.8%, IVC involvement in 28.2% and both IVC and Hepatic vein involvement in 23.9% cases. Technical success was achieved in 95.6% patients and clinical success in 86.3% patients. The cumulative primary patency rates at 6 months, 12 months, 2 years, and 5 years were 92.6%, 85.3%, 73.1% and 70.7% respectively. Re-intervention was done in 7 patients. Secondary patency rates at 6 months, 12 months, 2 years and 5 years were 100%, 100% 100% and 100% respectively. The cumulative overall survival at 6 months, 12 months, 2 years, and 5 years were 95.1%, 90.2%, 87.8% and 87.8% respectively.

CONCLUSION: We conclude that endovascular intervention has excellent outcome in management of Budd Chiari Syndrome cases refractory to medical treatment. Besides orthotopic hepatic vein recanalization, physiological recanalization in form of accessory hepatic vein stenting or collateral vein stenting are also alternatives. TIPS should only be offered where physiologic recanalization is not feasible.

Key Words: *Budd Chiari syndrome; Inferior vena cava; Hepatic vein thrombosis; TIPSS*

INTRODUCTION

Budd Chiari Syndrome (BCS) is no longer an unknown entity, characterized by hepatic venous outflow obstruction from the hepatic veins to termination of Inferior Vena Cava (IVC) into right atrium at any level that leads to increment in hepatic outflow resistance (1). Partial or complete obstruction of hepatic venous outflow leads to increased venous stasis and congestion that causes hepatocyte ischemia followed by liver fibrosis and ultimately cirrhosis. Treatment depends on the underlying cause, the anatomic location, the extent of the thrombotic process and the severity of liver disease. Treatment options can be divided into medical treatment which includes anticoagulation, diuretics, and thrombolysis; Interventional procedures such as balloon angioplasty, Hepatic vein (HV) or/and IVC stenting and Transjuglar intrahepatic porto-systemic shunt (TIPS) and surgical procedures such as surgical shunt or liver transplantation (2). In recent years, endovenous interventions have been widely used in the treatment of BCS to relieve hepatic congestion with more safety, minimal invasiveness, lower mortality and almost similar results to surgical treatment. This retrospective study delineates experience of a single tertiary care center in treating Budd Chiari Syndrome using endovenous interventions. Aim of our study is to assess the mid-term outcome of endovascular interventions and overall survival of patients with primary Budd Chiari syndrome.

METHODS

This was a single center retrospective study with data collected from the medical record for a period of approximately 6.5 years (April 2010 to December 2016). Requirement of patient consent was waived off by the Institutional review board because of the retrospective nature of the study, as per Institutional guidelines.

Patient characteristics

Fifty-eight patients diagnosed with BCS based on clinical and radiological criteria by Color Doppler Ultrasound, Triple phase CT angiography or hepatic MRI venogram were identified. Of these 58 patients, 2 patients with malignant obstruction, 7 patients who solely underwent medical management and 3 patients with insufficient medical record data were excluded. The final study population comprised of 46 cases in which endovascular interventions were performed. Baseline data including demographic data, clinical features, laboratory parameters, Child-Pugh Score and type of obstruction were obtained from medical records (Table 1).

TABLE 1

Demographics and relevant clinical data of patients included in the study

Gender		**n (Percentage)**
	Male	27 (58.7)
	Female	19 (41.3)
Median age – months (range, months)		35 (20-49)
Clinical symptoms		**n**
	Abdominal pain	23
	Abdominal distension	24
	Jaundice	6
	Fever	2
	Loss of appetite, fatigue, melena	1 each
Clinical and endoscopic evaluation		**n**
	Superficial collateral veins	6
	Endoscopic varices	13
Child Pugh status		**n**
	A	33
	B	12
	C	1
Type of outflow obstruction		**n (percentage)**
	Isolated HV	22 (47.8)
	Isolated IVC - Suprahepatic	7 (15.2)
	Isolated IVC- Intrahepatic	6 (13.1)
	Combined HV and IVC	11 (23.9)

Department of Interventional Radiology, Sir Ganga Ram Hospital, Delhi, India

Correspondence: Dr. Gaurav G, Department of Interventional Radiology, Sir Ganga Ram Hospital, Delhi, India. Telephone +919899025359, e-mail: sos.gaurav11@gmail.com

Received: December 16, 2018, Accepted: February 04, 2019, Published: February 08, 2019

OPEN ACCESS

This open-access article is distributed under the terms of the Creative Commons Attribution Non-Commercial License (CC BY-NC) (http://creativecommons.org/licenses/by-nc/4.0/), which permits reuse, distribution and reproduction of the article, provided that the original work is properly cited and the reuse is restricted to noncommercial purposes. For commercial reuse, contact reprints@pulsus.com

Our primary aim was to restore the normal physiologic outflow either by venoplasty or stenting. Based on pre-procedure imaging patients were divided into three groups; isolated involvement of IVC with patent hepatic veins, isolated HV involvement or involvement of both HV and IVC.

Patient selection for endogenous interventional procedures depending on type of obstruction

a. Patients with isolated IVC obstruction were treated by balloon venoplasty with or without stenting through transjugular, transfemoral or combined approach, latter used in cases where Interventional Radiologist failed to cross occlusion/stenosis with single access approach.

b. Patients with isolated HV involvement were assessed with colour Doppler US before procedure. Those with dilated and patent main HV or accessory HVs including caudal HVs and right inferior HV proximal to obstruction were treated by angioplasty with or without stenting using transjugular (Figure 1) or combined percutaneous and transjugular approach. If there was no suitable hepatic vein for recanalisation and large venovenous collateral (>8 mm) was seen, then collateral venoplasty or stenting was attempted in a similar fashion. If the hepatic vein recanalization was deemed not possible due to long segment occlusion, TIPS (Figure 2) was offered. If physiological recanalization failed, then switch over to TIPS was done.

c. For treatment of patients with combined IVC and HV involvement, balloon venoplasty or stenting of IVC and HV was done. However, in the absence of any suitable HV or collateral, IVC angioplasty/stenting along with TIPS was offered in the same sitting (Figure 3).

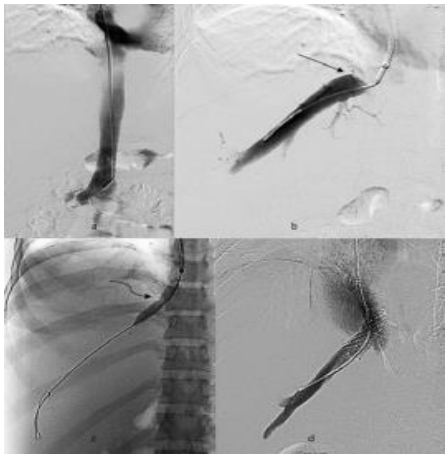

Figure 1) *a. Inferior vena cavogram using diagnostic catheter from trans-jugular approach suggestive of normal opacification of distal inferior vena cava uptil right atrial junction. b. Right hepatic venogram suggestive of linear occlusion (arrow) at hepatic vein ostium likely representing web. c. Fluoroscopic image during balloon venoplasty at right hepatic vein ostium with waist (curved arrow) at level of the occlusion. d. Right hepatic venogram after insertion of self-expandable metallic stent at the ostium suggestive of normal opacification of right hepatic vein with normal contrast flow into the inferior vena cava and right atrium*

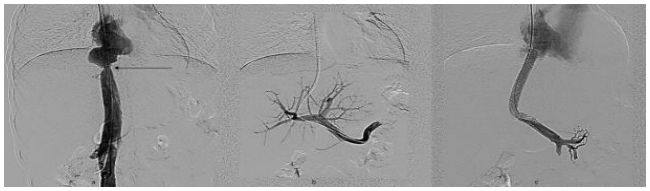

Figure 2) *a. Inferior vena cavogram using diagnostic catheter from trans-jugular approach suggestive of normal opacification of distal inferior vena cava uptil right atrial junction. Subtle narrowing noted at the expected location of hepatic vein ostia (arrow). No significant pressure gradient noted across the narrowing. b. After puncture of segmental branch of right portal vein and with diagnostic catheter placed in splenic vein, splenic venogram suggestive of normal opacification of distal splenic vein, portal vein and its intra-hepatic branches. c. After placement of combination of covered and uncovered metallic stent across the trans-hepatic tract between portal vein and inferior vena cava, portal venogram suggestive of normal opacification of the main portal vein and the stent with normal flow across distal aspect of stent into the supra-hepatic inferior vena cava and right atrium*

Technique

Recanalization of IVC

After securing chosen venous access with 6 Fr sheath under aseptic precautions, local anesthetic cover and Seldinger technique, a 5 Fr multi-purpose (MPA) catheter (Cook, Bloomington, IN, USA) or a 5 Fr kumpe catheter (Cook) was used with a 0.035 "hydrophilic J tip guide wire (Teromo Corporation, Tokyo, Japan) to negotiate past the stenosis/occlusion. In resistant cases, various techniques were used to cross the narrowing like using straight tip hydrophilic guide wire or stiff end of the hydrophilic guide wire, dual access approaches (Figure 1) and many others. Once the narrowing was crossed, the guide wire was exchanged with an 260 cm, 0.035" extra stiff amplatz guide wire (Cook) and the stenotic segment was dilated using a balloon catheter followed by stenting if any residual stenosis (confirmed by resistant balloon waist or cavography after dilatation) or pressure gradient persisted. Choice of various balloons and stents were available and used. Balloon dilatation was sequential with dilatation using smaller diameter balloon (10 mm) followed by larger diameter balloons (maximum up to 26 mm).

Recanalization of HV/collaterals

Under similar precautions right internal jugular vein was punctured and access secured using 10-F, 40-cm-long sheath (Cook). Using MPA catheter with 0.035" straight tip hydrophilic guide wire or metal cannula (from Rosch-Uchida transjugular liver access set) in difficult cases, HV/accessory HV cannulation was attempted (Figure 2) and recanalization of the parent vessel/collateral was done using similar technique as described for IVC recanalization above. In resistant cases where cannulation of HVs was not possible or crossing the stenosis/narrowing was not successful, percutaneous puncture of the suitable hepatic veins was done under sonographic guidance using 18 G puncture needle (Vygon, Ecouen, France) and a 0.035" straight tip hydrophilic guide wire (Teromo Corporation) was passed into the hepatic vein and used to cross the occlusion. In resistant cases, stiff end of the wire was used to cross the narrowing and after crossing, exchanged with the floppy end of the wire. The wire was snared from the transjugular end and rest of the procedure or angioplasty with/without stent insertion was continued as described earlier.

TIPS

In case where long segment occlusion or complete occlusion/thrombosis of the hepatic veins was found and no collateral or suitable accessory

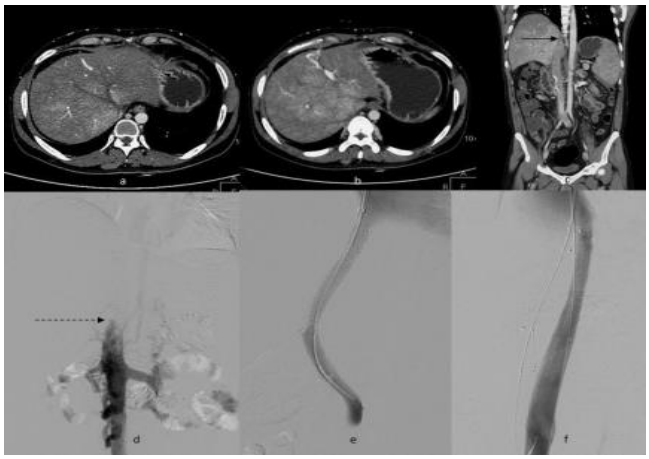

Figure 3) *a. Axial CT abdomen section (venous phase) at level of hepatic vein ostia suggestive of non-opacification of all hepatic veins. b. Axial CT abdomen section at another level suggestive of heterogeneous enhancement of hepatic parenchyma suggestive of congestion with subcapsular collateral from left branch of portal vein. c. Coronal reformat CT abdomen image (venous phase) suggestive of occlusion of retro-hepatic inferior vena cava (arrow). d. Inferior vena cavogram confirmatory of the occlusion (broken arrow). e. After insertion of trans-jugular intrahepatic porto-systemic shunt across portal vein and inferior vena cava, portal venogram suggestive of normal flow across the shunt into the supra-hepatic inferior vena cava and right atrium. f. Inferior hepatic venogram after subsequent placement of inferior vena cava stent suggestive of normal opacification of stent lumen with flow of contrast into the right atrium and no residual stenosis/narrowing*

hepatic vein was deemed feasible on Doppler study, TIPS was considered as intervention of choice. The procedure was carried out using Rosch-Uchida transjugular liver access set (Cook). A transjugular access was secured using the 10 Fr long sheath from the set. A metal cannula was used within the sheath and wedged to the IVC just below cavo-atrial junction. If a short ostial segment of the HV was cannulated, then a MPA catheter was used to cannulate the HV and the metal cannula exchanged with it and translated forward uptil the occlusion. A Rosch Uchida catheter Stylet set was inserted coaxially into the sheath cannula assembly and translated forward into the hepatic parenchyma under fluoroscopic and sonographic guidance (provided by a second operator) targeting the posterior branch of right portal vein. As soon as portal vein was punctured, a J tip hydrophilic guidewire was introduced into the portal vein and a 5 Fr MPA catheter used for portal venography. Pressure measurements were done in portal vein and caval/right atrial end. An extra stiff amplatz guide wire was used for balloon dilatation of the hepatic parenchymal tract (Mustang- 8 mm) followed by insertion of a 10 mm covered stent within the hepatic parenchymal tract (Fluency Plus; Bard Peripheral Vascular, Tempe, USA) upto the portal vein. This was followed by placement of another 10 mm diameter bare metal stent (E-luminex, Bard Peripheral Vascular, and Tempe, USA) within the covered stent, extending 2 cm into the portal vein lumen (Figure 3). Portal venography and pressure gradient was measured again.

Follow up and surveillance

After the successful radiological intervention patients were kept on anticoagulation viz 5000 IU low molecular weight heparin (dalteparin sodium) 12 hourly and acenocoumaral (acitrom) once daily dosage for 2 days after checking INR. Consequently, heparin was withheld and acitrom was continued lifelong/until next intervention to keep target INR between 2 to 3. Patients were followed up with standard protocol at 3rd day and one month, followed by every 3rd month for 1 year and then every 6 months after completion of one year. Follow up data was terminated at death, end of study period or at the date of last follow up in cases that were lost to follow up. Follow up data was collected from medical record or by telephonic interview. Stent patency was assessed at each follow up visit using colour Doppler ultrasound. Patients with suspicion of stenosis on color Doppler were taken for conventional venography and re-intervention was done if stent stenosis/ thrombosis was present or if significant pressure gradient across stent noted.

Definitions

Technical success of the intervention was defined as completion of the angioplasty, stenting or TIPS creation with fall of the pressure gradient across the shunt/recanalized segment to <8 mm Hg.

Primary patency was defined as the time interval from first intervention to next intervention while secondary patency was defined as stent patency amongst the patients with stent occlusion/stenosis after reintervention, ending with complete occlusion not amenable to endovascular therapy.

Statistical analysis

2 technical failure cases and 3 patents that died due to unrelated causes were excluded during outcome analysis. Overall survival and primary patency analysis was done using Kaplan–Meier curves. Statistical analysis was performed using SPSS version 22 statistical software. $p<0.05$ was considered significant.

RESULTS

During the study period from April 2010 to December 2016, 46 patients with Budd-Chiari syndrome undergoing radiological intervention were analyzed (Figure 4). Technical success was achieved in 44 (95.6%) patients. Selective venoplasty without stenting was done in 7 patients while 22 patients underwent combined venoplasty and stenting of the diseased vein. TIPS were placed in 15 patients. Isolated TIPS was successfully done in 11 patients with satisfactory gradient across the porto-systemic shunt. One patient had combined IVC stenting with TIPS while 3 had combined IVC plasty and TIPS stent placement. Two patients with complete occlusion of all three hepatic veins and large intrahepatic collaterals underwent stenting of the collateral vein (Figure 4).

Technique failure was seen in 2 patients. One patient had long segment IVC obstruction leading to failure of crossing the occlusion by combined transjugular and transfemoral route. He was started on medical management but was lost to follow up. Another one had failure due to non-cannulation of hepatic veins from both transjugular and percutaneous transhepatic approaches and patient refused TIPS placement. During follow up period, three patients were lost to follow up after 6, 8 and 16 months. The patients were included in the outcome and survival analysis and their event status was marked as censored in the Kaplan Meyer survival curve analysis.

Five patients expired during the follow up period. The underlying causes of death were liver failure (n=1), cardiac disease (n=1), non-hepatic malignancy (n=1), venous thrombosis (n=1) and unknown in one patient. These patients expired during a mean follow-up of 12.8 months (range=0.4, 3, 4, 12 and 45 months). Since the cause of death was related to Budd Chiari syndrome or its treatment in only 2 patients (at 3 and 12 months), rest of the 3 patients (at 0.4, 4 and 45 months) were excluded from outcome and survival analysis. Repeat intervention was required in 7 (15.9%) patients among whom, 4 patients had occlusion of all 3 hepatic veins, 1 patient had combined disease

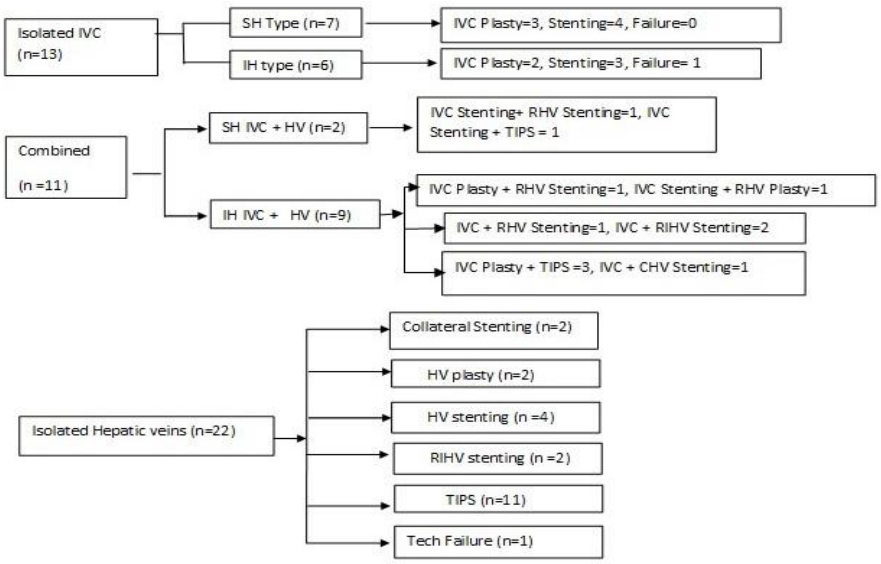

Figure 4) *Line diagram representing the disease level- inferior vena cava (sub-stratified as supra-hepatic vs. infra-hepatic) vs. hepatic vein vs. combined involvement and primary intervention done in each case. Amongst 46 cases, technical failure was met in 2 cases, 1 infra hepatic IVC occlusion and another hepatic vein disease. IVC- Inferior vena cava. SH- Supra-hepatic. IH- Infra-hepatic. HV – Hepatic vein. RHV- Right hepatic vein. TIPS- Trans-jugular intra-hepatic porto-systemic shunt. RIHV- Right inferior accessory hepatic vein. Tech- Technical*

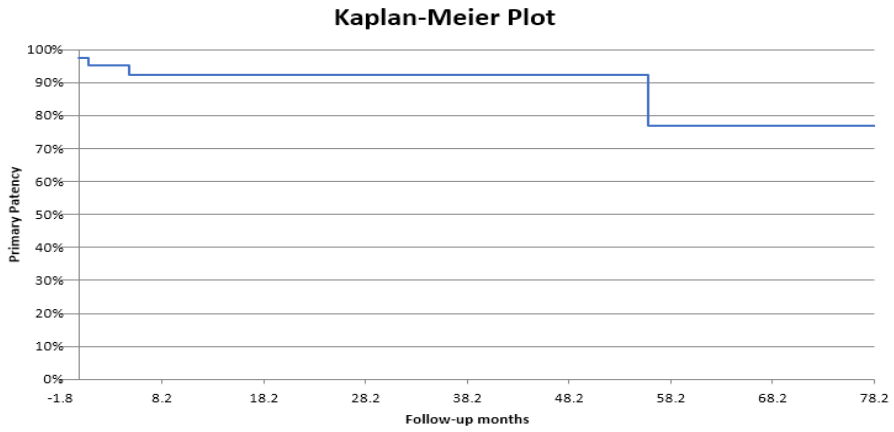

Figure 5) *Kaplan meyer curve representing primary patency rate after the first intervention*

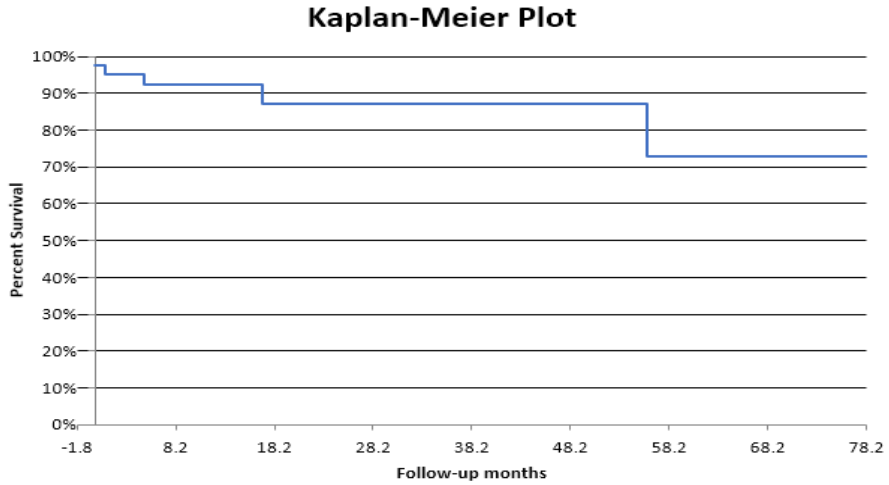

Figure 6) *Kaplan meyer curve representing overall/actuarial survival*

of hepatic vein and inferior vena cava and 2 patients had web in the inferior vena cava (one patient with supra hepatic disease and one patient with intra hepatic disease). The patients had been treated previously by TIPS creation for the first 4 patients, venoplasty and stenting for the patient with combined HV and IVC disease and venoplasty for the patients with IVC web. Among patients who underwent TIPS and required repeat intervention, narrowing of the shunt at the portal end was encountered in 3 patients while narrowing at the vena caval end was seen in one patient. Technical success was achieved in all these patients. All patients with narrowing at portal end successfully responded to balloon dilatation. One patient with narrowing at vena caval end was initially treated successfully with re-stenting; however the occlusion recurred again at 47 months and was managed with balloon angioplasty and anticoagulant cover. Remaining three patients who underwent venoplasty with or without stenting were intervened with repeat balloon dilatation which was successful in all patients. The cumulative primary patency rates at 6 months, 12 months, 2 years, and 5 years were 92.6%, 85.3%, 73.1% and 70.7% respectively (Figure 5) and cumulative secondary patency rates at 6 months, 12 months, 2 years and 5 years were 100%, 100% 100% and 100% respectively.

The transplant-free/cumulative actuarial survival at 6 months, 12 months, 2 years, and 5 years were 95.1%, 90.2%, 87.8% and 87.8% respectively (Figure 6).

2 patients had complications in the form of transient pulmonary edema post TIPS in 1 patient and heparin induced hematuria in the other. Both of the complications were conservatively managed.

DISCUSSION

Various patterns of venous obstruction are seen in BCS patients all over the world. While geographic variations in pattern of venous outflow involvement exist, recent literature reports from East and India show change in disease profile with combined IVC and HV obstruction or isolated HV obstruction being more common (3-6). Isolated HV occlusion (47.8%) was the most common pattern in our study also which is similar to these studies. The cumulative primary patency rates in current study are comparable to recent studies done in China and India (6,7). The cumulative overall survival rate in our study was also comparable to that of patients treated with TIPS (8) or liver transplant (9) in western studies. Mukund et al. (9) studied outcomes and survival in 136 patients diagnosed with budd chiari syndrome after performing HV/IVC anatomic recanalization or Direct intra-hepatic porto-systemic shunting (DIPS). They concluded that both techniques had similar efficacy and resultant patient survival but the improvement in liver functions tests and hepatic elastographic changes was better in the anatomic recanalization group. The findings of improved clinical and biochemical parameters in anatomic hepatic venous outflow recanalization with added risks of hepatic encephalopathy and liver dysfunction in patients of DIPS necessitates anatomic recanalization to be the first offered intervention choice in patients with BCS. The dictum of endovascular management was that if there was long segmental hepatic venous narrowing or complete non-visualization of all hepatic veins, then DIPS remained the only endovascular intervention that could be offered. However, with detailed understanding of accessory hepatic venous anatomy and hemodyamics and hepatic venous collateral circulation, other physiologic recanalization procedures like accessory vein recanalization and collateral vein recanalization started being offered to defer DIPS. The cohort with such angio-architecture is not very uncommon. The understanding of accessory vein and collateral anatomy also enabled maneuver/tricks for successful orthotopic hepatic vein recanalization like floss/loop approach described in few studies (10,11). Our study highlights the importance of draining collaterals and accessory hepatic veins to avoid early TIPS in a subset of patients. Apart from the three major orthotopic cephalad draining veins of liver namely right, middle and left hepatic veins, there are other caudal draining veins described in literature namely the accessory hepatic veins. The most common accessory HV is inferior right hepatic vein (IRHVs). Accessory veins draining caudate

lobe are also distinctly appreciated. The incidence of IRHVs in normal population is still controversial. On the basis of autopsies, the incidence reported is between 61 -88%, while on the basis of color Doppler and CT the incidence is lower ranging from 10-47% (12,13). However, the diameter of IRHV is highly variable. Trotovsek (14) and Hwang (15) reported the mean diameter of IRHVs to be 7.0 ± 2.1 mm (range, 1.9-13.7 mm). Since, the diameter of the accessory hepatic vein which can be used in venous reconstruction during liver transplant needs to be large (>5 mm) to avoid graft congestion or atrophy, we took threshold diameter of >8 mm for safe recanalization of accessory hepatic veins keeping the same concept in mind. Accessory hepatic vein recanalization in the setting of complete occlusion of main hepatic veins was done in 5 cases. Out of these 4 were on right side and one was on left side. None of these patients required re-intervention. Hence, by adequate assessment of accessory hepatic venous anatomy, caliber and hemodynamics TIPS can be avoided in selected patients. Fu et al., shared their experience of recanalization of accessory hepatic veins in 20 patients with non-recanalizable orthotopic HVs and presence of dilated accessory HVs having membranous/short segmental ostial stenosis (16). They suggested that this cohort of patients exists because collateral supply leads to compensatory dilatation of the accessory HV stem but fails to dilate the accessory HV ostium because that is restricted by the IVC wall. The authors achieved technical success rate in all 20 patients with venoplasty/stenting and secondary patency of 100% in all patients, after re-intervention in 3 patients. Cai et al. studied the number, course, diameter, orifice, lesions and hemodynamics in obstructed and unobstructed Accessory HVs in 300 patients and concluded that ultrasonography combined with Doppler was superior to digital subtraction angiography, CT angiography and Magnetic resonance imaging for characterizing accessory HV lesions and hemodynamics (17). Obstruction to hepatic venous drainage in BCS patients leads to development of collateral pathways which serve as an alternative pathway for venous return to systemic circulation. Intrahepatic collaterals can either drain into systemic veins through sub-capsular venous plexus or shunt blood from occluded to non-occluded hepatic veins which are then seen as comma shaped veno-venous collaterals, best depicted on ultrasound. Baijal et al. observed that in patients with both HV and IVC obstruction, recanalization of IVC alone was effective if there was a large collateral vessel draining into IVC via orthotopic/accessory venous route (18). Thus in cases with complete or near complete HV obstruction, recanalization of dilated veno-venous collaterals, if present, can restore adequate physiological flow. The importance of collateral assessment and recanalization was reported in an Indian study by Mammen et al. who reported 4 cases of collateral recanalization where the collateral shared its ostium with adjacent accessory veins (19). In our study, 2 patients with isolated HV obstruction underwent collateral venoplasty and stenting none of whom required repeat intervention till now, at 21 and 26 months of follow up. A case-by case approach is necessary because the incidence of accessory hepatic veins and presence of dilated collateral vessel is variable, making these recanalization procedures suitable only for selected patients. However, for the patients not amenable to medical therapy, angioplasty or stenting, TIPS has emerged as an excellent treatment option (8). In our study, TIPS was performed in 15 patients with a technical success rate of 100%. None of our patients under went liver transplant and the overall survival rates are comparable to transplant free 5-year survival rates of other studies (20). Post TIPS survival in our study is also similar to post liver transplant survival in BCS patients (9). The study had many limitations. The foremost limitation was the retrospective nature of the study and no comparison arm for patients undergoing alternative management. The sample size was relatively small for deriving statistical analysis powered to a greater significance. The operators chose the interventions after Doppler study based on their experience and expertise, which could have potentially introduced bias in intervention choice. In conclusion, our study demonstrates the efficacy of physiologic venous recanalization and TIPS for BCS in Indian patients. It particularly highlights the importance of accessory hepatic vein and collateral recanalization in achieving adequate physiologic hepatic venous drainage so that TIPS and associated complications can be avoided in selected patients with non recanalizable orthotopic HVs.

CONCLUSION

We conclude that endovascular intervention has excellent outcome in management of Budd Chiari Syndrome cases refractory to medical treatment. Besides orthotropic hepatic vein recanalization, physiological recanalization in form of accessory hepatic vein stenting or collateral vein stenting is also alternatives. TIPS should only be offered where physiologic recanalization is not feasible.

REFERENCES

1. DeLeve LD, Valla DC, GarciaTsao G. Vascular disorders of the liver. Hepatolo. 2008;49(5):1729-64.
2. Slakey DP, Klein AS, Venbrux AC, et al. Budd-Chiari syndrome: Current management options. Annl surger. 2001;233(4):522-7.
3. Dilawari JB, Bambery P, Chawla Y, et al. Hepatic outflow obstruction (Budd-Chiari syndrome): Experience with 177 patients and a review of the literature. Med. 1994;73:21-36.
4. Mohanty D, Shetty S, Ghosh K, et al. Hereditary thrombophilia as a cause of Budd-Chiari syndrome: A study from Western India. Hepatolo. 2001;34:666-70.
5. Eapen CE, Mammen T, Moses V, et al. Changing profile of Budd Chiari syndrome in India. Indian J Gastroenterol. 2007;26:77-81.
6. Mukund A, Mittal K, Mondal A, et al. Anatomic recanalization of hepatic vein and inferior vena cava *vs.* direct intrahepatic portosystemic shunt creation in budd-chiari syndrome: Overall outcome and midterm transplant-free survival. J Vascul Int Radiolo. 2018; 29(6):790-9.
7. Han G, Qi X, Zhang W, et al. Percutaneous recanalization for Budd-Chiari syndrome: an 11-year retrospective study on patency and survival in 177 Chinese patients from a single center. Radiolo. 2013;266(2):657-67.
8. Garcia–Pagán JC, Heydtmann M, Raffa S, et al. TIPS for Budd-Chiari syndrome: Long-term results and prognostics factors in 124 patients. Gastroenterolo. 2008;135(3):808-15.
9. Mentha G, Giostra E, Majno PE, et al. Liver transplantation for Budd–Chiari syndrome: A European study on 248 patients from 51 centres. J hepatolo. 2006;44(3):520-8.
10. Da-Silva FP, Donato P, Caseiro-Alves F. Collteral loop approach from left to right liver lobe: Endovascular recanalization of a hepatic vein in Budd-Chiari syndrome. Eur J radiolo open. 2016;3:251-3.
11. Weaver JJ, Dobrow EM, Hsu EK, et al. Single-access liver floss technique with antegrade hepatic vein access and recanalization in Budd-Chiari syndrome. Diagno Int Radiolo. 2018;24(1):38.
12. Li X, Xeusong X, Gainping G. Clinical significance of inferior right hepatic vein. Ame J Med Case Rep. 2016;4(1):26-30.
13. Orguc S, Tercan M, Bozoklar A, et al. Variations of hepatic veins: Helical computerized tomography experience in 100 consecutive living liver donors with emphasis on right lobe. In Transpla procee. 2004;36(9):2727-32.
14. Trotovsek B, Gadzijev EM, Ravnik D, et al. Liver hanging maneuver for right hrmiliver *in situ* donation-anatomical considerations. HPB (Oxford). 2006;8(1):35-7.
15. Hwang JW, Park KM, Kim SC, et al. Surgical impact of an inferior right hepatic vein on right anterior sectionectomy and right posterior sectionectomy. ANZ J Surg 2014;84: 59-62.
16. Fu YF, Xu H, Zhang K, et al. Accessory hepatic vein recanalization for treatment of Budd-Chiari syndrome due to long-segment obstruction of the hepatic vein: Initial clinical experience. Diagno Inte Radiolo. 2015;21(2):148.
17. Cai SF, Gai YH, Ma S, et al. Ultrasonographic visualization of accessory hepatic veins and their lesions in Budd–Chiari syndrome. Ultrasound in medicine & biology. 2015;41(8):2091-8.
18. Baijal SS, Roy S, Phadke RV, et al. Management of idiopathic Budd-Chiari syndrome with primary stent placement: Early results. J Vasc Interv Radiol. 1996;7:545-53.
19. Mammen T, Keshava S, Eapen CE, et al. Intrahepatic collateral recanalization in symptomatic Budd-Chiari syndrome: A single-center experience. J Vascul Int Radiolo. 2010;21(7):1119-24.
20. Akamatsu N, Sugawara Y, Kokudo N. Budd-Chiari syndrome and liver transplantation. Intractable Rare Dis Res. 2015;4(1):24-32.