

Rash caused by sticky patch: Contact dermatitis due to adhesive tape containing zinc oxide 20%: A case report

Suryawanshi M^{1*}, Singh S², Mulchandani PD², Banker N³

Suryawanshi M, Singh S, Mulchandani PD, et al. Rash caused by sticky patch: Contact dermatitis due to adhesive tape containing zinc oxide 20%: A case report. *J Skin*. 2021;5(5):11-13.

Medical adhesives tapes are versatile, safe and easy-to-use solution for fastening, sealing, masking, or joining, they provide both essential and non-critical instruments and products with security, promote skin protection and healing, and allow non-invasive monitoring. There are various types of tapes

with their different varieties of backing, adhesives, and release liners. We report a case of a female undergone lower segment caesarean section developing irritant contact dermatitis due to medical adhesive tape applied over surgical wound site. This article will also give brief idea about classification, constituents and uses of surgical adhesive tape.

Key Words: *Irritant contact dermatitis; Allergic contact dermatitis; Zinc oxide 20%w/w adhesive tape; Surgical adhesive tapes; Pressure sensitive adhesive; Acrylic adhesive*

INTRODUCTION

Medical adhesives are a component of a number of products, including tapes, dressings, electrodes, ostomy supplies, and patches; they provide both essential and non-critical instruments and products with security, promote skin protection and healing, and allow non-invasive monitoring [1]. Medical adhesives contains various chemicals namely the adhesive hydro abietic acid (an industrial derivative of colophony); a glycerol ester of hydrogenated abietic acid, a wood rosin derivative used as an adhesive; benzoyl peroxide, used to increase the stretch potential of some adhesive tapes; epoxy resin, used to promote adhesion in an adhesive [2] dodecyl maleamic acid and octadecyl maleamic acid, both adhesives; diethyldithiocarbamate, a preservative in an adhesive; tetrahydrofurfuryl acrylate, used as an adhesive; and p-tertbutyl phenol formaldehyde resin, an acrylate polymer used as a contact adhesive owing to its flexibility, strength, and rapid onset of action. If the right procedure is not used while removing adhesive tapes, the surface layers of the skin are removed along with the adhesive substance, which not only damages the durability of the skin, but also induce irritation and the risk of infection, increase the size of the wound, and hinder healing, both of which affects the quality of life of patients. When the skin to adhesive binding is greater than skin cell to skin cell attachment, skin damage occurs. Adhesive removal also results in the breakup of different quantities of superficial epidermal cell membranes, even though there is no apparent damage. Maceration and inflammation, which renders the skin more susceptible to mechanical damage, may result in trapping of moisture under an occlusive tape [3].

In the present study, we report a case of a female undergone lower segment caesarean section and applied medical adhesive tape over surgical wound, causing irritation contact dermatitis due medical tape or its adhesive. Elastic medical adhesive tape used in our patient contained zinc oxide B.P 20 %w/w and natural rubber, although zinc oxide medical tape can be used on almost any external wound, it is especially useful for skin and soft tissue injuries [4].

CASE PRESENTATION

Thirty-one-year-old post-partum female presented to Skin OPD with complains of redness over forearm, which was gradually progressive and associated with itching and burning, she also complained of itching over lower abdomen at the site of dressing. She delivered a full-term healthy baby

by Lower segmental caesarean section 7 days back. She noticed rash over right distal forearm since 6 days at the site of intravenous catheter which was secured with adhesive tape. On removal of dressing on day 7 of lower segmental caesarean section, there was presence of rash at the site of dressing. On clinical examination, there was involvement of distal and lateral aspect of right forearm and lower abdomen in the form of multiple erythematous papules coalescing to form plaques along with multiple vesicles and few erosions, lesion over distal forearm was about 3 × 3 cm and over lower abdomen was about 25 × 7 cm, nearly rectangular in shape and with central sparing. The borders were well defined. Patch test done using Indian standard series was negative. She was prescribed oral antihistaminic and fluticasone propionate 0.05 % cream, twice daily for 15 days with which the lesions dried up in 7 days with mark reduction in erythema and subsequently healed in 15 days without any dyspigmentation.

Mechanism of contact dermatitis

Two major types of CD can be recognised according to the pathophysiological mechanisms involved, namely irritant contact dermatitis (ICD) and allergic contact dermatitis (ACD). Allergic contact dermatitis is a T-cell-mediated skin inflammation caused by repeated skin exposure to contact allergens, i.e., nonprotein chemicals called haptens. Allergic contact dermatitis, also referred to as contact hypersensitivity, is mediated by CD8+ T cells, which are primed in lymphoid organs during the sensitization phase and are recruited in the skin upon re-exposure to the haptens, ACD only occurs in sensitized patients, i.e., individuals who have developed chemical-specific T cells [5]. ACD occurs 24 hours to 96 hours after contact with the haptens. Irritant contact dermatitis has historically been characterised as a non-specific local inflammatory skin reaction after a single or repeated exposure to an irritant [6]. It is widely accepted that a number of mechanisms are involved in the development of ICD, including skin barrier disruption, keratinocyte damage, and the release of proinflammatory mediators that directly recruit and activate T-cells [7-9]. The cytokine cascade possibly begins with a preformed IL-1, which is stored in the Stratum corneum and the keratinocytes [10-12]. It is important to note that if the skin is exposed to sufficiently high concentrations for a long enough period of time, virtually every substance can be considered a cutaneous irritant [13]. In the treatment of irritant contact dermatitis, topical corticosteroids play a small role [14]. When a potential causative allergen is known, the first step in verifying the diagnosis is to decide whether avoidance of the substance resolves the issue. Patch testing may be suggested if avoidance and

¹Department of Surgery, Datta Meghe Medical College, Nagpur, India, ²Department of Dermatology, Datta Meghe Medical College, Nagpur, India, ³Department of Microbiology, Jawaharlal Nehru Medical College, Wardha, India

Correspondence: Mihika Suryawanshi, Department of Surgery, Datta Meghe Medical College, Nagpur, India, Tel: 08888004335; E-mail: mulchandani panku@gmail.com

Received: October 29, 2021, **Accepted:** November 12, 2021, **Published:** November 19, 2021



This open-access article is distributed under the terms of the Creative Commons Attribution Non-Commercial License (CC BY-NC) (<http://creativecommons.org/licenses/by-nc/4.0/>), which permits reuse, distribution and reproduction of the article, provided that the original work is properly cited and the reuse is restricted to noncommercial purposes. For commercial reuse, contact reprints@pulsus.com

empirical treatment do not overcome dermatitis or if the allergen remains unknown [15].

DISCUSSION

Before discussing allergic reaction to adhesive tapes, it is prudent to have a basic knowledge regarding the various medical adhesive tapes. An adhesive bandage, also called a sticking plaster, medical plaster, or simply plaster, it protects the wound and scab from friction, bacteria, damage, and dirt. Thus, the healing process of the body is less disturbed [16]. Medical adhesive tape mostly has a tape side (adhesive side), a backing side (carrier), and a release liner (Figure 1). Depending upon the use of adhesive tape, backing (Figure 2) can be made up of transparent plastic, paper, woven article, non-woven synthetic fibers or foam based. Adhesives used in medical practices are commonly used for surgical procedures, while medical adhesives cover a wide range of manufacturing materials; they are typically made up of synthetic or biological formulations. Standard adhesives commonly found in the medical field include the following three types: pressure sensitive, dissolvable, and electrically conductive adhesives. In general, synthetic and biological adhesive materials are included in the two primary medical adhesive composition categories. Formulations shall be tested to meet the criteria of medical safety. Common variants of these adhesive types include: acrylics, silicone, rubber and bio-adhesives. These include the following: the adhesive hydro abietic acid (an industrial derivative of colophony) [17]; a glycerol ester of hydrogenated abietic acid; a wood rosin derivative used as an adhesive[18]; tricresol phosphate, a plasticizer in a vinyl backing; 2,5- di(tertiary-amy)l hydroquinone, antioxidant in an adhesive ; benzoyl peroxide, used to increase the stretch potential of some adhesive tapes [19]; epoxy resin, used to promote adhesion in an adhesive[20]; dodecyl maleamic acid and octadecyl maleamic acid, both adhesives[21]; diethyldithiocarbamate, a preservative in an adhesive[22]; tetrahydrofurfuryl acrylate, used as an adhesive[14-16]; and p-tertbutyl phenol formaldehyde resin, an acrylate polymer used as a contact adhesive owing to its flexibility, strength, and rapid onset of action. A pressure-sensitive adhesive and a lining, which acts as a carrier for the adhesive, make up medical adhesive tapes and bandages. Rubber adhesives are mostly used for indoor applications with low stress requirements and found on masking tapes, duct tapes. Silicone is another common material used in medical bonding typically used for critical applications where the tapes are exposed to extremely high temperatures and/or harsh environments, this material is popular because it is biocompatible, and there are several curing formulations available but is expensive type of adhesive. Polyurethanes are commonly produced in bandage adhesives and are available in different strengths and are efficient in processes and applications due to their water resistance.

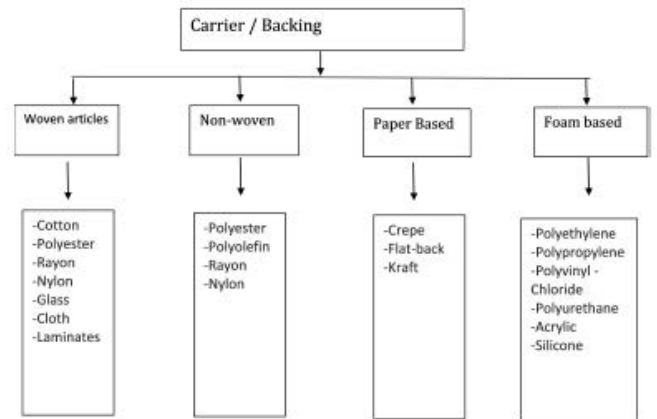


Figure 2) Classification of carrier/backing

To avoid the allergic reactions and instability associated with rubber-based adhesives, single-component adhesives were developed. The combination of an acrylic ester monomer and a polar monomer produces these so-called hypoallergenic adhesives [23], sometimes this component can cause irritant or allergic contact dermatitis to adhesives.

Symptoms of dermatitis can be relieved by cool compresses, and calamine lotion and colloidal oatmeal baths can help dry and soothe acute, oozing lesions [24]. In our patient, she had elastic medical adhesive tape applied which was made up of zinc oxide 20%w/w, it has anti-bacterial, mild astringent properties, aids in wound healing and is soothing to skin. Zinc oxide tape is composed of a lotion web foundation with a composite mixture of gum, resin and zinc oxide paste, presented as 1.25 cm and 2.5 cm diameter rolls each 10 m in length this is a common tape used as there are many advantages of zinc oxide medical adhesive tape like mainly it is not expensive, can be applied easily at home by patient or parent, mostly painless removal is observed. Related studies were reviewed [25]. Our patient might have had allergy to zinc oxide 20 %of tape, which was resolved by antihistamines, topical steroids (Figures 3). There has been very little public knowledge about the variations in the adhesive materials of medical tapes. Exact compositions of the adhesive in tapes are trade secret.

Although most of the reported allergic contact dermatitis cases through medical tapes were due to adhesive portion of the tape but other components like backing which carries the adhesive can also cause allergic or irritant contact dermatitis Patch testing done for suspected allergen were negative.

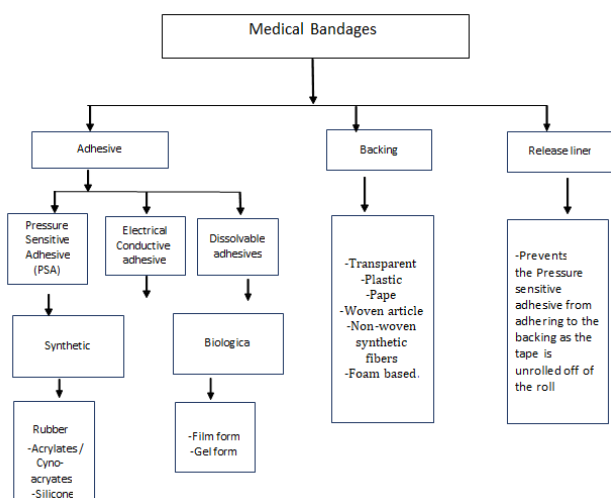


Figure 1) Classification of medical bandages

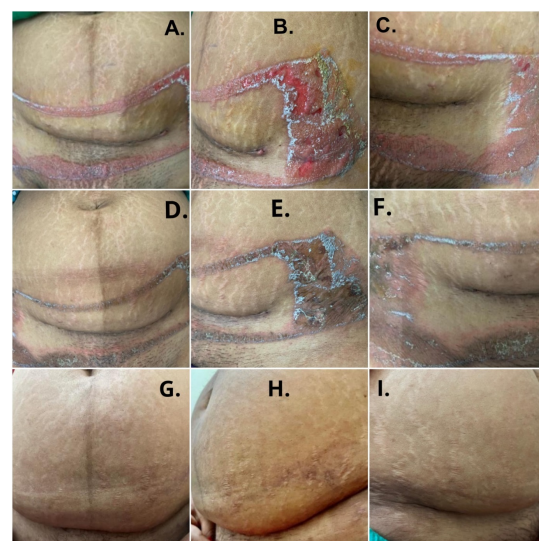

Figure 3) (A-C) Multiple erythematous papules coalescing to form plaques along with few vesicles and erosions, nearly rectangular in shape (D-F) After 7 days-marked decrease in erythema, hyperpigmentation and Crusting seen (G-I) Post 3 weeks forearm lesion healed with hyperpigmentation

CONCLUSION

Contact dermatitis due to adhesive tape are uncommon clinical problem, there are few documents reporting allergic or irritant contact dermatitis to adhesive tapes. We present middle aged female suffering from irritant contact dermatitis to adhesive tape containing zinc oxide 20% w/w. It is important to differentiate between Allergic contact dermatitis and irritant contact dermatitis to adhesive tapes. The diagnosis of contact dermatitis is based on clinical history and examination, patch test and on histopathological examination.

REFERENCES

1. Cutting KF. Impact of adhesive surgical tape and wound dressings on the skin, with reference to skin stripping. *J Wound Care* 2008;17(4): 157-62.
2. Moffitt DL, Sansom JE. Occupational allergic contact dermatitis from tetrahydrofurfuryl acrylate in a medical-adhesive. *Contact Dermatitis* 2001;45(1):54.
3. McNichol L, Lund C, Rosen T, et al. Medical adhesives and patient safety: State of the science consensus statements for the assessment, prevention, and treatment of adhesive-related skin injuries. *J Wound Ostomy Continence Nurs* 2013;40(4):365-80.
4. Hughes G, McLean NR. Zinc Oxide Tape: A useful dressing for the recalcitrant finger-tip and soft-tissue injury. *Arch Emerg Med* 1988;5(4):223-7.
5. Mezard P, Rozie`res A, Krasteva M, et al. Allergic contact dermatitis. *Eur J Dermatol* 2004;14:284-95.
6. Hunziker T, Brand CU, Kapp A, et al. Increased levels of inflammatory cytokines in human skin lymph derived from sodium lauryl sulphate-induced contact dermatitis. *Br J Dermatol* 1992;127(3): 254-7.
7. Levin CY, Maibach HI. Irritant contact dermatitis: is there an immunologic component? *Int Immunopharmacol* 2002;2(2-3):183-9.
8. Mathias CG, Maibach HI. Dermatotoxicology monographs I. Cutaneous irritation: factors influencing the response to irritants. *Clin Toxicol* 1978;13(3):333-46.
9. Lambrecht BN, Leung D. Initiation and maintenance of allergic inflammation: team work at the interface of innate and adaptive immunity. *Curr Opin Immunol* 2011;23(6):769-71.
10. Cumberbatch M, Dearman RJ, Groves RW, et al. Differential regulation of epidermal Langerhans cell migration by interleukins (IL)-1 α and IL-1 β during irritant-and allergen-induced cutaneous immune responses. *Toxicol Appl Pharmacol* 2002;182(2):126-35.
11. Enk AH, Katz SI. Early molecular events in the induction phase of contact sensitivity. *Proc Natl Acad Sci USA* 1992;89(4):1398-402.
12. Choi JM, Lee JY, Cho BK. Chronic irritant contact dermatitis: recovery time in man. *Contact Dermatitis* 2000;42(5):264-9.
13. Levin C, Zhai H, Bashir S, et al. Efficacy of corticosteroids in acute experimental irritant contact dermatitis? *Skin Res Technol* 2001;7(4): 214-8.
14. Le TK, De Mon P, Schalkwuk J, et al. Effect of a topical corticosteroid, a retinoid and a vitamin D3 derivative on sodium dodecyl sulphate induced skin irritation. *Contact Dermatitis* 1997;37(1):19-26.
15. Bourke J, Coulson I, English J. Guidelines for the management of contact dermatitis: an update. *Br J Dermatol* 2009;160(5):946-54.
16. Spencer A, Gazzani P, Thompson DA. Acrylate and methacrylate contact allergy and allergic contact disease: a 13-year review. *Contact Dermatitis* 2016;75(3):157-64.
17. Cronin E, Calnan CD. Allergy to hydroabietic alcohol in adhesive tape. *Contact dermatitis* 1978;4:57.
18. Sjoborg S, Fregert S. Allergic contact dermatitis from a colophony derivative in a tape skin closure. *Contact Dermatitis* 1984;10(2):114-5.
19. James WD. Allergic contact dermatitis to a colophony derivative. *Contact dermatitis* 1984;10(1):6-10.
20. Norris P, Storrs FJ. Allergic contact dermatitis to adhesive bandages. *Dermatol Clin* 1990;8(1):147-52.
21. Taylor JS, Bergfeld WF, Guin JD. Contact dermatitis to knee patch adhesive in boys' jeans: a nonoccupational cause of epoxy resin sensitivity. *Cleve Clin Q* 1983;50(2):123-7.
22. Burden AD, Lever RS, Morley WN. Contact hypersensitivity induced by p-tert-butylphenol-formaldehyde resin in an adhesive dressing. *Contact dermatitis* 1994;31(4):276-7.
23. Avenel-Audran M, Goossens A, Zimerson E, et al. Contact dermatitis from electrocardiograph-monitoring electrodes: role of p-tert-butylphenol-formaldehyde resin. *Contact Dermatitis* 2003;48(2): 108-11.
24. Matzinger P. Tolerance, danger, and the extended family. *Annu Rev Immunol* 1994;12(1):991-1045.
25. Matzinger P. The danger model: A renewed sense of self. *Science* 2002;296(5566):301-5.