

Purely laparoscopic anatomical liver resection: Right anterior sectionectomy

Takao Ide*, Tomokazu Tanaka, Hirokazu Noshiro

Ide T, Tanaka T, Noshiro H. Purely laparoscopic anatomical liver resection: Right anterior sectionectomy. *Gen Surg: Open Access* 2020;3(1):19.

ABBREVIATIONS

Ant: Right Anterior Glissonean Pedicle; IVC: Inferior Vena Cava; RHV: Right Hepatic Vein; MHV: Middle Hepatic Vein

COMMENTARY

In right anterior sectionectomy, isolation of the right anterior Glissonean pedicle and exposure of the middle (MHV) and right hepatic veins (RHV) on the liver transection planes are essential for carrying out anatomical liver resection safely and securely [1,2]. In order to perform this procedure a purely laparoscopic approach, we developed an original surgical procedure based on the isolation of the extrahepatic Glissonean pedicle at the hilum and consequently comprising four transection planes selected according to anatomical landmarks [3].

In the isolation of the Glissonean pedicle at the hilum, the caudal view with magnifying visual recognition, which is the strongest advantage of this approach and can only be achieved laparoscopically, should be used as much as possible. The counter traction achieved by pulling the gallbladder, including the cystic plate, helps achieve a good view of the hepatic hilum and facilitates the isolation of the targeted Glissonean pedicle (Figure 1).

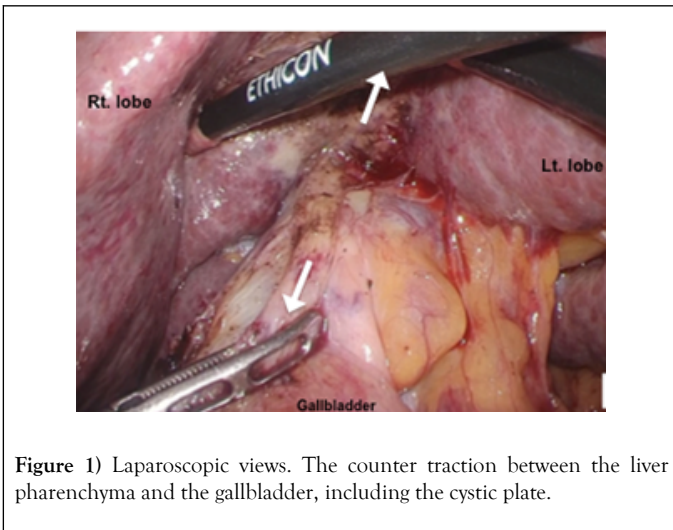


Figure 1 Laparoscopic views. The counter traction between the liver pharenchyma and the gallbladder, including the cystic plate.

Careful dissection of the tiny connective tissue and thin Glissonean capsule around the right anterior Glissonean pedicle while paying attention to the surgical anatomy based on Laennec's capsule is important for extrahepatic isolation without parenchymal destruction (Figure 2) [4].

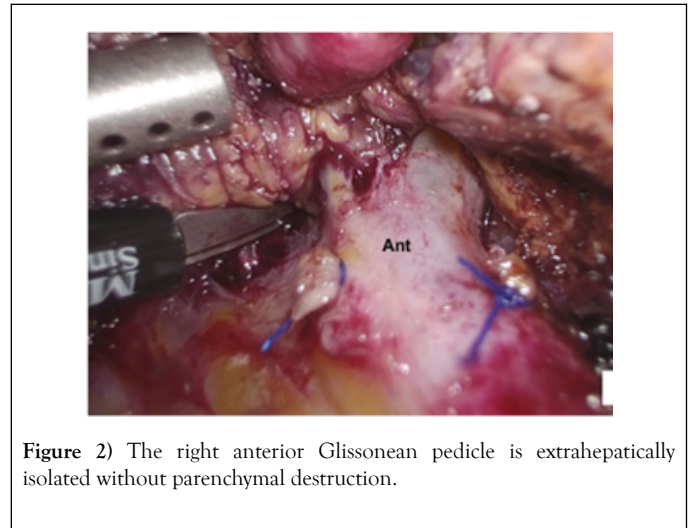


Figure 2 The right anterior Glissonean pedicle is extrahepatically isolated without parenchymal destruction.

The selective anterior segment inflow is temporary occluded by ligation using 3-0 polypropylene thread after confirming the ischemic area using a bulldog clamp.

However, the low spatial perception ability, which is the weak point of laparoscopic surgery, must be resolved when creating appropriate transection planes. Establishing anatomical landmarks is thus an indispensable step in overcoming this disadvantage, especially in right anterior sectionectomy, which demands relatively wide transection planes. In this procedure, the anatomical landmarks are the demarcation line, MHV, right anterior Glissonean pedicle, and RHV. Liver parenchymal transection consequently consists of four sequential planes according to these anatomical landmarks. The first transection is started between the internal and anterior sections along with the demarcation line and ventral to the MHV (Plane 1). The MHV is then exposed from the IVC side toward the peripheral side to avoid splitting the bifurcation of the hepatic veins [5].

Transection of the parenchyma is then performed from dorsal to the MHV to the right anterior Glissonean pedicle (Plane 2). On the third transection plane, the parenchymal between the anterior and posterior sections is transected from the IVC side of the RHV (the dorsal side) toward the right anterior Glissonean pedicle (Plane 3) (Figure 3).

Department of Surgery, Saga University, Saga, Japan

*Correspondence: Takao Ide, Department of Surgery, Saga University, Saga, Japan, E-mail: idetaka@cc.saga-u.ac.jp

Received date: April 28, 2020; Accepted date: May 12 2020; Published date: May 19, 2020



This open-access article is distributed under the terms of the Creative Commons Attribution Non-Commercial License (CC BY-NC) (<http://creativecommons.org/licenses/by-nc/4.0/>), which permits reuse, distribution and reproduction of the article, provided that the original work is properly cited and the reuse is restricted to noncommercial purposes. For commercial reuse, contact reprints@pulsus.com

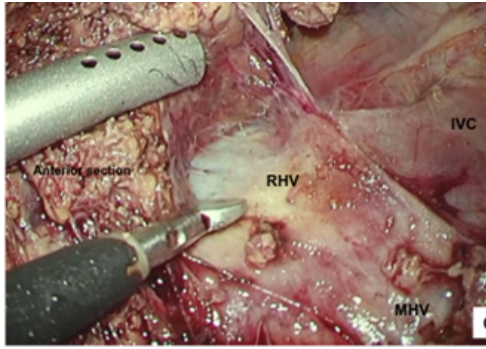


Figure 3) The RHV is exposed from the IVC side toward the peripheral side.

We subsequently divide the right anterior Glissonean pedicle with a linear stapler after obtaining sufficient space around the right anterior Glissonean pedicle. Finally, the resection plane is completed by performing parenchymal transection between the demarcation line and the area ventral of the RHV (plane 4) (Figure 4).

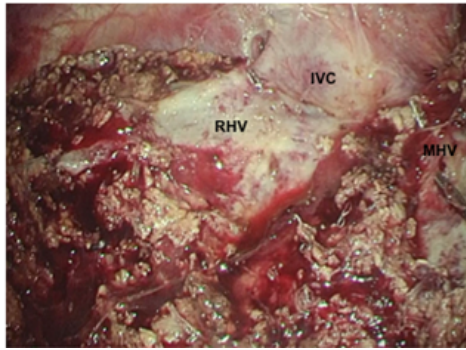


Figure 4) A laparoscopic view of the transection planes after completing right anterior sectionectomy.

Changing the access ports appropriately is important for maintaining the proper direction of parenchymal transection. During parenchymal transection, an ICG fluorescence navigation system is routinely used to help identify the tumor margins and confirm the appropriate transection planes.

This standardized procedure using the isolation of the targeted Glissonean pedicle at the hilum with appropriate transection planes established sequentially according to anatomical landmarks makes purely laparoscopic right anterior sectionectomy feasible. These surgical techniques may also be applicable for other anatomical liver resections via a laparoscopic approach.

REFERENCES

1. Kirchner VA, Kim KH, Kim SH, et al. Pure laparoscopic right anterior sectionectomy for hepatocellular carcinoma with great vascular exposure. *SurgEndosc* 2017; 31: 3349-50.
2. Wakabayashi G, Cherqui D, Geller DA, et al. Recommendations for laparoscopic liver resection: A report from the second international consensus conference held in Morioka. *Ann Surg*. 2015; 261: 619-29.
3. Ide T, Matsunaga T, Tanaka T, et al. Feasibility of purely laparoscopic right anterior sectionectomy. *SurgEndosc*. 2020; Epub ahead of print.
4. Sugioka A, Kato Y, Tanahashi Y. Systematic extrahepatic Glissonean pedicle isolation for anatomical liver resection based on Laennec's capsule: proposed of a novel comprehensive surgical anatomy of the liver. *J HepatobiliaryPancreat Sci*. 2017; 24: 17-23.
5. Okuda Y, Honda G, Kobayashi S, et al. Intrahepatic Glissonean pedicle approach to segment 7 from the dorsal side during laparoscopic anatomical hepatectomy of the cranial part of the right liver. *J Am Coll Surg*. 2018; 226: e1-6.