



Pre-omental epigastric redundant sigmoid colon: a case report and review of its functional and clinical implications

Published online February 26th, 2015 © <http://www.ijav.org>

Afadhali Denis RUSSA *

Department of Anatomy, School of Medicine, Muhimbili University of Health and Allied Sciences (MUHAS), Dar es Salaam, TANZANIA.



* Dr. Afadhali Denis Russa
Department of Anatomy
School of Medicine
Muhimbili University of Health
Sciences and Allied Sciences
P. O. Box 65001
Dares Salaam, TANZANIA.
☎ +255 755 524 771
✉ drussa@muhas.ac.tz

Received January 10th, 2014; accepted July 21st, 2014

Abstract

The sigmoid colon is a highly variable part of the gastrointestinal tract. Most of variations occupy the pelvis and lower abdomen and has a strong association with abdominal pathologies. We report a rare case of a high-reaching sigmoid colon which filled the entire space posterior to the anterior abdominal wall up to the lower border of the liver in the epigastrium. The case lacked typical colonic wall features such as haustrations, taenia coli and appendices epiploicae. The case was not associated with apparent functional loss but had high a likelihood of malfunctioning through space-occupying effect, displacements and adhesions, disorders of transit of the digesta and disorders of vascular and neural supply. Reports of extreme anatomical variations of abdominal viscera are of clinical significance. More studies are needed to guide the clinicians for successful management of abdominal conditions with variant anatomy.

© *Int J Anat Var (IJAV)*, 2015; 8: 17-19.

Key words [sigmoid colon] [redundancy] [preomental] [epigastric]

Introduction

The sigmoid colon is continuous with the descending colon proximally and the rectum distally. It is an intraperitoneal organ suspended in a long mesocolon and has a median length of about 25-38 cm. It is highly mobile and quite variable in position and length [1, 2]. A longer than normal sigmoid colon is referred to as a redundant sigmoid colon or dolichosigmoid. Most of these variations are strongly associated with abdominal conditions such as chronic constipation and colicky pains [3]. Anatomically these variants occupy the pelvic cavity or the lower part of the abdomen [1, 4, 5]. A sigmoid colon extending into the upper abdomen is rare. In the present paper we report a case of the sigmoid colonic loop which reached as high as the epigastrium. We also discuss possible functional and clinical implications of this rare finding.

Case Report

During a Dissectional Anatomy Module for the medical students at the Muhimbili University of Health and Allied Sciences (MUHAS) we observed a redundant loop of the sigmoid colon in a male cadaver aged 50 years. The loop was located immediately posterior to the anterior abdominal wall and anterior to the greater omentum (Figure 1). This position

of the redundant loop displaced the omentum towards the left hypochondrium (Figure 2). The redundant loop of the sigmoid colon filled the entire space posterior to the anterior abdominal wall. The displaced omentum was also constricted – obviously interfering with its blood flow. The ileocecal junction was tightly attached to the posterior abdominal and distally continuous with a long, narrow and tortuous vermiform appendix (Figure 3).

Unlike the other parts of the colon, the wall of the redundant loop was flabby and distended. It had a relatively large diameter of 9.5-11.2 cm when compared with the markedly narrower ascending or transverse colon of 3.4-5.1 cm diameter. There were features of a reduced perfusion to the structure. Other parts of the colon seemed normal in location, size and consistency. In the most parts, the loop lacked or had poorly developed features of a typical colon. The appendices epiploicae were markedly reduced in size and in number with minimal amount of fat deposits. Externally the loop lacked the usual haustrations in its wall and the taenia coli were notably absent (Figure 4). The internal wall depicted limited amount of haustration and, despite its large size, the lumen contained little or no fecal material (Figure 5). Interestingly, there were no discernable sites of obstruction proximal to the loop. No

signs of fecal impaction, stasis or colonic perforations were evident.

Discussion

Sigmoid redundancy is a common encounter and it is developmental in origin, commonly due to malrotational disorders of the primitive gut [6]. It mostly occupies the pelvic and lower abdominal cavity. This is the first reported case in the adult whose redundant loops extend as high as the epigastrium beyond the mid-abdomen. Sigmoid redundancy may or may not be associated with overt abdominal problems to the affected person. There is, however, a high likelihood of functional and clinical consequences of such a defect [3].

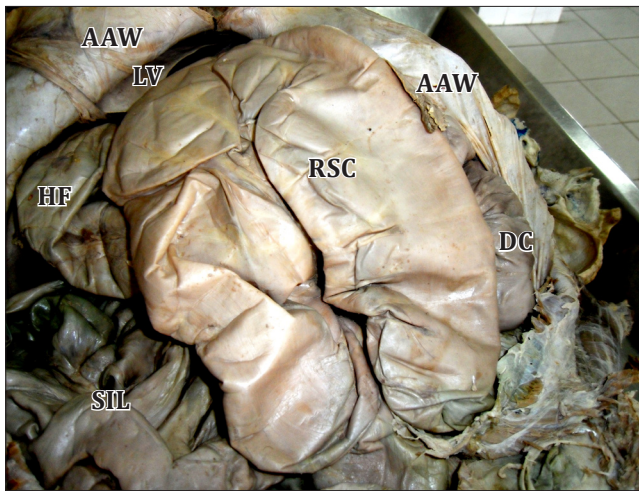


Figure 1. Abdominal viscera in situ. (*RSC*: redundant sigmoid colon; *AAW*: anterolateral abdominal wall; *DC*: descending colon; *HF*: hepatic flexure; *LV*: liver; *SIL*: small intestinal loop)

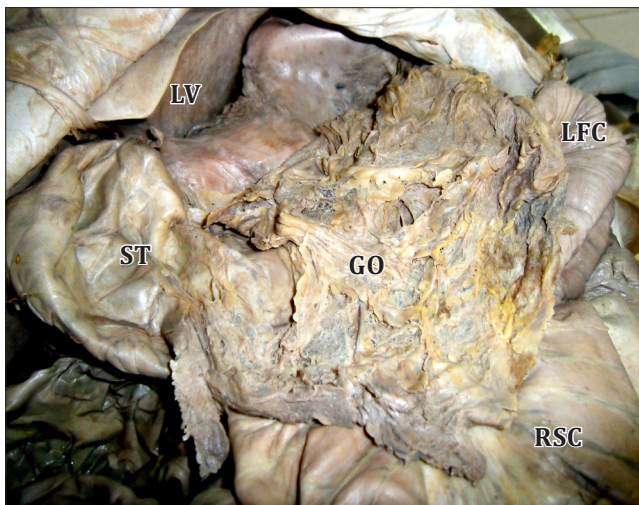


Figure 2. Preomental position of the redundant sigmoid colon (retracted downward). (*LV*: liver; *ST*: stomach; *GO*: greater omentum; *RSC*: redundant sigmoid colon; *LFC*: left colic flexure)

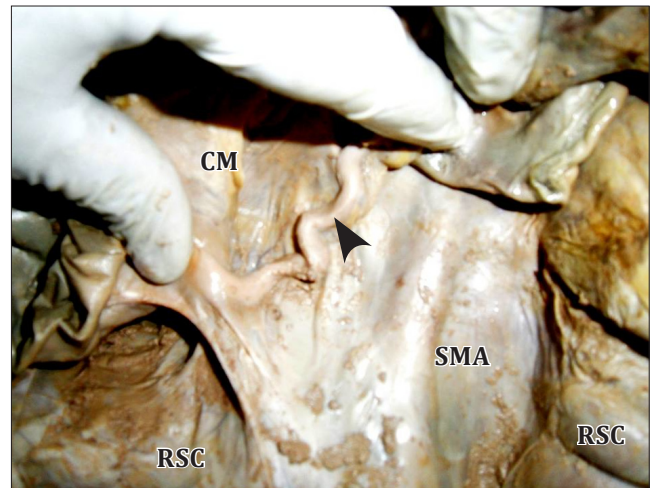


Figure 3. Long tortuous vermiform appendix (arrowhead). (*RSC*: redundant sigmoid colon reflected inferolaterally; *CM*: caecum; *SMA*: sigmoid mesoappendix)

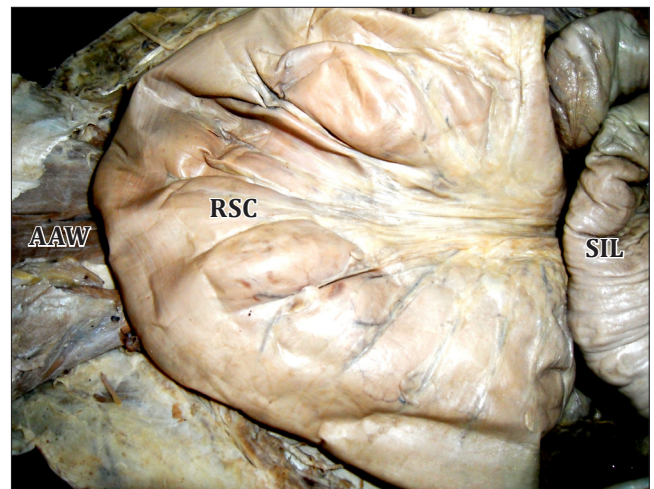


Figure 4. Up close redundant sigmoid colon (*RSC* –retracted left) shows reduced haustrations, taenia coli and flabbiness of the colonic wall. (*AAW*: anterior abdominal wall; *SIL*: small intestinal loop)

From the anatomical and functional viewpoints sigmoid redundancies reaching high in the abdomen are most likely to cause problems to the affected individual by: (1) impingement and space-occupying effect, (2) displacement and adhesions to the neighboring abdominal viscera, (3) disorders of transit of the digesta through the redundant loop and, (4) disorders of vascular and neural supply and lymphatic drainage.

Examination of the present case revealed that the greater omentum was displaced and constricted in structure by the sigmoid redundancy. The primary functions of the omentum are provision of cellular immunity and physical protection of the abdominal viscera. Typically it acts as a barrier against the spread of local infections. Drawn from the basic functions

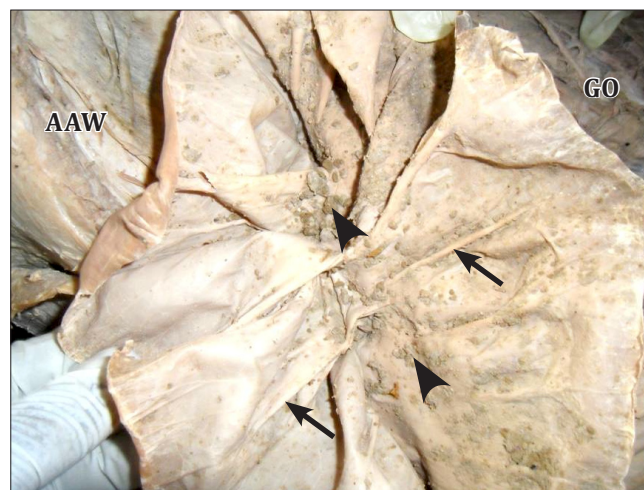

Figure 5. Redundant sigmoid colon opened. (**Arrows:** poorly developed haustrations; **arrowheads:** sparse fecal materials; **AAW:** anterior abdominal wall superolaterally; **GO:** greater omentum)

of the greater omentum, the displacement of the latter in the present case would interfere with its physical mobility and lymphatic drainage hence hindering its immunity roles. The impingement of the redundant loop to the greater omentum would also inhibit its blood flow and neural responses—further limiting its protective functions.

The sigmoid colon receives its arterial supply and venous drainage from the branches of the inferior mesenteric vessels which descend by way of the sigmoid mesocolon. Its sympathetic innervation is via the inferior mesenteric plexus whereas parasympathetic supply comes from the inferior mesenteric plexus and the sacral splanchnic nerves which also reach it via the mesocolon [1]. The long course of the nerves and blood vessels traveling in the mesocolon reaching

high in the abdomen means a high likelihood of strangulation and twisting of the loop. If these obstructive disorders occur, they can lead to even severer consequences such as volvulus, intussusceptions and strangulation [5, 7, 8].

The present case exhibited megacolic features of an enlarged lumen which was devoid of blood vessels and an excessively long mesocolon. It was also associated with a long and tortuous vermiform appendix. Whether these vermiform appendicular variations were a result of the sigmoid redundancy remains to be established. The absence of typical colonic wall features such as haustrations, taenia coli and appendices epiploicae entails a reduction of the functioning of the loop. A large lumen and poor vascular supply are further likely to cause problems of fecal material transit and consequently leading to various pathologies such as fecal impaction, chronic constipation, bacterial growth, diverticulosis, necrosis and wall perforations [7].

Conclusion

Reports of extreme variations in structure and location of the abdominal viscera are of radiological and surgical significances. Gastroenterologists need to have in mind these rare but important variations of the sigmoid colon and other intestinal viscera for surgical procedures involving the abdomen. More reports are needed in order to guide the successful diagnosis and management of abdominal conditions with variant anatomy.

Acknowledgement

I am indebted to Hamis Rajabu, Ismail Mkecha and Adamu Botea, mortuary technicians in the Department of Anatomy, Muhimbili University of Health and Allied Sciences, for the preparation and demonstration of the case. I am also indebted to the MUHAS first year medical students for the academic year 2012/2013 who reported the case for detailed studies.

References

- 11) Standring S, Jeremiah HC, Borley NR, Collins P, Wigley C, Johnson D, Shah P, eds. Gray's Anatomy. The Anatomical Basis of Clinical Practice. 39th Ed., Edinburgh, London, New York, Oxford, Philadelphia, St. Louis, Sydney, Toronto, Elsevier Churchill Livingstone. 2005; 1177–1186, 1197–1198.
- 12) Nayak SB, George BM, Mishra S. Abnormal length and position of the sigmoid colon and its clinical significance. *Kathmandu Univ Med J (KUMJ)*. 2012; 10: 94–97.
- 13) Southwell BR. Colon lengthening slows transit: is this the mechanism underlying redundant colon or slow transit constipation? *J Physiol*. 2010; 588: 3343.
- 14) Tan CK. Observations on some anomalies of the sigmoid colon. *Singapore Med J*. 1972; 13: 146–150.
- 15) Madiba TE, Haffajee MR, Sikhosana MH. Radiological anatomy of the sigmoid colon. *Surg Radiol Anat*. 2008; 30: 409–415.
- 16) Indrajit G, Sudeshna M, Subhra M. Redundant loop of descending colon and right-sided sigmoid colon. *Int J Anat Var (IJAV)*. 2012; 5: 11–13.
- 17) Safioleas M, Chatziconstantinou C, Felekouras E, Stamatakos M, Papaconstantinou I, Smirmis A, Safioleas P, Kostakis A. Clinical considerations and therapeutic strategy for sigmoid volvulus in the elderly: a study of 33 cases. *World J Gastroenterol*. 2007; 13: 921–924.
- 18) Alatise OI, Ojo O, Nwoha P, Omoniyi-Esan G, Omonisi A. The role of the anatomy of the sigmoid colon in developing sigmoid volvulus: a cross-sectional study. *Surg Radiol Anat*. 2013; 35:249–257.