



Case Report

“Pozzi”

Published online May 6th, 2011 © <http://www.ijav.org>

Tintu Thottiyil SUKUMARAN †
Asha Joselet MATHEW

Department of Anatomy, Amrita School of Medicine, Amrita Institute of Medical Science and Research Centre, Kerala, INDIA.



† Ms. Tintu Thottiyil Sukumaran, MSc
Lecturer
Department of Anatomy
Amrita School of Medicine
Amrita Institute of Medical Science and
Research Centre
AIMS Ponekkara P.O., Kochi 682041, Kerala, INDIA.
☎ +91 495 2261556
✉ tintu112233@gmail.com

Received July 20th, 2010; accepted March 1st, 2011

ABSTRACT

In a routine dissection, conducted in the Department of Anatomy, Amrita School of Medicine, Kochi, a well-developed small muscle was seen bilaterally, arising from the dorsal surface of wrist joint capsule overlying the carpus and deep to extensor retinaculum. © IJAV. 2011; 4: 93-94.

Key words [aberrant muscle] [extensor digitorum brevis manus] [ganglion]

Introduction

The dorsum of the hand is normally devoid of muscles and is crossed by the long extensor tendons placed in six fibro-osseous canals. However, some variant muscles have been documented. The clinical anatomy and morphology of a variant known as the extensor digitorum brevis manus (EDBM) was discussed in this study.

Case Report

During routine dissection for the first year medical students at the Amrita School of Medicine a small muscle belly was detected on the dorsum of the hand of a 65-year-old male cadaver, bilaterally. It was identified as the EDBM (Figures 1,2). It was originated from the wrist joint capsule and dorsum of the carpal bones. It was inserted into the extensor expansion hood of the middle finger deep to the extensor tendons. Its innervation and blood supply were confirmed to be the posterior interosseous nerve and anterior interosseous artery (Figure 3).

Discussion

The extensor digitorum brevis manus was first described by Albinus in 1734 [1]. Samuel Pozzi, French anatomist described it in detail and it is called Pozzi or Pozzi's muscle

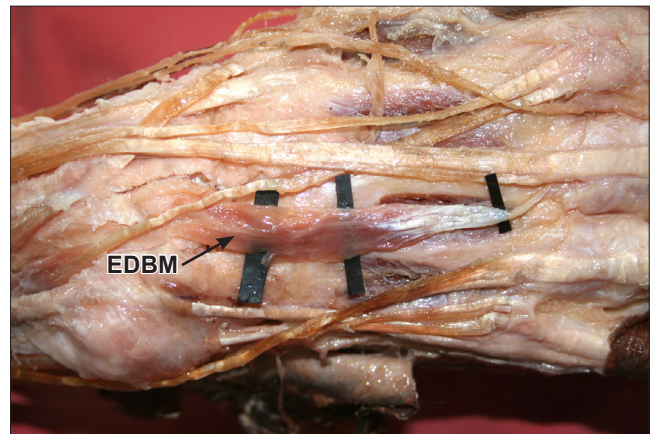


Figure 1. Photograph of extensor digitorum brevis manus muscle originated from the right wrist joint capsule and dorsum of the carpal bones. (EDBM: extensor digitorum brevis manus muscle)

[2]. In comparative anatomical studies the amphibian digits are controlled exclusively by this muscle [3].

Similar muscle was described by Parthasarathy and he was of the view that it had undergone long segmentation and delamination from the extensor digitorum [4].

* Presented at the 54th National Conference of the Anatomical Society of India, Kochi, Kerala State, India (2006).

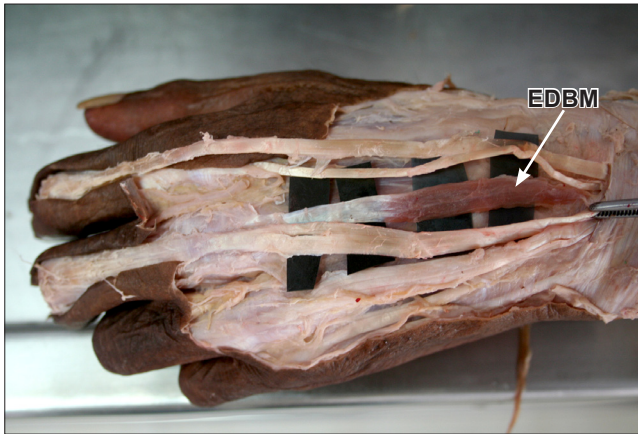

Figure 2. Photograph of extensor digitorum brevis manus muscle originated from the left wrist joint capsule and dorsum of the carpal bones. (*EDBM: extensor digitorum brevis manus muscle*)

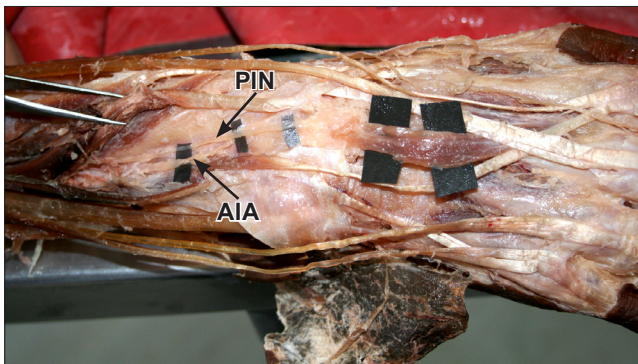


Figure 3. Photograph showing blood supply and innervation of extensor digitorum brevis manus muscle. (*PIN: posterior interosseous nerve; AIA: anterior interosseous artery*)

Depending on its insertion to the index, middle or ring fingers it has been documented as extensor indicis brevis [5], extensor medii brevis [6] and extensor anularis brevis or a combination of any two [7].

An unusual variation was described by Paraskevas et al. wherein the EDBM was found at the dorsum of the hand arising from the wrist capsule beneath the extensor retinaculum and inserted in to the ulnar side of the base of

the proximal phalanx of the index finger but superficial to the extensor tendons of the fingers [8].

Rodriguez et al. described an EDBM. In their case report the muscle was supplied by the posterior interosseous nerve and artery. They further stated that it could be mistaken for a ganglion, soft tissue tumour, cyst or nodule [1].

The presence of such an aberrant muscle may present as pain after repetitive activity [9]. The pain is because of compression of the nerve and artery along with hypertrophy of the muscle.

Conclusion

Although the presence of this variant may be asymptomatic in most cases, it is necessary for surgeons to be aware of variations of extensor muscles so that it may be included in the differential diagnosis of soft tissue mass on the dorsum of the hand. This is particularly significant in the “age of the computer manus” as repetitive activity on the keyboard may present with symptoms. EMG studies and MRI scans can confirm preoperative diagnosis and avoid unnecessary intervention and complications thereof. Its presence can also be taken advantage of in microsurgical procedures such as tendon transfers and reconstructive surgery.

Acknowledgements

We are extremely thankful to Dr. K. K. Krishnamma, Professor of Anatomy for her guidance.

References

- [1] Rodriguez-Niedenfuhr M, Vazquez T, Golano P, Parkin I, Sanudo JR. Extensor digitorum brevis manus: Anatomical, radiological and clinical relevance. A review. *Clin Anat.* 2002; 15: 286–292.
- [2] Illustrated Stedman's Medical Dictionary. 24th Ed., Baltimore/ London, Williams & Wilkins. 1982, reprint – 1984; 902.
- [3] Tan ST, Smith PJ. Anomalous extensor muscles of the hand: a review. *J Hand Surg Am.* 1999; 24: 449–455.
- [4] Parthasarathy MS. Another accessory extensor muscle in the hand. *J Anat Soc India.* 1953; 2: 38–39.
- [5] el-Badawi MC, Butt MM, al-Zuhair AC, Fadel RA. Extensor tendons of the fingers: arrangement and variations – II. *Clin. Anat.* 1995; 8: 381–388.
- [6] Kadanoff D. Über die Erscheinungen des Umladungsprozesses der Finger- und Zehenstrecker beim Menschen. *Gegenbaur's Morphol Jahrb.* 1958; 99: 613–661. (German)
- [7] Fernandez Vazquez JM, Linscheid RL. Anomalous extensor muscles simulating dorsal wrist ganglion. *Clin Orthop Relat Res.* 1972; 83: 84–86.
- [8] Paraskevas G, Papazilogas B, Spanidou S, Papadopoulos A. Unusual variation of the extensor digitorum brevis manus: A case report. *Eur J Orthop Surg Traumatol.* 2002; 12: 158–160.
- [9] Fakih RR, Thomas R, Mansour A. The extensor digitorum brevis manus. A case report. *Bull Hosp Jt Dis.* 1997; 56: 115–116.