

# Neonatal lupus presenting with abnormal intrapartum fetal heart rate patterns: A case report

Junsuke Muraoka<sup>1,2</sup>, Yuki Kodama<sup>1\*</sup>, Tomoko Yamaguchi<sup>2</sup>, Hajime Taniguchi<sup>2</sup>, Nozomi Shiiba<sup>1</sup>, Emi Kino<sup>1</sup>, Rie Yamashita<sup>1</sup>, Kaori Michikata<sup>1</sup>, Masatoki Kaneko<sup>1</sup>, Hiroshi Sameshima<sup>1</sup>

Muraoka J, Kodama Y, Yamaguchi T, et al. Neonatal lupus presenting with abnormal intrapartum fetal heart rate patterns: A case report. *J Pediatr Health Care Med.* 2019;2(1):27-28.

We report a case of neonatal lupus erythematosus (NLE) that presented with systemic cutaneous lesions and thrombocytopenia at birth. A female neonate weighing 1909 g was delivered by cesarean section due to non-reassuring fetal status at 35 weeks of gestation, with recurrent late decelerations and decreased baseline variability. Umbilical arterial pH level was 7.27. The

infant exhibited no signs of arrhythmia. Frequent platelet transfusions and intravenous immunoglobulin administration were required. The mother was revealed to be positive for anti-Ro/SSA and anti-La/SSB antibodies, indicating Sjögren's syndrome. Future pregnancies should be monitored for NLE. This is the first case of NLE presenting with abnormal intrapartum fetal heart rate patterns.

**Key Words:** Neonatal lupus erythematosus; Fetal heart rate monitoring

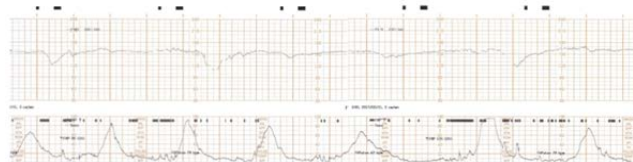
## INTRODUCTION

Neonatal lupus erythematosus (NLE) is an uncommon but serious disease caused by maternal antibodies [1,2]. Antibodies that cross the placenta to the fetus can cause various clinical manifestations, including cardiac, cutaneous, hepatic, and hematological lesions, such as hepatitis and cytopenias [1,2]. One strategy for the prevention of cardiac lesions is administration of steroids when the mother is known to have causative autoantibodies [3]. However, mothers pregnant with infants with NLE are sometimes asymptomatic [4], and physicians do not know that the mother has such autoantibodies. In this report, we describe a case of NLE that presented with widespread cutaneous eruptions and thrombocytopenia at birth, following abnormal fetal heart rate (FHR) patterns on monitoring during delivery. Informed consent for publication of this case report was obtained from the infant's parents.

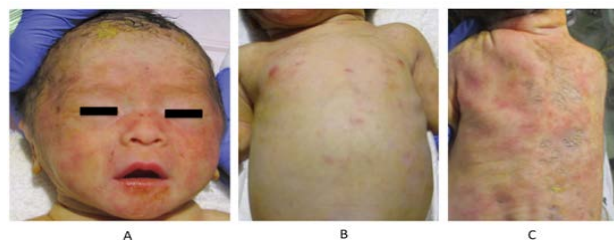
## CASE REPORT

A 31-year-old Japanese woman (gravida 3, para 2) who had an uneventful antenatal course was referred to our hospital due to preterm labor at 35 weeks and 3 days of gestation. Her two sons from the previous pregnancies were normal. She was suspected of having systemic lupus erythematosus at the age of 29 years because of a "butterfly" erythematous rash on the face and positive antinuclear antibody test. However, the diagnosis was not confirmed. On the day of referral, FHR monitoring showed recurrent late decelerations with decreased baseline variability (Figure 1). An urgent cesarean section was performed and a female neonate weighing 1,909 g was delivered with an Apgar score of 5 at 1 minute and 8 at 5 minutes. Blood gases of umbilical cord blood showed a pH 7.27, pO<sub>2</sub> 14.5 mmHg, pCO<sub>2</sub> 56.2 mmHg, and base excess -0.9 mmol/L. There was no retroplacental hematoma. The patient was admitted to the neonatal intensive care unit. The cutaneous lesions including erythematous, purplish, atrophic patches were distributed over the face, abdomen, back, trunk, extremities, and bilateral inguinal regions (Figure 2). Cardiac arrhythmias were not detected. Blood tests showed: white blood cell 5,010 per mm<sup>3</sup> (stab. 18.5%); hemoglobin 10.5 g/dL; platelet count 8,000 per mm<sup>3</sup>; aspartate transaminase, 261 U/L; alanine transaminase, 47 U/L; lactate dehydrogenase, 3,046 U/L; and C-reactive protein, 2.29 mg/dL. The mother's blood and umbilical cord blood were positive for anti-Ro/SSA and anti-La/SSB antibodies.

Cardiac ultrasonography revealed a small pericardial effusion and left ventricular ejection fraction of 65%. Dopamine (5 µg/kg/min) was given to stabilize the circulation. Ampicillin (400 mg/kg/day), amikacin (10 mg/kg/day), cefotaxime (100 mg/kg/day), and gamma globulins (100 mg/kg/



**Figure 1)** Findings from fetal heart rate monitoring on the day of referral. This pattern lasted for at least 2 hours until delivery.



**Figure 2)** Cutaneous lesions of the newborn at birth. Erythematous, purplish, atrophic patches were distributed over her face (A), abdomen (B), and back (C).

day) were also administered for 5 days on suspicion of microbial infection. Cultures from the oral cavity, skin, stool, and venous blood were negative. Tests for antibodies to cytomegalovirus, parvovirus B19, toxoplasma, fungi, and *Treponema pallidum* were also negative.

We applied moisturizer to her body and avoided cutaneous exposure to sunlight out of concern for worsening the lesions. The eruptions spontaneously regressed. Repeated platelet transfusions were needed. Intravenous immunoglobulin administration (1 g/kg) gradually resolved the thrombocytopenia. Thereafter, during the first 6 weeks, she needed platelet transfusions twice, erythrocyte transfusion, and another immunoglobulin administration (Figure 3). Results of lip biopsy from the mother were consistent with Sjögren's syndrome.

## DISCUSSION

NLE is an uncommon disease caused by the transplacental passage of maternal

<sup>1</sup>Faculty of Medicine, Department of Obstetrics and Gynecology, University of Miyazaki, Japan.

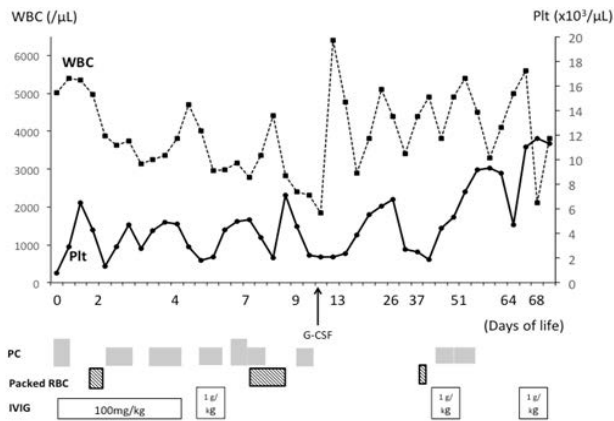
<sup>2</sup>Department of Obstetrics and Gynecology, Miyazaki Prefectural Nichinan Hospital, Japan

**Correspondence:** Dr Kodama Y, Department of Obstetrics and Gynecology, University of Miyazaki, 5200 Kihara, Kiyotake-cho, Miyazaki 889-1692, Japan, Tel: +81-985-85-0988; E-mail yuki\_kodama@med.miyazaki-u.ac.jp

Received: February 11, 2019, Accepted: March 06, 2019, Published: March 13, 2019



This open-access article is distributed under the terms of the Creative Commons Attribution Non-Commercial License (CC BY-NC) (<http://creativecommons.org/licenses/by-nc/4.0/>), which permits reuse, distribution and reproduction of the article, provided that the original work is properly cited and the reuse is restricted to noncommercial purposes. For commercial reuse, contact [reprints@pulsus.com](mailto:reprints@pulsus.com)



**Figure 3)** Trends in white blood cell and platelet counts. Transfusions of packed red blood cells and platelets, as well as immunoglobulin administration are shown. WBC: White Blood Cell; Plt: Platelet; IVIG: Intravenous Immunoglobulin; G-CSF: Granulocyte Colony Stimulating Factor.

autoantibodies into the fetal circulation [1,2]. Though the true prevalence of NLE is not clear, it is approximately 1: 20,000 live births [5]. Manifestations are detected when congenital heart block or fetal hydrops develop during pregnancy. Other manifestations, such as cutaneous lesions or hematological or hepatic abnormalities are not found until birth. Congenital heart block can result in a poor prognosis [6], whereas non-cardiac manifestations are transient [7].

According to previous reports [2,7] cutaneous NLE is likely to appear in the first weeks of life and improve spontaneously within several months, as a consequence of the disappearance of maternal antibodies from the neonatal circulation. When obstetricians encounter these characteristic skin eruptions in neonates, cutaneous NLE should be a differential diagnosis. Skin biopsy is helpful when the diagnosis is in doubt, but it is not needed to confirm the diagnosis.

Thrombocytopenia has been noted in several cases of NLE, which often resolves spontaneously [7]. However, in our case, the serious thrombocytopenia recurred during the neonatal period, despite repetitive platelet transfusions. After administering immunoglobulin, the platelet count gradually increased to more than 20,000/mm<sup>3</sup>. Although no consensus has been reached on the efficacy of intravenous immunoglobulin therapy in infants with NLE, we speculate that immunoglobulin therapy might have some beneficial effects.

The FHR patterns in this case showed recurrent late decelerations with decreased baseline variability, which was present for at least 2 h. However, the umbilical arterial blood gas analysis showed almost normal values. This discrepancy between abnormal FHR patterns and normal umbilical arterial pH may have been caused by several factors. For example, maternal antibodies may affect the fetal cardiac conduction system, resulting in late deceleration and decreased variability. The antibodies also may affect sympathetic-parasympathetic reflex circuits. Some relative hypoxia might also have occurred associated with the fetal pericardial effusion [8]. The current understanding that links autoantibodies to fetal heart damage is most abundant in the mid-trimester of pregnancy, infrequent in the third trimester, and less amenable to the regenerative process. One thing is that the patient had not been performed FHR tracing before, which we could

not have detected non reassuring patterns. Second, as the gestational age progressed, the autoantibodies might have affected the placenta.

According to a follow-up survey [4], asymptomatic mothers of children with NLE have a substantial risk of developing overt autoimmune disease. In another report, 65% (13 of 20) of mothers who had delivered infants with cutaneous NLE gave birth to NLE newborns in their subsequent pregnancies [9]. The mother in our case was diagnosed with asymptomatic Sjögren's syndrome after delivery. This might progress in the future, and infants from subsequent pregnancies are also at risk of NLE. Careful follow-up as well as pregestational counseling is essential.

In summary, we report a case of NLE that presented with non-reassuring intrapartum FHR patterns, and widespread cutaneous eruptions and severe thrombocytopenia at birth. Maternal surveillance for collagen diseases and intensive neonatal therapy, including repetitive blood transfusions, were needed.

#### ACKNOWLEDGEMENTS

The authors are grateful to the Drs. Nishimura, Ishiai and Kashima for their clinical assistance. This study was supported by a Grant for Clinical Research from Miyazaki University Hospital (2018).

#### CONFLICT OF INTEREST

There are no conflicts of interest to disclose from all authors.

#### REFERENCES

1. McCuiston C, Schoch EP Jr. Possible discoid lupus erythematosus in newborn infant; report of a case with subsequent development of acute systemic lupus erythematosus in mother. *Arch Dermatol.* 1954;70:782-5.
2. Cimaz R, Spence DL, Hornberger L, et al. Incidence and spectrum of neonatal lupus erythematosus: a prospective study of infants born to mothers with anti-Ro autoantibodies. *J Pediatr.* 2003;142:678-3.
3. Shinohara K, Miyagawa S, Kidoguchi K, et al. Neonatal lupus erythematosus: Results of maternal corticosteroid therapy. *Obstet Gynecol.* 1999;93:952-7.
4. Rivera TL, Izmirly PM, Buyon JP, et al. Disease progression in mothers of children enrolled in the Research Registry for Neonatal Lupus. *Ann Rheum Dis.* 2009;68:828-5.
5. Wisuthsarewong W, Soongswang J, Chantorn R. Neonatal lupus erythematosus: Clinical character, investigation, and outcome. *Pediatr Dermatol.* 2011;28:115-21.
6. Hornberger LK, Al Rajaa N. Spectrum of cardiac involvement in neonatal lupus. *Scand J Immunol.* 2010;72:189-97.
7. Boh EE. Neonatal lupus erythematosus. *Cli Dermatol.* 2004;22:125-8.
8. Sameshima H, Ikenoue T, Ibara S, et al. Association of non-reassuring fetal heart rate patterns and subsequent cerebral palsy in infants exposed to intrauterine infection. *Am J Perinatol.* 2005;22:181-7.
9. Neiman AR, Lee LA, Buyon JP, et al. Cutaneous manifestations of neonatal lupus without heart block: characteristics of mothers and children enrolled in a neonatal registry. *J Pediatr.* 2000;137:674-80.