



Multiple variations of the subhepatic hepatobiliary vasculature

Published online March 3rd, 2010 © <http://www.ijav.org>

Bincy M. GEORGE
Somayaji SN ⁺

Melaka Manipal Medical College (Manipal Campus), International Centre for Health Sciences, Manipal, INDIA.



⁺ Somayaji S N
Professor of Anatomy
Melaka Manipal Medical College (Manipal Campus)
International Centre for Health Sciences
Madhav Nagar, Manipal
Udupi District, Karnataka State, 576104, INDIA.
☎ +91 820 2922519
✉ snsomayaji@yahoo.com

Received July 31st, 2009; accepted February 10th, 2010

ABSTRACT

Proper knowledge of the anatomy of hepatobiliary vasculature and its possible variations are important for surgeons, radiologists and other clinicians. We noticed few variations in the branching pattern of hepatic artery, portal vein and cystic artery during routine anatomy dissection classes. The variations include an additional left hepatic artery, which was found communicating with left branch of portal vein, and an additional cystic artery.
© IJAV. 2010; 3: 39–40.

Key words [accessory left hepatic artery] [patent ligamentum venosum] [extrahepatic biliary system] [hepatobiliary vasculature] [multiple variations]

Introduction

Extrahepatic part of portal vein ascends within the right free margin of lesser omentum in front of epiploic foramen, and reaches the porta hepatis where it divides into right and left branches. The left branch is longer and more oblique and is connected with round ligament of the liver from below and ligamentum venosum from above.

In front of epiploic foramen, the extrahepatic part of portal vein is accompanied by hepatic artery proper and bile duct. Close to the porta hepatis, the hepatic artery proper divides into right and left branches which supply respectively the physiological right and left lobes of the liver. The right hepatic artery gives origin to one cystic artery to supply the gallbladder.

Case Report

During the regular demonstration classes for undergraduate medical students, we encountered a liver with few subhepatic vascular variations in a 53-year-old male cadaver. We saw an accessory left hepatic artery arising from hepatic artery proper, which was branching and supplying the left hepatic lobe. One among these branches found to be joined to the left branch of portal vein along the fissure for ligamentum venosum. There were 2 cystic arteries; both arose from hepatic artery proper just after the former gave rise to the accessory left hepatic artery. The hepatic artery proper was dividing into right and left hepatic artery near the right end of

porta hepatis. The lumen of ligamentum venosum was found patent (Figure 1).

Discussion

Branching pattern and distribution of the common hepatic artery found varied in many cases. Accessory left hepatic artery arising from left gastric artery, common hepatic artery or gastroduodenal artery, and origin of accessory right hepatic artery from superior mesenteric artery or gastroduodenal artery were reported [1–3].

The ductus venosus is a bypass between the umbilical vein and inferior vena cava in fetal circulation. Functional closure of ductus venosus occurs in 93% of infants at 2 weeks of age, followed by anatomic closure. The ductus venosus rarely opens in patients with portal hypertension. There are few reported cases of patent ductus venosus in adults. The reason why the asymptomatic patent ductus venosus of childhood persists as symptomatic patent ductus venosus in adults is not known. The hepatoportal arteriovenous shunt could result indirect blood flow between hepatic artery and portal vein, which may cause portal hypertension and consequently splenomegaly, ascites and esophageal varices, accelerating intrahepatic dissemination and extrahepatic metastasis of carcinoma cells [4–7].

The cystic artery is also known for its variations. It can arise from middle hepatic artery, the gastroduodenal artery, or the left hepatic artery. Accessory cystic arteries can arise from right hepatic, middle hepatic or the left

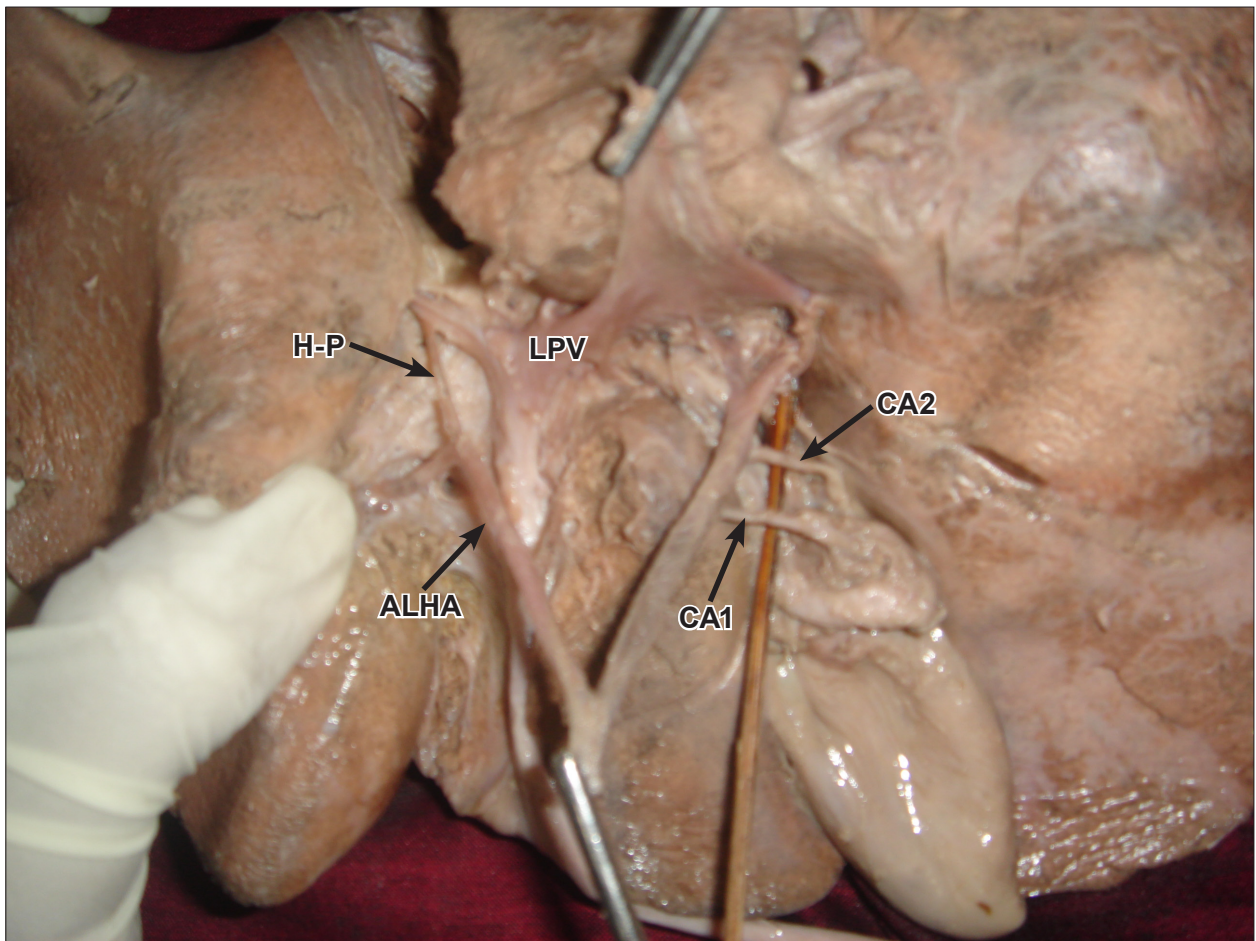


Figure 1. Subhepatic view of the case. (*H-P*: hepato-portal arteriovenous anastomoses; *LPV*: left branch of portal vein; *ALHA*: accessory left hepatic artery; *CA1*: first cystic artery; *CA2*: second cystic artery)

hepatic arteries. But it is most often a single vessel. There is a 2-15% incidence of double cystic artery. Ligation of both these cystic arteries may become necessary during cholecystectomy, for the treatment of gallbladder stones, inflammation, edema, adhesions and fibrosis [8-10].

The literature suggests that these variations can be explained in terms of developmental basis [3]. During development, the extrahepatic biliary system arises from an intestinal diverticulum, which carries blood

supply from branches of aorta, celiac trunk and superior mesenteric arteries. As the development progresses, most of these vessels are disappeared and the pattern of the disappearance is highly variable. This explains the reason for the subhepatic variations. The surgeon and interventional radiologists need to be aware of the possibility for such anatomical variations in order to avoid potentially disastrous complications.

References

- [1] Loukas M, Ferguson A, Louis RG Jr, Colborn GL. Multiple variations of the hepatobiliary vasculature including double cystic arteries, accessory left hepatic artery and hepatosplenic trunk: a case report. *Surg Radiol Anat.* 2006; 28: 525-528.
- [2] Futara G, Ali A, Kinfu Y. Variations of the hepatic and cystic arteries among Ethiopians. *Ethiop Med J.* 2001; 38: 133-142.
- [3] Tharao MK, Saidi H, Kitunguu P, Julius OA. Variant anatomy of the hepatic artery in adult Kenyans. *Eur J Anat.* 2007; 11: 155-181.
- [4] Alzevi N, Kokoua A, Yangni-Angate H, Kassanyou S, Agossou-Voyeme AK, Santos KA, Ouattara D, N'Guessan G. Portal vein: variations of its branches (about 32 dissections). *Morphologie.* 2005; 89: 76-81. (French)
- [5] Macchi V, Porzionato A, Tiengo C, Parenti A, De Caro R. Persistence of embryonic pattern of hepatocaval venous junction and patent ductus venosus in Budd-Chiari syndrome. *Clin Anat.* 2006; 19: 673-677.
- [6] Uchino T, Endo F, Ikeda S, Shiraki K, Sera Y, Matsuda I. Three brothers with progressive hepatic dysfunction and severe hepatic steatosis due to a patent ductus venosus. *Gastroenterology.* 1996; 110: 1964-1968.
- [7] Luo MY, Shan H, Jiang ZB, Li LF, Huang HQ. Study on hepatocellular carcinoma-associated hepatic arteriovenous shunt using multidetector CT. *World J Gastroenterol.* 2003; 9: 2455-2459.
- [8] Mlaker B, Gadzijev EM, Ravnik D, Hribernik M. Anatomical variations of the cystic artery. *Eur J Morphol.* 2003; 41: 1: 31-34.
- [9] Sarkar AK, Roy TS. Anatomy of the cystic artery arising from the gastroduodenal artery and its choledochal branch - a case report. *J Anat.* 2000; 197: 503-506.
- [10] Flisinski P, Szpinda M, Flisinski M. The cystic artery in human fetuses. *Folia Morphol (Warsz).* 2004; 63: 47-50.