



Multiple variations in neck musculature and their surgical implications

Published online October 6th, 2011 © <http://www.ijav.org>

Avinash THAKUR †

Bertha A

Suresh K PARMAR

Department of Anatomy, Christian Medical College, Vellore, INDIA.



† Dr. Avinash Thakur
Department of Anatomy
Christian Medical College
Vellore 632 002, INDIA.
☎ +91 416 2284245
✉ thakurevns@gmail.com

Received March 9th, 2011; accepted September 26th, 2011

ABSTRACT

Muscular variations in the region of head and neck are not uncommon but when present are extremely significant not only for the anatomists but also for the clinicians and the surgeons because they can hinder the diagnosis and treatment of various disorders, and also can cause a few rare diseases. We report here a case of multiple muscular variations in the neck of a 58-year-old male cadaver, involving the omohyoid, sternocleidomastoid and the digastric muscles. On the left side, both the bellies of omohyoid were originating from the clavicle with the absence of an intermediate tendon. The left sternocleidomastoid had three heads of origin, one sternal and two clavicular. There was bilateral duplication of the anterior belly of digastric muscle. The clinical implications of these anatomical variations are discussed in detail. © IJAV. 2011; 4: 171–173.

Key words [omohyoid] [sternocleidomastoid] [digastric] [cleidohyoideus] [pseudodysphagia]

Introduction

The omohyoid consists of two fleshy bellies united at an angle deep to the sternocleidomastoid by an intermediate tendon. The inferior belly originates just lateral to the suprascapular notch and partly from the transverse scapular ligament and ends in the intermediate tendon. The superior belly passes almost vertically upwards lateral to the sternohyoid and inserts on the lateral part of the lower border of the hyoid bone. Intermediate tendon that varies in length and composition usually lies deep to sternocleidomastoid, adjacent to internal jugular vein, opposite the arch of cricoid cartilage. It is held by a band of deep cervical fascia which is attached to the clavicle and the first rib below. The angular form of the omohyoid muscle is maintained by this fascial sling. There have been several reports of variations in the omohyoid: the superior belly being attached to the transverse process of the C6, double omohyoids, absence of superior belly and absence of inferior belly where the superior belly is attached to the clavicle [1]. It is important for the clinicians to be aware of these variants because of the close relation of omohyoid to important neurovascular structures in the neck.

The sternocleidomastoid arises from two heads. A tendinous sternal head from the anterolateral part of manubrium sterni and a musculotendinous clavicular head from the medial one third of the clavicle. Both the heads fuse in the middle of the

neck and insert on the lateral surface of the mastoid process and the lateral one third of the superior nuchal line. This muscle is a prominent landmark in the neck region especially when contracted. Spasm of the sternocleidomastoid muscle, usually of unknown origin but sometimes congenital, is one cause of a flexion deformity of the neck known as wryneck or torticollis; other muscles that rotate and flex the neck also may contribute to torticollis.

Case Report

Routine dissection of the triangles of the neck was performed on a 58-year-old male cadaver in the Anatomy Department of Christian Medical College Vellore for undergraduate teaching. There were no signs of trauma or any surgical scars in the neck region. Rare variations in the musculature of the neck region were observed. The superior belly of omohyoid was originating from the posterior surface of medial two thirds of the clavicle and was in continuation with the insertion of the inferior belly on the clavicle. This origin was ensheathed by the deep cervical fascia and was adherent to the wall of the internal jugular vein. The origin of the inferior belly and the insertion of the superior belly were as usual. The superior belly was fused with the sternohyoid. The superior belly was thus considered to be cleidohyoideous [2] with the above mentioned variations (Figure 1). Intermediate tendon was absent. The superior

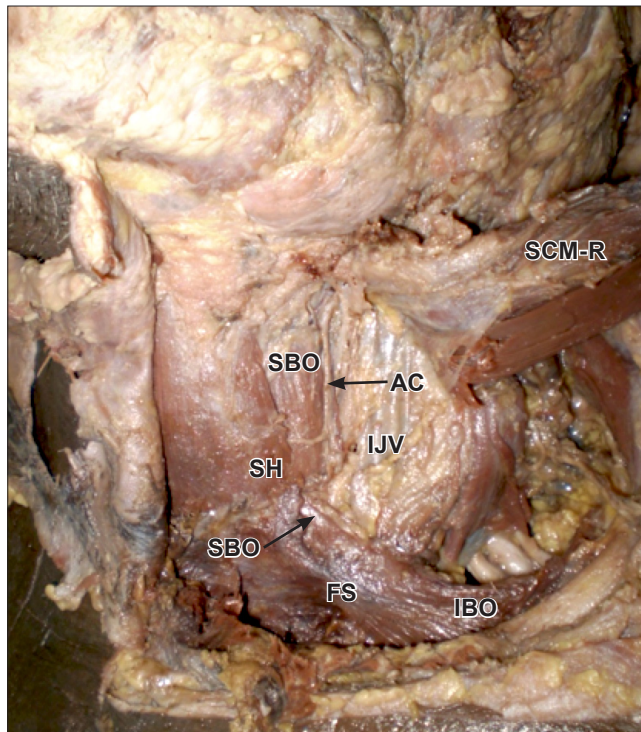


Figure 1. Muscular variation of omohyoid. (*SBO*: superior belly of omohyoid; *IBO*: inferior belly of omohyoid; *FS*: fascial sheath of deep cervical fascia; *IJV*: internal jugular vein; *AC*: ansa cervicalis; *SCM-R*: sternocleidomastoid-reflected head; *SH*: sternohyoid)

belly was supplied by descendens hypoglossi and the inferior belly by the loop of the ansa cervicalis. The arterial supply showed no variation.

An additional tendinous head of origin was observed in the left sternocleidomastoid attached to the medial most part of the clavicle between the sternal head and the clavicular head (Figure 2). This additional slip was present in the lesser supraclavicular fossa superficial to the neurovascular structures dividing it into two fossae, which were named as medial and lateral lesser supraclavicular fossae. This slip fused with the deep surface of the sternal head in the middle of the neck. It was supplied by a branch from the spinal accessory nerve. The sternal head was tendinous in origin and the clavicular head was muscular. The musculature on the right side of the neck was as usual.

The anterior belly of digastric muscles bilaterally showed duplication (Figure 3). There was a tendinous slip extending from the lesser horn of hyoid bone, which spread into a muscular attachment into the superior part of the body of hyoid bone.

Discussion

Multiple muscular variations in the head and neck region are extremely rare. These variations can have a wide variety of clinical implications. Omohyoid is related to important neurovascular structures in the neck and hence its variation

can cause variable disorders. In this case the fascial sheath covering the omohyoid was fused with the internal jugular vein and this could cause variation in the size of the lumen of the vein and hence hindering the venous return from the head and neck region. Exact etiology of pseudodysphagia (omohyoid muscle syndrome) is not known yet but absence of intermediate tendon and muscular origin of the superior belly of omohyoid from the clavicle can be the cause [3]. Studies of muscle spindles in the infrahyoid muscles has shown omohyoid to have the maximum number which can be the possible embryogenetic cause behind such great number of its variations. These wide varieties of omohyoid also have clinical implications in the management of oral and oropharyngeal carcinomas. Surgeons should have a thorough knowledge of these variations especially for flap reconstruction in the neck region. Omohyoid can be used in prevention of chyle fistula [4], to decrease the aspiration rate of previously reported simple mucodermal tracheo-esophageal fistula [5], in horizontal myocutaneous infrahyoid flaps with superior thyroid artery as the vascular pedicle [6], for defect restoration after intra-oral cancer surgeries [7], in transposition for treatment of bowed vocal cords [8], for restoration of inspiratory vocal cords for abduction using phrenic-omohyoid transfer [9], and in reconstruction for anterior commissure cancer using bilateral omohyoid flap [10].

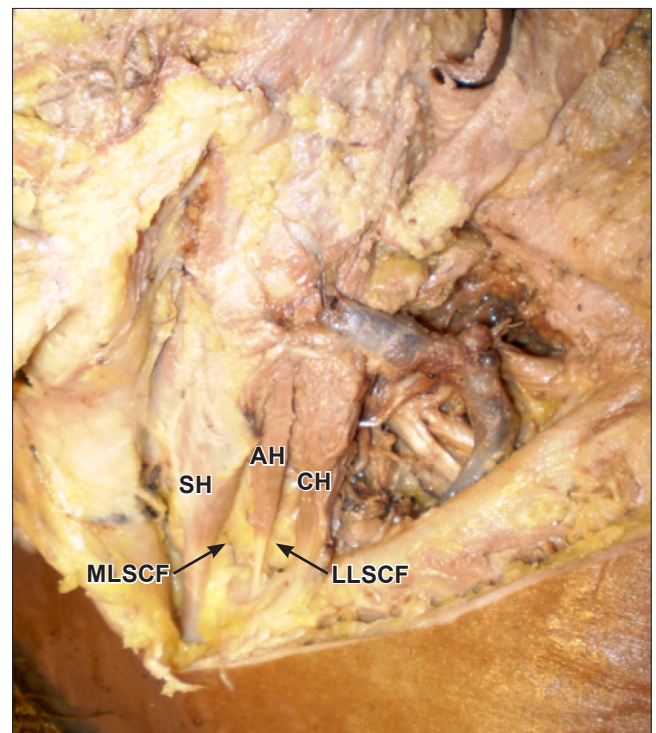


Figure 2. Additional head of sternocleidomastoid. (*SH*: sternal head; *CH*: clavicular head; *AH*: additional head; *MLSCF*: medial lesser supraclavicular fossa; *LLSCF*: lateral lesser supraclavicular fossa)

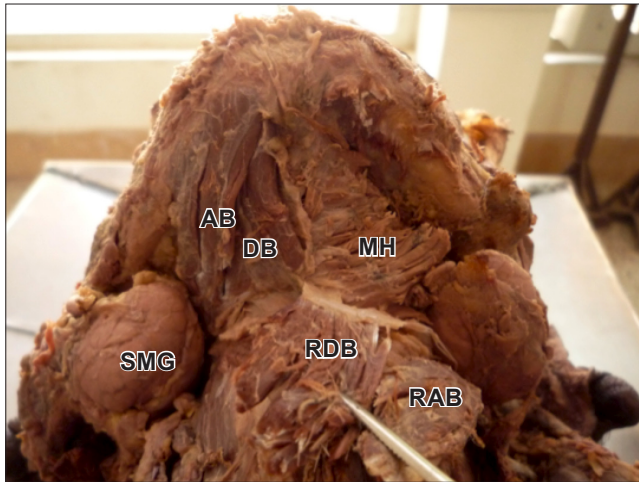


Figure 3. Bilateral duplicated anterior bellies of digastric muscle. (*AB*: anterior belly of digastric muscle; *DB*: duplicated anterior belly of digastric muscle; *SMG*: submandibular gland; *RDB*: reflected left duplicated belly of digastric muscle; *RAB*: reflected left anterior belly of digastric muscle; *MH*: mylohyoid)

Sternocleidomastoid can have additional slips of origin but usually arising lateral to the clavicular head. Rarely the sternocleidomastoid can be fused with the trapezius because of their common development from the post-sixth branchial arch, which is considered normal by some authors. These variations are probably due to the development of the muscle by several myotomes. Thorough knowledge of variations of sternocleidomastoid is necessary for harvesting the muscle flap. In the case of deformities related to some causes of cancer and trauma, sternocleidomastoid muscle is often used as muscle and myocutaneous flap in the treatment of oral cavity and facial deficits. It can also be used as a

gator neck flap in neck dissections [11], as perforator flap [12], for primary repair of trachea-esophageal fistulas [13], for facial nerve reconstruction using sural nerve and sternocleidomastoid flap [14], to seal off esophageal leakage following free jejunal flap reconstruction [15], and lip augmentation [16]. Additional head of sternocleidomastoid in the region of the lesser supraclavicular fossa can lead to compression and cause severe damage to the underlying neurovascular structures. These additional slips of sternocleidomastoid can cause severe clinical symptoms like sternomastoid pseudotumors and congenital torticollis, and should be studied in detail for their prompt management [17].

Variations of the bellies of digastric have been reported in the literature. Ozgur et al., have discussed the aberrant and quadrification of anterior belly of digastric muscles. The anterior belly of digastric muscle is removed in platysmarrhaphy and cosmetic surgeries. Supernumerary and accessory bellies should be looked for and removed by the surgeons for best desired effect in these procedures. Digastric muscle transplant is used for corrective surgeries for lower lip asymmetry and harvested in pedicled submental flap. Accessory muscle slips can provide supplementary tissue to work with in these cases. Accessory muscle slips, especially in the cervical region can be mistaken for enlarged lymph nodes, lead to confusion in some pathological diagnosis, radiological examination and aesthetic facial surgery. They may cause pharyngeal pain and foreign body sensation in the throat. These extra slips give a variant mobility to the hyoid bone leading to symptoms similar to stylohyoid syndrome [18]. Digastric muscle sew-up procedure for the repair of the floor of the mouth following the pull through operation for advanced oral cancers has been found to be simple, safe and timesaving method for small to medium-sized defects of the floor of the mouth created by ablative surgery.

References

- [1] Tubbs RS, Salter EG, Oakes WJ. Unusual origin of the omohyoid muscle. *Clin Anat*. 2004;17: 578–582.
- [2] Bergman RA, Thomson SA, Afifi AK, Saadeh FA. *Compendium of Human Anatomic Variation*. Baltimore – Munich, Urban & Schwarzenberg. 1988; 85.
- [3] Kim L, Kwon H, Pyun SB. Pseudodysphagia due to omohyoid muscle syndrome. *Dysphagia*. 2009; 24: 357–361.
- [4] Zhengjiang L, Sabesan T, Pingzhang T, Ilankovan V. Omohyoid muscle flap in prevention of chyle fistula. *J Oral Maxillofac Surg*. 2007; 65: 1430–1432.
- [5] Saito H, Fujieda S, Ohtsubo T, Tsuda C, Saito T, Shibamori Y, Sunaga H. Tracheoesophageal shunt method with omohyoid muscle loop for voice restoration. *Arch Otolaryngol Head Neck Surg*. 2003; 129: 321–323.
- [6] Majoufre-Lefebvre C, Laurentjoye M, Faucher A, Zwetyenga N, Siberchicot F, Ricard AS. The horizontal infrahyoid myocutaneous flap: surgical technique. *Rev Stomatol Chir Maxillofac*. 2008; 109: 106–109. (French)
- [7] Li B, Li CH, Guo H, Chen J, Wang SX. Analysis of 27 cases of defect restoration using infrahyoid myocutaneous flap after intraoral cancer surgery. *Zhonghua Er Bi Yan Hou Tou Jing Wai Ke Za Zhi*. 2008; 43: 826–829.
- [8] Kojima H, Hirano S, Shoji K, Omori K, Honjo I. Omohyoid muscle transposition for the treatment of bowed vocal fold. *Ann Otol Rhinol Laryngol*. 1998; 105: 536–540.
- [9] Crumley RL. Muscle transfer for laryngeal paralysis. Restoration of inspiratory vocal cord abduction by phrenic-omohyoid transfer. *Arch Otolaryngol Head Neck Surg*. 1991; 117: 1113–1117.
- [10] Calcatera TC. Bilateral omohyoid muscle flap reconstruction for anterior commissure cancer. *Laryngoscope*. 1987; 97: 810–813.
- [11] Parell GJ, Cassisi NJ. The skin-sternocleidomastoid muscle composite flap for neck dissection (the gator neck flap). *Laryngoscope*. 2008; 118: 1791–1792.
- [12] Avery CME. The sternocleidomastoid perforator flap. *Br J Oral Maxillofac Surg*. 2011; 49: 573–575.
- [13] Okuyama H, Kubota A, Due T, Kuroda S, Nara K, Takahashi T. Primary repair of tracheoesophageal fistula secondary to disc battery ingestion: a case report. *J Pediatr Surg*. 2004; 39: 243–244.
- [14] Motomura H, Yamanaka K, Maruyama Y, Sakamoto M, Harada T. Facial nerve reconstruction using a muscle flap following resection of parotid gland tumours with thorough recipient bed preparation. *J Plast Reconstr Aesthet Surg*. 2011; 64: 595–601.
- [15] Lin CH, Lin CH, Wu CW, Liao CT. Sternocleidomastoid muscle flap: an option to seal off the esophageal leakage after free jejunal flap transfer – a case report. *Chang Gung Med J*. 2009; 32: 224–229.
- [16] Agarwal A, Gracely E, Maloney RW. Lip augmentation using sternocleidomastoid muscle and fascia grafts. *Arch Facial Plast Surg*. 2010; 12: 97–102.
- [17] Cheng JC, Tang SP, Chen TM. Sternocleidomastoid pseudotumor and congenital muscular torticollis in infants: a prospective study of 510 cases. *J Pediatr*. 1999; 134: 712–716.
- [18] Ozgur Z, Govsa F, Celik S, Ozgur T. An unreported anatomical finding: unusual insertions of the stylohyoid and digastric muscles. *Surg Radiol Anat*. 2010; 32: 513–517.