



## Multiple tendons of abductor pollicis longus

Published online February 23rd, 2010 © <http://www.ijav.org>Dil Islam MANSUR <sup>(1)</sup>Ashwin KRISHNAMURTHY <sup>(1)</sup> ✦Soubhagya R NAYAK <sup>(2)</sup>Ganesh KUMAR C <sup>(1)</sup>Rajalakshmi RAI <sup>(1)</sup>Sujatha D'COSTA <sup>(1)</sup>Latha V. PRABHU <sup>(1)</sup>

Department of Anatomy, Kasturba Medical College, Centre for Basic Sciences, Bejal, Mangalore, Karnataka <sup>(1)</sup> and Department of Anatomy, College of Medicine, JNM Hospital, Kalyani, Nadia, WB <sup>(2)</sup>, INDIA.



✦ Ashwin Krishnamurthy, MBBS, MD  
Department of Anatomy  
Kasturba Medical College  
Centre for Basic Sciences  
Bejal, Mangalore, Karnataka, INDIA.  
☎ +91 824 2211746  
✉ anatashwin@gmail.com

Received July 27th, 2009; accepted January 20th, 2010

### ABSTRACT

Anatomic variations of the tendons of the abductor pollicis longus (APL) and its knowledge is important to assess the diseased and traumatized hand and when considering tendons for repair or graft. During routine dissection of a 63-year-old male cadaver, in the Department of Anatomy, Kasturba Medical College, Mangalore, Karnataka, India we came across an unusual APL in the right upper limb. The muscle had altogether 9 tendons and they were inserted to the lateral and anterolateral sides of the base of the 1st metacarpal bone, opponens pollicis (two tendons each), the abductor pollicis brevis, trapezium and thenar fascia (one tendon each). The number of accessory tendons of APL has functional significance in the development of de Quervain's syndrome.

© IJAV. 2010; 3: 25–26.

**Key words** [abductor pollicis longus] [anatomic variation] [accessory tendons] [de Quervain's syndrome]

### Introduction

The extensor compartment of the forearm of the human body is one with frequent variations of its contents. Among all, the abductor pollicis longus (APL) muscle is known to exhibit numerous variations. Variations in the number of tendons of APL muscle may be asymptomatic and often incidental finding [1]. The present variation detected in a 63-year-old male cadaver, describes the APL muscle having nine tendons. The presence of accessory tendons may be important in de Quervain's syndrome [2].

Anatomical knowledge of such variations may be clinically important for surgeons performing reconstructive hand surgeries in the dorsolateral region of the hand. In a wider perspective, variations in the number of tendons of APL may also be important for anthropological correlation and academic studies [1].

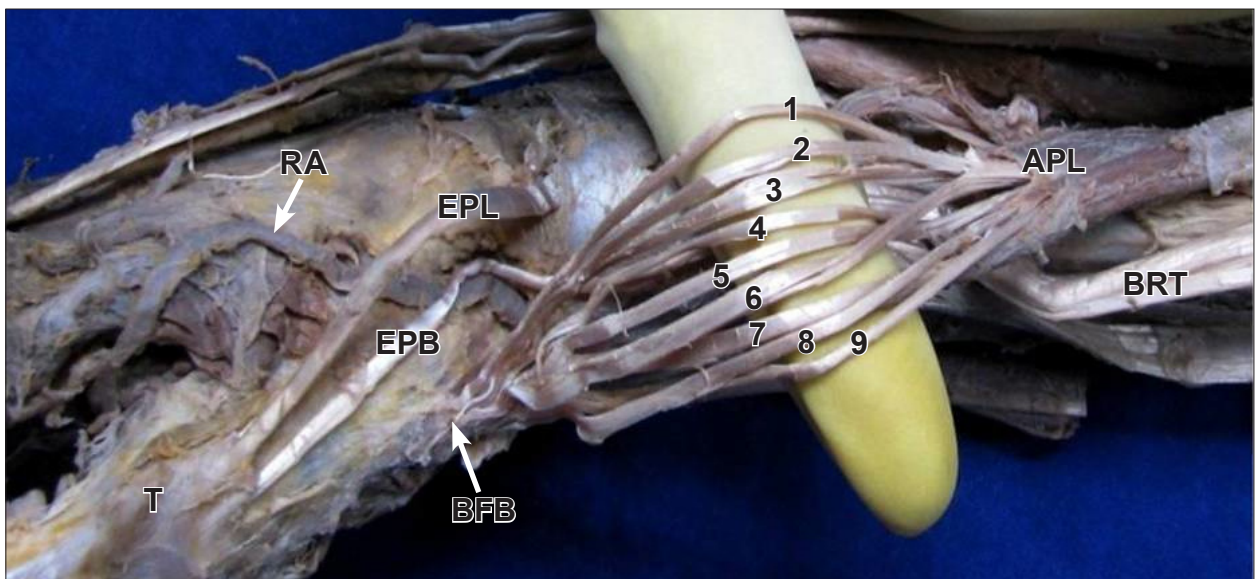
### Case Report

During routine dissection of a 63-year-old male cadaver, in the Department of Anatomy, Kasturba Medical College, Mangalore, Karnataka, India, we came across an unusual APL in the right upper limb. The muscle had altogether 9 tendon slips of insertion. The proximal attachment of the muscle was found deeply in the middle third of the forearm from middle of the posterior surface of the radius, upper most part of the lateral area on the posterior surface of the shaft of the ulna and interosseous membrane. At the lower part it crossed the two radial

extensors of wrist (extensor pollicis longus and extensor pollicis brevis). APL had altogether 9 tendons and they were inserted to the lateral and anterolateral sides of the base of the first metacarpal bone and opponens pollicis (two tendons each), to the abductor pollicis brevis, trapezium and thenar fascia (one tendon each). It was innervated by a branch of posterior interosseous nerve.

### Discussion

The APL is important muscle of dexterity. Knowledge about its variations is important in clinical assessment and reconstructive surgery [3]. It is exceptional to find a single tendon or insertion of APL [4]. Considering the fact that multiple tendon variation is more frequent, the clinical importance of such variations cannot be neglected. The variations of tendons have been reported by many researchers. A maximum of seven tendons of APL have been reported [5]. The multiple tendons of APL may alter the force component, thereby altering the mechanics of the thumb. During any surgery, the existence of multiple tendons of APL is bound to confuse any surgeon. The variations in number of APL tendons and the corresponding osseo-fibrous canals have been reported to be involved in the etiology and subsequent decompression of de Quervain's syndrome. Many a time, lack of prior anatomical knowledge may lead to inadequate surgical decompression of de Quervain's syndrome [6]. The APL is known to have split insertion in chimpanzees, gorillas and gibbons [7]. A bilateral digastric muscle formed by APL and abductor pollicis



**Figure 1.** Anterolateral view of right hand showing nine tendons of APL. (APL: abductor pollicis longus; 1-9: tendons of APL; BRT: brachioradialis tendon; BFB: base of the first metacarpal bone; EPB: extensor pollicis brevis; EPL: extensor pollicis longus; RA: radial artery; T: thumb)

brevis has also been mentioned [8]. Rayan and Mustafa [9] reported abnormal insertion of an APL slip into an anomalous thenar muscle. The anomalous thenar muscle, most probably, represented duplication of abductor pollicis brevis. Bilateral subluxation of the trapezio-metacarpal joint has been attributed to abnormal insertion of APL tendon and an atrophic extensor pollicis brevis tendon [10]. Splitting of the APL has been reported. In one case the APL split into two bellies and gave off two tendons. One tendon inserted into the thenar muscles and the other inserted into the first metacarpal bone, which is considered a normal site for the APL [11]. In another case APL tendon had four slips, which inserted into the fascia of abductor pollicis brevis, distal and palmar to the trapezio-metacarpal joint [9]. The number, thickness and the length of the accessory tendons have a functional significance in the development of de Quervain's syndrome [2].

The existence of such variations in the human beings may be a result atavism. Hence the presence of such

variants also underlines the anthropological importance. The presence of multiple tendons may be important for surgeons performing grafting operations in the dorso-lateral compartment of the hand. The present case report is a humble submission to highlight the existence of multiple tendons of APL and its clinical importance in day-to-day clinical practice.

### Conclusion

The presence of accessory tendons of APL in the present case may cause de Quervain's syndrome, further the clinicians and surgeons should be aware of such anatomical variations while operating for tendon transfer in the vicinity of the wrist and the dorsal surface of the hand. Often the surgeon is exposed to vagaries of the hand region only during operation and a prior anatomical knowledge of such variations maybe helpful in checking any inadvertent injury to the accessory tendons. Additional tendons may be used for reconstructive surgery.

### References

- Paul S, Das S. Variant abductor pollicis longus muscle: a case report. *Acta Medica (Hradec Kralove)*. 2007; 50: 213–215.
- Melling M, Witte J, Schnellinger M, Schweighart W, Panholzer M. Supernumerary tendons of the abductor pollicis. *Acta Anat (Basel)*. 1998; 155: 291–294.
- Nayak SR, Krishnamurthy A, Pai MM, Prabhu LV, Ramanathan LA, Ganesh Kumar C, Thomas MM. Multiple variations of the extensor tendons of the forearm. *Rom J Morphol Embryol*. 2008; 49: 97–100.
- Coleman SS, McAfee DK, Anson BJ. The insertion of the abductor pollicis longus muscle; an anatomical study of 175 specimens. *Q Bull Northwest Univ Med Sch*. 1953; 27: 117–122.
- Melling M, Reithsner R, Steindl M, Karimian-Teherani D, Schnellinger M, Behnam M. Biomechanical stability of abductor pollicis longus muscles with variable numbers of tendinous insertions. *Anat Rec*. 1998; 250: 475–479.
- Giles KW. Anatomical variations affecting the surgery of de Quervain's disease. *J Bone Joint Surg Br*. 1960; 42-B: 352–355.
- Lacey T 2nd, Goldstein LA, Tobin CE. Anatomical and clinical study of the variations in the insertions of the abductor pollicis longus tendon, associated with stenosing tendovaginitis. *J Bone Joint Surg Am*. 1951; 33-A: 347–350.
- Saeed M, Rufai AA, Elsayed SE, Sadiq MS. Variations in the subclavian-axillary arterial system. *Saudi Med J*. 2002; 23: 206–212.
- Rayan GM, Mustafa E. Anomalous abductor pollicis longus insertion in the thenar muscles. *J Hand Surg Am*. 1989; 14: 550–552.
- Martinez R, Omer GE Jr. Bilateral subluxation of the base of the thumb secondary to an unusual abductor pollicis longus insertion: A case report. *J Hand Surg Am*. 1985; 10: 396–399.
- Yukseil M, Onderoglu S, Arlik Z. Case of an abductor pollicis longus muscle: variation or differentiation? *Okajimas Folia Anat Jpn*. 1992; 69: 169–171.