



## Case Report

# Multiple “retrogressive” variations in upper limb

Published online June 12th, 2011 © <http://www.ijav.org>

Gurusiddappa Chandrashekarappa POORNIMA <sup>+</sup>  
Kantharajapura Rajagopal DAKSHAYANI

Department of Anatomy, Mysore Medical College & Research Institute, Mysore, INDIA.



<sup>+</sup> Dr. Gurusiddappa Chandrashekarappa Poornima  
Associate Professor  
Department of Anatomy  
Mysore Medical College & Research Institute  
Mysore, 570001, INDIA.  
☎ +91 99725 15908  
✉ poornige2009@yahoo.com

Received October 23rd, 2010; accepted April 23rd, 2011

### ABSTRACT

The muscular, neural and vascular variations of upper limb are not uncommon. Their importance become apparent with regard to surgical approaches for various clinical conditions and comparative anatomy involving the upper limb.

Even though individually presence of 3rd head of biceps brachii, absence of musculocutaneous nerve, innervations of the flexors of arm by median nerve, accessory belly Ganzter’s muscle in the forearm, median artery in the forearm and formation of superficial palmar arch by median artery are common occurrence.

The combination of all these events occurring in a single upper limb is a rare phenomenon.

During routine dissection class of 1st MBBS students at MMC & RI, Mysore, we observed the above mentioned unilateral variations in the left upper limb of a middle aged male cadaver. © IJAV. 2011; 4: 109–111.

**Key words** [biceps brachii] [median nerve] [median artery] [superficial palmar arch]

### Introduction

Many variations are found in man which correspond to normal arrangements in the lower animals. In some instances, the ancestral character that had disappeared in evolution makes its presence in human beings. In such situation we quote “antogeny recapitulates phylogeny”. Here is one such case seen unilaterally in the left upper limb.

### Case Report

In present study the following were observed in the left upper limb of a middle aged male cadaver. The dissection was carried in Department of Anatomy, Mysore Medical College & Research Institute, Mysore. The body was preserved in 10% formalin.

The third head of biceps brachii was originating below the insertion of coracobrachialis (CB), laid medial to brachialis. It joined with tendon of biceps brachii and formed bicipital aponeurosis. It was innervated by median nerve (MN) (Figure 1). We also observed a median artery (MA) of palmar variant took origin in the upper 1/3rd of forearm at the level of neck of radius between ulnar artery and common interosseous artery. The MA coursed lateral to MN and pierced it posteriorly (Figures 2, 3). In middle third of forearm, the artery was anterior to MN and in distal third it was between the tendons of flexor carpi radialis (FCR)

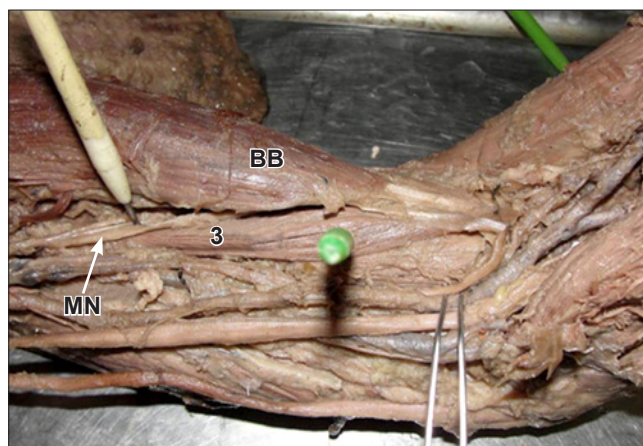
and middle finger tendon of flexor digitorum superficialis (FDS). The artery traversed deep to flexor retinaculum and terminated by forming superficial palmar arch (SPA) of mediano-ulnar type (Figure 3). The median artery gave few muscular branches at its origin, no digital branches in the palm (Figures 2, 3).

An accessory muscle was also noticed in the same forearm between FDS and flexor pollicis longus (FPL) with a central belly about 6–8 cm in length. This accessory muscle (Ganzter’s) laid behind the MN and MA. It was innervated by MN and vascular supply by MA (Figures 2, 4).

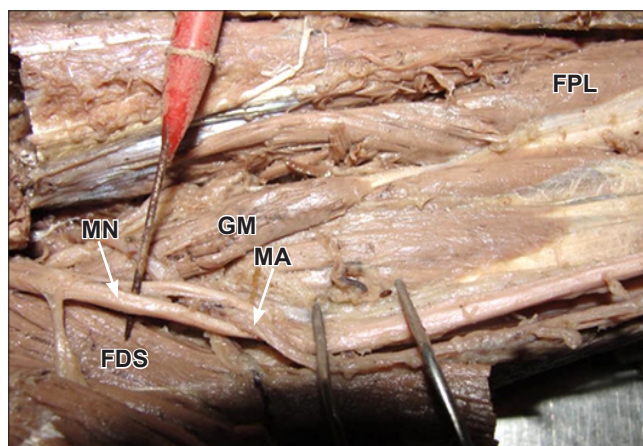
### Discussion

The biceps brachii is a large fusiform muscle deriving its name by its 2 proximally attached parts. This muscle is one of the most variable muscles in the human body, in terms of its heads and morphology [1,2]. It has frequently more than 2 heads arising from humerus at insertion of coracobrachialis or neck of humerus. There are reports describing supernumerary bicipital heads ranging from 3 to 7 in different population groups. The 3 headed variant is the most common type with prevalence ranging between 7.5–18.3% [1,2].

Previous studies show that the 3rd head of biceps brachii is seen in about 8% of Chinese [1,2], 10% of Europeans, 12% of



**Figure 1.** Photograph showing the third head of biceps brachii (3) having a common insertion with biceps brachii (BB). (MN: median nerve)



**Figure 2.** Photograph showing the Ganzter's muscle (GM) connecting flexor digitorum superficialis (FDS) with flexor pollicis longus (FPL). Median nerve (MN) is pierced by median artery (MA).

Black Africans, 18% of Japanese, 20.5% of South Africans blacks, 8.3% of South Africans whites [1].

The 3rd head of biceps brachii is a common occurrence in mammals [1]. The third head in present case was of type 1 – based on its origin, which is at the insertion of CB [1,2]. Human lack long head of CB, in cases where third head arises at the insertion of CB, it represents the remnant of long head of CB, an ancestral hominoid muscle [1].

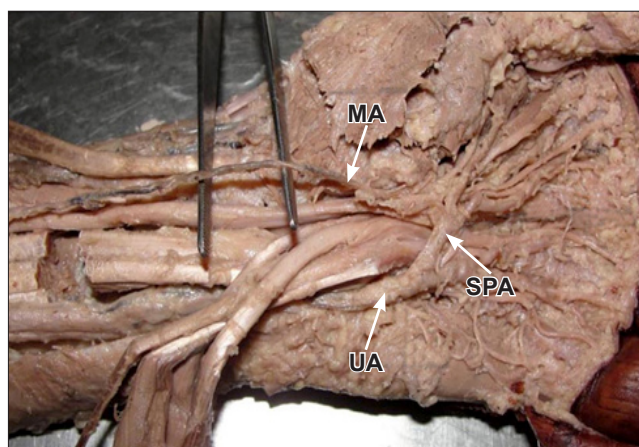
In the cercopithecus, long head of CB may find insertion into radial tuberosity in common with biceps brachii [1]. The third head may provide additional strength to biceps during supination of forearm and elbow flexion irrespective of shoulder position [1].

The musculocutaneous nerve (MCN) frequently shows the following variation: double, short or totally absent. The MCN arise from lateral cord in 90.5%, from lateral and posterior cords in 1.4% of cases. Very rarely the nerve

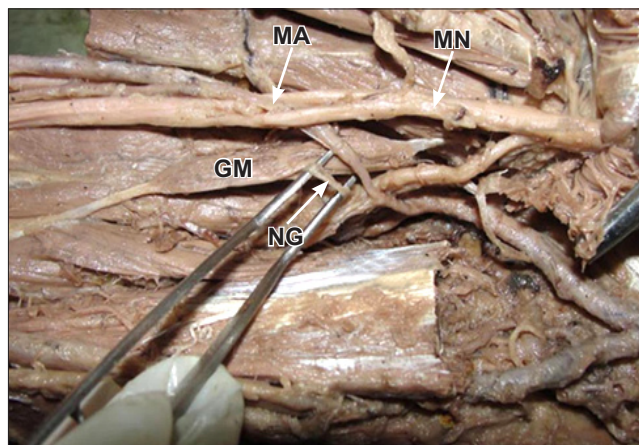
instead of piercing coracobrachialis, may adhere to MN for some distance down the arm, either as a single trunk or several branches may pass between biceps and brachialis. Communication between MN and MCN occur in the distal part of arm but in the proximal region it occurs in 8% of the cases [3].

In this case, the MCN was absent, the flexors of the arm were innervated by the lateral root of MN [3]. The third head of biceps received the same innervation.

It has been reported that there is only one trunk equivalent to MN in the thoracic limb of lower vertebrates like the amphibian, reptiles and bird [4]. In man the forelimb muscles develop from the mesenchyme of paraxial mesoderm in the 5th week of embryonic life. The axons of spinal nerves grow distally to reach the mesenchyme of limb bud. The peripheral processes of motor and sensory neurons grow in the mesenchyme in different directions [4]. Expressions



**Figure 3.** Photograph showing the median artery (MA) forming the superficial palmar arch (SPA) with ulnar artery (UA).



**Figure 4.** Photograph showing the Ganzter's muscle (GM) innervated by median nerve (MN). Median nerve is pierced by median artery (MA). (NG: nerve to Ganzter's muscle)

of chemoattractants and repellents regulate the developing axon in a systemic site-specific manner. Variations are result of alteration of signal between mesenchymal cells and neural growth factors and also by circulatory factors at the time of formation of brachial plexuses [4]. The combination of above events might have occurred during development, which resulted in the present variation in the arm.

The presence of fusiform muscle belly or accessory muscle (Gantzer's) was reported back 1813 by Gantzer, and this muscle has been reported with variable attachments. The accessory heads of forearm been reported to insert FPL or FDP [5].

In the present case, the accessory muscle (Gantzer's) muscle attaching FDS to FPL was along with the persistent MA which pierced the MN in the upper 1/3rd of the forearm.

The MA in relation with the Gantzer's muscle, is anterior to it in 20% of cases or 17% posterior to the muscle [6], as seen in this case. The Gantzer's muscle is innervated by MN and vascular supply by MA [6].

The presence of Gantzer's muscle also called accessory head of flexor muscles have been described in primates and other mammals (pigs, foxes and marmots). It is the muscle belly that connects the medial epicondyle origin of FDS with more or less differentiated deep flexor muscles [5].

The flexors of forearm that develop from flexor mass divide into two layers as superficial and deep. The FDS, FDP, FPL originate from deep layer. The existence of accessory muscles connecting the flexor muscles could be explained by incomplete cleavage of deep layer of flexor mass during development which represents an "atavistic character" [5].

The MA is of Type1 (palmar) is a transitory vessel that represents the arterial axis during early embryonic life. It

normally regresses by 2nd month to become a small slender artery—arteria comitans nervi mediana [7]. It is usually conserved in domestic animals and lower tetrapods [8]. Incidence of palmar type of MA has been reported ranging from 1.5% to 27.1% cases [8].

In this case, in the upper third of forearm, MA pierced the MN—in such instances, it can cause pronator syndrome and anterior interosseous syndrome [6]. This neurovascular relationship has been described in anatomical studies as occasional findings [6]. In the middle third of forearm it is between FCR and middle finger tendon of FDS.

In the current case, the MA terminated in the SPA, initial caliber of the MA was thick, in the distal third of the forearm it was a slender trunk. It traversed deep to FR and formed SPA. Here it can cause carpal tunnel syndrome [6]. The SPA was Group 1 type C variety (3.8%)—medianoulnar arch that is composed of ulnar artery and an enlarged MA [9]. Here in this case MA gave muscular branches in the forearm including accessory muscle, but in palm it did not contribute.

We thus conclude that the present case is unique by retainment of ancestral character in each part of the left limb, with the neuronal and vascular modifications with their clinical implications. The variations are retrogressive as ontogeny recapitulates phylogeny in each instance that as occurred and associated clinical conditions are highlighted. It is "retrogressive" as the variations has occurred in lower forms of animals or in the embryonic life, later disappeared and again makes its presence in humans [10].

This adds up to the present knowledge and also helps anatomists and clinicians for future references.

## References

- [1] Asvat R, Candler P, Sarmiento EE. High incidence of the third head of biceps brachii in South African populations. *J Anat.* 1993; 182: 101–104.
- [2] Sargon MF, Tunçali D, Celik HH. An unusual origin for the accessory head of biceps brachii muscle. *Clin Anat.* 1996; 9: 160–162.
- [3] Gumushurum E, Adiguzel E. A variation of the brachial plexus characterized by the absence of the musculocutaneous nerve: a case report. *Surg Radiol Anat.* 2000; 22: 63–65.
- [4] Chauhan R, Roy TS. Communication between the median and musculocutaneous nerve—a case report. *J Anat Soc India.* 2002; 51: 72–75.
- [5] Jones M, Abrahams PH, Sanudo JR, Campillo M. Incidence and morphology of accessory heads of flexor pollicis longus and flexor digitorum profundus (Gantzer's muscles). *J Anat.* 1997; 191: 451–455.
- [6] Rodriguez-Niedenfuhr M, Sanudo JR, Vazquez T, Nearn L, Logan B, Parkin I. Median artery revisited. *J Anat.* 1999; 195: 57–63.
- [7] Vollala VR, Nagabhooshana S, Bhat SM, Potu BK, Rakesh V. Multiple accessory structure in the upper limb of a single cadaver. *Singapore Med J.* 2008; 49: 254–258.
- [8] Sanudo JR, Chikwe J, Evans SE. Anomalous median nerve associated with persistent median artery. *J Anat.* 1994; 185: 447–451.
- [9] Gopichand PVV, Kalsey G, Rajan SK. Superficial palmar arch duplication—a case report. *J Anat Soc India.* 2000; 49: 63–66.
- [10] Schafer EA, Symington J, Bryce TH. Quain's Elements of Anatomy. Vol. 4., London, Longmans Green & Co. 1923: 30.