

---

## CASE SERIES

---

# Hepato-Pancreatic-Biliary (HPB) tuberculosis: Case series of six cases and literature review

Balram Goyal<sup>1</sup>, Manish Manrai<sup>2</sup>, Deepti Mutreja<sup>3</sup>, Rohit Aggarwal<sup>4</sup>, Priyanshi Maurya<sup>5</sup>

Goyal B, Manrai M, Mutreja D, et al. Hepato Pancreatic Biliary (HPB) tuberculosis: Case series of six cases and literature review. *Surg Case Reports*. 2022; 6(3):1-4.

### ABSTRACT

Abdominal Tuberculosis (TB) is well known clinical entity and it involves peritoneum, lymph nodes, intestine and solid organs. Involvement of hepatobiliary tract and pancreas is less common. It often mimics as malignancy and often possess diagnostic dilemma.

Here, we are presenting data and our experience of Six cases diagnosed and managed as Heptopancreaticobiliary (HPB) tuberculosis

Two patients initially suspected to have malignancy on the basis of clinical and radiological findings. One patient found to have numerous small lesions involving both lobe of liver, during laparoscopic cholecystectomy, giving a visual impression of possibly metastatic in nature which turned out to be of

tubercular on histopathological examination. On further evaluation he was diagnosed to have disseminated TB. Three patients presented with fever and managed as case of pyogenic liver abscess. There was no response to broad spectrum IV antibiotics. On further evaluation tubercular nature of liver abscesses confirmed and all 03 patients successfully treated with ATT. High index of suspicion and keeping HPB TB is one of differential diagnosis is of paramount importance for positive outcome.

**Key Words:** *Heptopancreaticobiliary (HPB); Abdominal Tuberculosis; Antituber Cular Treatment (ATT)*

---

### INTRODUCTION

Abdominal Tuberculosis (TB) is well known and it involves the peritoneum, lymph nodes, intestine, and solid organs. Involvement of the hepatobiliary tract and pancreas is less common. It often mimics a malignancy and often possesses a diagnostic dilemma. A high index of suspicion is of paramount importance for diagnosis and timely intervention.

Here, we are presenting data and our experience of six cases diagnosed and managed during the last 05 years. Out of these six patients male (03) and female (03) with age range 18 years-45 years.

Two patients were initially suspected to have malignancy based on clinical and radiological findings. Three cases presented with fever diagnosed to have multiple hepatic abscesses.

One patient was found to have numerous small lesions involving both lobes of the liver, during laparoscopic cholecystectomy, giving a visual impression of possibly metastatic which turned out to be tubercular on histopathological examination. On further evaluation, he was diagnosed to have disseminated TB.

### 1<sup>st</sup> CASE

42-year-old lady presented with features of obstructive jaundice associated with significant unintentional weight loss over 03 months duration. There was no history of fever, GI Bleed, or anorexia. Clinically, she was well preserved with ECOG performance status 1 and had icterus. Her abdominal examination revealed a palpable gallbladder. The rest of the systemic examination was essential within normal limits.

Her Lab parameters were Hb 10 gm%, TLC 6300/cmm, (P72 L20 E02 B06), Plt 287000/cmm LFT S Bil/OT/PT/ALP (3.0/65/69/1389). Her tumor marker levels CA 19-9: 14.94 U/mL, CEA: 1.35 U/mL.

Imaging Ultrasonography and CECT abdomen revealed dilated common bile duct, bilateral IHBR dilatation, and sludge in the gallbladder. She was further subjected to side viewing endoscopy which showed a deformed and bulky ampulla and biopsy from the same was nonspecific duodenitis (Figure 1).

---

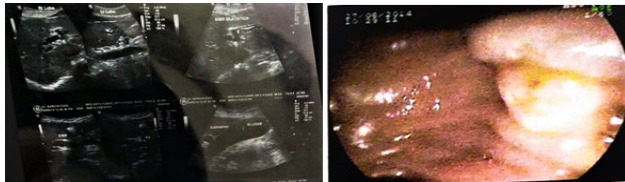
<sup>1</sup>Department of Surgical Gastroenterology Command Hospital (Southern Command) Pune, India; <sup>2</sup>Department of Gastroenterology Armed Forces Medical College Pune India; <sup>3</sup>Department of Pathology Armed Forces Medical College Pune, India; <sup>4</sup>Department of Radiology Command Hospital (Southern Command) Pune, India; <sup>5</sup>Intern Command Hospital (Southern Command) Pune, India

Correspondence: Dr Balram Goyal, Department of Surgical Gastroenterology Command Hospital (Southern Command) Pune, India. Telephone 9401562326, e-mail balramneetu.goyal@gmail.com

Received:- 23 October, 2022, Manuscript No. PULSCR-22-5514; Editor assigned:- 26 October, 2022, Pre-QC No. PULSCR-22-5514(PQ); Reviewed:- 12 November, 2022, QC No. PULSCR-22-5514(Q); Revised:- 15 November, 2022, Manuscript No. PULSCR-22-5514(R); Published:- 30 November, 2022, DOI: 10.37532/pulscr.22.6.3.1-3



This open-access article is distributed under the terms of the Creative Commons Attribution Non-Commercial License (CC BY-NC) (<http://creativecommons.org/licenses/by-nc/4.0/>), which permits reuse, distribution and reproduction of the article, provided that the original work is properly cited and the reuse is restricted to noncommercial purposes. For commercial reuse, contact reprints@pulsus.com



**Figure 1) Dilated IHBR and Bulky Ampulla**

Her PET CT scan was suggestive of periampullary growth with extensive nodal and vertebral metastasis and bilateral cervical level lymph nodes (max SUV 5.53) she underwent USG-guided FNAC of cervical lymph node which revealed the focus of epithelioid cell clusters and multinucleated macrophages seen.

She was started on ATT following CBD stenting. She recovered well and a repeat PET CT done after 3 months of commencement of ATT showed significant regression of all lesions.

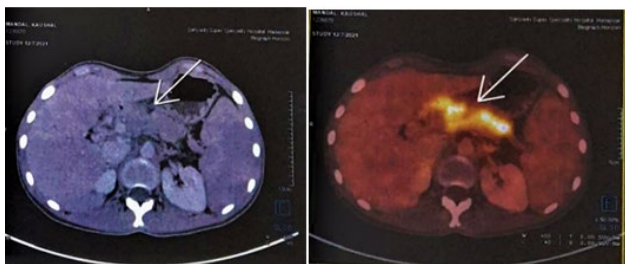
She was on regular follow-up and diagnosed to have biliary strictures for which underwent Hepaticojejunostomy (HJ) due to failure of endoscopic management. Presently, she is asymptomatic, doing well, and on regular follow-ups.

**2<sup>nd</sup>CASE**

20 years old male engineering student presented with diffuse upper abdominal pain, melena, anorexia, and significant unintentional weight loss of one-month duration.

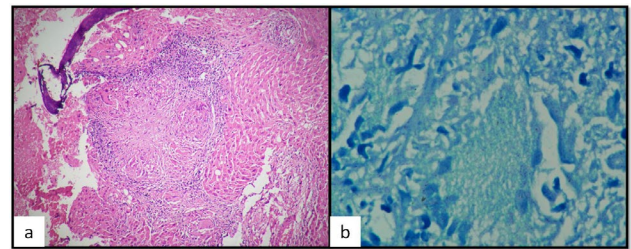
There was no history of fever, jaundice, cough, or diarrhea. He was evaluated with upper GI endoscopy which revealed a duodenal ulcer with stricture formation. He was started on PPI and had a partial response. He continued to be symptomatic with pain abdomen and developed features of GOO which were further evaluated with CECT abdomen which revealed a pancreatic head mass infiltrating the portal vein and multiple lymph nodes which seemed to be inoperable.

His CA 19.9 was 22 U/ml. PET CT revealed hypermetabolic ill-defined lesions involving the pancreatic neck, body, peripancreatic, and gastrohepatic regions with perilesional stranding (Figure 2).



**Figure 2) PET CT Hypermetabolic SOL pancreas**

Because of imaging and PET findings, he was advised to terminal care at home. He presented to our center where a repeat upper GI endoscopy revealed duodenal stricture (scope not negotiable). He was then taken up for diagnostic laparoscopy and gastrojejunostomy. Intraoperative findings showed millions of pleomorphic tubercles scattered throughout the peritoneal surface, making a visual impression of TB which was later confirmed by the histopathological report (Figure 3).

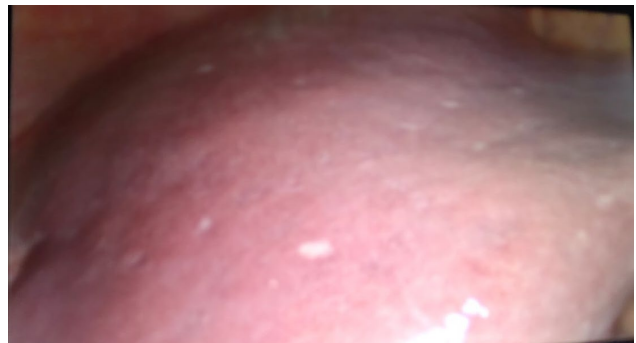

**Figure 3) Granuloma with caseous necrosis and Giant cell**

He was started on the Anti-Tubercular Drug (ATT). Within a few months, his appetite returned to normal, he gained weight and recovered well, and follow-up PET CT after 03 months suggested complete regression of previously mentioned lesions.

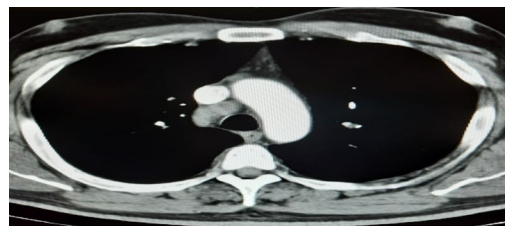
**3<sup>rd</sup>CASE**

A 37 years old male, with a known case of diabetes mellitus and hypertension presented with h/o recurrent episodes of pain abdomen (RUQ) for 02 years. The pain was localized to right hypochondrial region, intermittent, moderate to severe in intensity, colicky in nature, and not associated with fever, jaundice, GI bleeding, anorexia, or weight loss. His clinical examination was essential within normal limits. His lab parameters were normal while USG Abd was suggestive of cholelithiasis. He was taken for laparoscopic cholecystectomy intraoperatively multiple hepatic SOL were present scattered all over the liver surface (Figure 4).

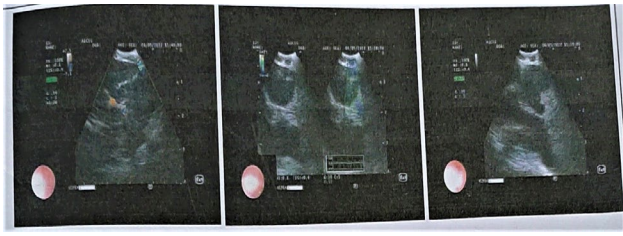


**Figure 4) Multiple SOL seen on laparoscopy**

Multiple biopsy taken and submitted for histopathological examination. Biopsy revealed these hepatic SOLs of granulomatous in nature and negative staining for acid fast bacilli. He was further evaluated and underwent a CECT chest and abdomen which revealed multiple mediastinal lymphadenopathies. Endobronchial ultrasound showed multiple conglomerated necrotic lymph nodes (subcarinal approx. 2.5 cm and right paratracheal approx. 16 mm) (Figures 5 and 6).



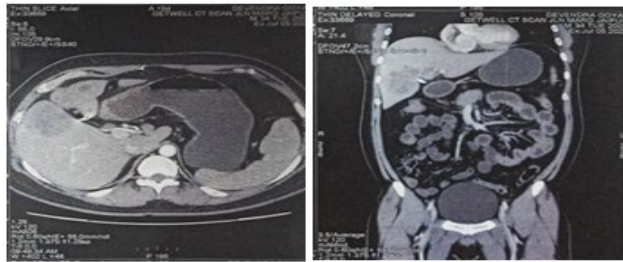
**Figure 5) Mediastinal Nodes (ShortArrow)**



**Figure 6)** Endobronchial USG; Large lymph nodal mass  
Biopsy from the same showed granulomatous tissues. He has been started on ATT and is on regular follow-up.

#### Liver abscess 03 cases

Out of these three cases, two patients were male and one was female. Two of them had a similar presentation of liver abscess associated with high-grade fever not responding to broad spectrum IV antibiotics/antifungal while one male patient had a recurrent fever of 06 months duration as he had a partial response to IV antibiotics (Figure 7).



**Figure 7)** CECT abdomen showing hepatic SOL (Rt lobe)

#### DISCUSSION

Tuberculosis is the most important communicable disease worldwide and has staged a global comeback. An abdominal variant is one of the common sites of extrapulmonary involvement and is a great mimicker which often possess a diagnostic challenge to the clinician. The abdomen is involved in around 11 % of patients with extra-pulmonary tuberculosis [1].

Abdominal tuberculosis denotes involvement of the gastrointestinal tract, peritoneum, lymph nodes, and solid viscera, eg, liver, spleen, pancreas, etc. and it is distinct from pulmonary tuberculosis in that it affects young adults more commonly (mean age in India, 31 years) The first report of pancreatic tuberculosis was reported by Auerbach in 1944. In his series of 1656 autopsies of tuberculosis patients, only 14 cases had pancreatic involvement with an incidence of 4.7% [2]. The primary site of TB is usually not evident in most cases of hepatobiliary and pancreatic TB. The liver is affected most commonly as a part of a military spread of tuberculosis from the lung via the hepatic artery. Infection can also spread through the portal vein or lymphatics, especially in patients with concomitant TB of the gastrointestinal tract [3, 4].

The symptomatology of pancreatic and hepatic tuberculosis is often nonspecific. Affected patients may remain asymptomatic as evident in the third patient. In a study of 42 cases, 19 patients (45.2%) were asymptomatic, while the others had various nonspecific symptoms [5]. In a series from India of 18 Patients

suffering from HPB TB, symptoms were abdominal pain (n=13) followed by jaundice (n=10), fever (n=9), anorexia (n=9), and weight loss (n=9). Only five (28%) had associated extra-abdominal TB (pulmonary, spinal, and cervical lymph node TB [5, 6].

In the majority of cases, the clinical and radiological information often mimics malignancy as in our two cases initial impression was made. In a study in 42 pts about 52% of cases, pancreatic tuberculosis was misdiagnosed for pancreatic cancer, lymphoma, or retroperitoneal lymph node metastases and in the majority of pts results of surgical intervention were futile [5].

Abdominal ultrasound is often the imaging modality of choice in patients presenting with pain abdomen and jaundice. Findings may be non-specific homogeneous or heterogeneous masses. Other advanced imaging modalities may be of no use as findings are non-specific and may be seen in focal pancreatitis or pancreatic carcinoma [7, 8].

Once the diagnosis of TB is established ATT will cure the disease and surgery may be not required. However, in our first case developed biliary stricture and subsequently required HJ and in the second case GJ was done due to duodenal stricture [9].

#### CONCLUSION

Tuberculosis is a great masquerade and must be considered in particularly young and well-preserved patients. A high index of suspicion is required and a good long-term outcome is anticipated with ATT

#### REFERENCES

1. Aston NO, Chir M. Abdominal tuberculosis. *World J Surg.* 1997; 24: 492-99.
2. El Majdoubi MT. Tuberculose pancréatique, à propos d'un cas. Étude de 40 cas publiés dans la littérature. Thèses de Médecine. 2011.
3. Terry RB, Gunnar RM. Primary miliary tuberculosis of the liver. *JAMA.* 1957; 164: 150-57.
4. Hersch C. Tuberculosis of the liver. A study of 200 cases. *S Afr Med J.* 1964; 38: 857-63.
5. Kim JB, Lee SS, Kim SH, et al. Peripancreatic tuberculous lymphadenopathy masquerading as pancreatic malignancy: a single-center experience. *J. Gastroenterol. Hepatol.* 2014; 29: 409-16.
6. Saluja SS, Ray S, Pal S, et al. Hepatobiliary and pancreatic tuberculosis: a two decade experience. *BMC Surg.* 2007; 7(1): 1-9.
7. Kacemi L, Dafiri R. Imagerie d'une atteinte tuberculeuse du foie et du pancréas chez un enfant révélée par un ictère. *J. Radiol.* 2006; 87(4): 396-98.
8. Suri S, Gupta S, Suri R. Pictorial review, Computed tomography in abdominal tuberculosis. *Br J Radiol.* 1999;72: 92-8.
9. Kacemi L, Dafiri R. Imagerie d'une atteinte tuberculeuse du foie et du pancréas chez un enfant révélée par un ictère. *J. Radiol.* 2006; 87(4): 396-398.