

Hairy tongue, geographic tongue, scrotal tongue and systemic connections: clinical images and an overview

Cinzia Casu, DDS¹, Maria Giulia Nosotti, RDH², Antonia Sinesi, RDH², Giovanna Mosaico, RDH²

Casu C, Nosotti MG, Sinesi A, et al. Hairy tongue, geographic tongue, scrotal tongue and systemic connections: clinical images and an overview. *Dentist Case Rep.* 2019;3(1):01-03.

ABSTRACT

Black Hairy Tongue (BHT) is a benign condition, caused by a defect of keratin desquamation over lingual papillae and its discoloration is caused by the presence of porphyrin-producing chromogenic bacteria or yeast. Geographic Tongue (GT) is characterized by a central erythematous zone consisting of atrophy of the filiform papillae, whereas the white zone shows regenerating filiform papillae along with keratin. Scrotal Tongue (ST) is a common

condition, predominantly asymptomatic. Clinically, it is characterized by fissures with a depth of up to 6 mm that extend along the dorsal and/or lateral sides of the tongue. These benign entities are connected with systemic disease (psoriasis, diabetes, hypertension and GT; tumors, radiant therapies and BHT; fungal infections and Merkeson-Rosenthal syndrome and ST). Although an association between elevated IgE and migrant glossitis has been documented, associations between the three lingual conditions and the presence of allergy are unclear. We would like to present a case in which the 3 conditions were present in the same tongue of a female patient with allergic rhinitis and calcium deficiency.

Key Words: *Geographic tongue; scrotal tongue; black hairy tongue*

The tongue is considered the most complex organ of the body and a very important structure in the oral cavity. It is involved in various functions including taste, phonation, chewing and swallowing tongue is considered the most complex organ of the body and a very important structure in the oral cavity. It is involved in various functions including taste, phonation, chewing and swallowing. The status of the tongue is considered an indicator of systemic health and disease (1). The human tongue may be the site of reactive and inflammatory processes like the villous tongue, pigmented fungiform papillae of the tongue, benign migrant glossitis and scrotal or fissured tongue (2). Black Hairy Tongue (BHT) is a benign condition, caused by a lack of adequate desquamation of keratin over filiform lingual papillae on the dorsal surface of the tongue and the discoloration is caused by the presence of porphyrin-producing chromogenic bacteria or yeast (3). The condition's discovery dates back to 1557, when Dr. Amatus Lusitanus described a patient with BHT (4). Although it is usually asymptomatic, occasionally some patients may refer swelling or burning of the tongue, nausea, halitosis or a different appearance of the tongue, up to arrive, in more severe cases, a gagging reaction (5). Hairy tongue may appear brown, yellow, green, blue, or even unpigmented. Known predisposing factors include smoking, excessive coffee/black tea consumption, poor oral hygiene, trigeminal neuralgia, general debilitation, xerostomia and medication use (6). The exact prevalence of BHT is not known because its occurrence is highly variable among different populations and dependent on a multitude of factors; however, studies have shown that the prevalence may be as high as 11.3% with increased rates in men (18%) compared to women (6%), so men are about three times more affected than women (7,8). Geographic Tongue (GT) is also known as Benign Migratory Glossitis (BMG) since the lesion to migrate over time from one location to another. It is a benign condition commonly seen on the tip, lateral borders, and dorsum of the tongue. Clinically, it is characterized by a central erythematous zone consisting of atrophy of the filiform papillae, whereas the white zone shows regenerating filiform papillae along with keratin. Histologically, there is epithelial degeneration in the erythematous zone and elongated rete pegs with hyperkeratosis in the white zone.

The connective tissue shows infiltration of polymorphonuclear leukocytes and lymphocytes (9,10). The precise etiology remains obscure. Histopathologically, geographic tongue is characterized by hyperparakeratosis and acanthosis resembling psoriasis. Hence, it has been postulated that it represents a form of intraoral psoriasis. The condition is also associated with allergy, stress, diabetes mellitus, and anemia (11). Geographic tongue has a prevalence rate of 3% in the United States. The prevalence of BMG in the general population ranges from 1% to 3% (9). The prevalence of GT in the paediatric population ranges from 0.37% to 14.3% (10).

Scrotal Tongue (ST) is a frequent condition in the population, predominantly asymptomatic. Clinically, it is characterized by fissures with a depth of up to 6 mm that extend along the dorsal and/or lateral sides of the tongue. If the cracks are deep enough, food debris can settle in them causing inflammation of the tongue. In this case the patient must be instructed to correctly clean the tongue. ST can have many enlarged filiform papillae and inflammatory subepithelial infiltrations from polymorphonuclear leukocytes and lymphocytes (12,13).

According to the literature, the difference in prevalence between different age groups indicates that ST is not a congenital disease because it seems to have higher incidence in adults, and is very rare in children under 10 years of age. The most known cause is age; an additional factor is the hyposalivation which in turn is also associated with age. Most of the literature indicates a prevalence of 10-20% of ST in the population although there is a marked variation. Degrees of severity and number of individuals involved increase according to age and gender, more frequent in males than females, and smoking also exerts a predisposing factor. A correlation between the burning mouth syndrome and ST is also evident (12,13). We would like to propose a clinical case images of a patient with migratory glossitis, hairy tongue and scrotal tongue, with a history of calcium deficiency and allergic rhinitis.

CASE PRESENTATION

A 68-year-old woman comes to our attention for a slight burning of the tongue. In the anamnesis the patient reported: use of calcium supplements, sporadic antihistamines for allergic rhinitis; surgery of hallux valgus, recurrent gynecological infections. Observing the tongue we can see the presence of a film yellow-green in the tongue, slightly eroded areas, less than one centimeter in diameter, in the side edges, and a very jagged shape of the dorsum of the tongue (Figures 1-3). The patient also told us that small erosions change shape and location within a few days. A diagnosis of a villous tongue, a geographic map and a scrotal tongue was made.

The patient reported that this symptom had been present for some months but that lately she had become more symptomatic with spicy or sour foods. Gentle daily brushing of the tongue and rinsing with sodium bicarbonate was recommended for the patient. Laser therapy sessions to be performed at subsequent controls have been also recommended.

DISCUSSION

BHT presents two typical components as elongated filiform papillae and discoloration of the dorsal tongue, that is lined by non-keratinized stratified

¹Private Dental Practice, Cagliari, Italy; ²Freelancer, Piacenza, Italy

Correspondence: Cinzia Casu, DDS, Private Dental Practice, Cagliari, Italy. e-mail ginzia.85@hotmail.it

Received: December 24, 2018, Accepted: January 19, 2019, Published: January 25, 2019



This open-access article is distributed under the terms of the Creative Commons Attribution Non-Commercial License (CC BY-NC) (<http://creativecommons.org/licenses/by-nc/4.0/>), which permits reuse, distribution and reproduction of the article, provided that the original work is properly cited and the reuse is restricted to noncommercial purposes. For commercial reuse, contact reprints@pulsus.com

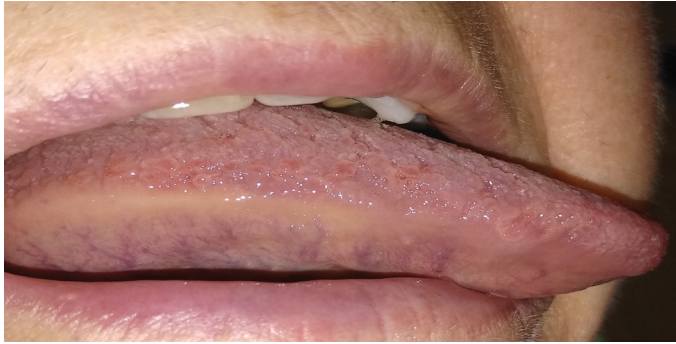


Figure 1) Tongue erosions

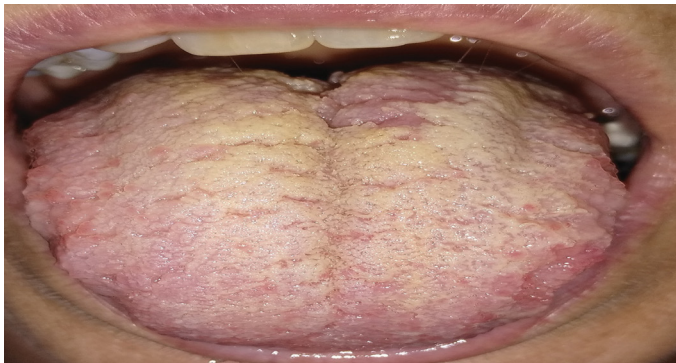

Figure 2) Hairy tongue and scrotal tongue

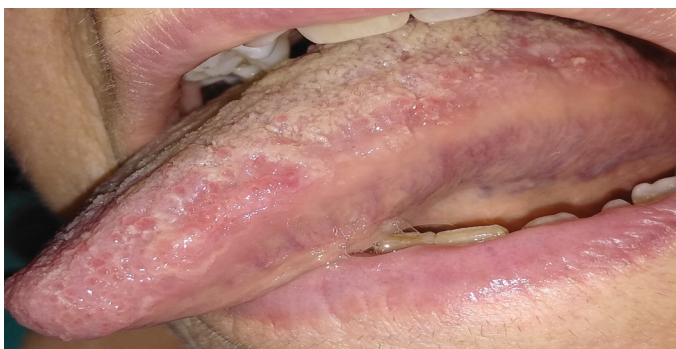

Figure 3) Migratory glossitis

squamous epithelium posteriorly, which is directly attached to the underlying muscle, while the underlying lamina propria is composed of dense fibrous connective tissue with numerous vessels and nerves supplying papillae (14). At the diagnosis the length of filiform papillae in BHT is >3 mm while the normal length is <1 mm (15). Some studies showed a prevalence of BHT of 40% in patients over 60 years old (16). Patients with oncological disorders, smokers, HIV-positive patients, edentulous patients and those with poor oral hygiene are most involved (4). Although casual smoking poses a slightly increased risk of having BHT compared to non-smokers (15% to 10% in men, 5.5% to 5.2% in women), habitual use of tobacco leads to estimated prevalence of 58% in men and 33% in women; also the excessive black tea consumption lead to increased prevalence of BHT in both male and female patients (17).

Alcohol and intravenous drug use, excessive coffee consumption, poor oral hygiene, general debilitation, and recent radiation therapy to the head and neck region are important risk factors that predispose some patients to develop BHT; also prolonged use of oxidizing mouthwashes containing sodium perborate, sodium peroxide, and hydrogen peroxide has also been associated with the development of BHT (7).

Two other risk factors for the development of BHT are pureed diets and conditions causing dry mouth. Soft or pureed diets with less roughage, as in edentulous patients, are less likely to desquamate the dorsal tongue than rough or textured foods and therefore lead to keratin retention (3). In addition to this, several studies have been demonstrated that lots of drugs are associated with an increased risk for the development of BHT. Specifically, antibiotics such as penicillin, erythromycin, doxycycline, linezolid, and neomycin are documented in the literature (3,18).

The study of Thompson et al has reported a strong evidence for antibiotic-induced BHT, of 22 cases, 18 (82%) involved antibiotics. For example, in this study of four cases of penicillin-induced BHT, two of the cases involved patients taking penicillin lozenges and two involved administering penicillin aerosol and has been reported that both of these dosage forms can result in prolonged contact of the antibiotic with the oral cavity (5). In addition, another important class of drugs implicated in drug-induced BHT includes those that can cause xerostomia, such as anticholinergic, antidepressant, and antihypertensive agents, moreover is frequently seen in patients undergoing radiation therapy, particularly to the head and neck region. The mechanism of drug induced BHT is not known. Moreover, antibiotics can alter the flora of the oral cavity and this play an important role in the development of BHT. Although, very rarely, another study of Braggio et al, reports a quite uncommon case of Linezolid-induced BHT in a patient with a long-lasting history of chest wall infection (19).

In this study microbiological examinations revealed the presence of *Staphylococcus Haemolyticus* and *Enterococcus Faecalis* and the therapy provided oral antibiotic for 2 months, but without benefit. For this reason it was started an antibiotic therapy with linezolid and two weeks later the patient showed tongue black discoloration with elongated filiform papillae. After that the linezolid was discontinued, the tongue returned normal after 2 weeks. Linezolid-induced BHT is an uncommon, benign, self-limiting disorder that has been rarely previously reported, but it might induce BHT (19).

Migratory glossitis has an association with psoriasis: due to similarities in clinical, histopathologic and immunohistochemical findings, few researchers consider geographic tongue as an oral manifestation of psoriasis (20). Histopathological, similarity may support the hypothesis that GT may be considered as an expression of oral psoriasis. A case-control study in India examined 600 adult patients with psoriasis and revealed a strong association between psoriasis and GT. Authors concluded that GT more frequently affects males and those patients with severe psoriasis (21). Psychological factors, such as stress, may represent a potentially modifiable risk factor that could influence the frequency of recurrence of GT in adults (22).

Stooper et al, in their clinical observation suggested that these factors may be associated with GT even in the paediatric population similar to the adult population (23). Ebrahimi et al, demonstrated the association between the stress and geographic tongue. They also found that decreasing stress in geographic tongue patients can be helpful in healing the lesions (24). Wysocky and Daley found association between the geographic tongue and diabetes and found fourfold increase in the prevalence of geographic tongue in diabetic patients. They found a prevalence of 8% in type 1 diabetic patients (25). On the contrary, Guggenheimer et al, reported no significant correlation between geographic tongue and insulin dependent diabetes mellitus (26). Allergy has also been suggested as an etiologic factor in geographic tongue (27).

A relation between geographic tongue and asthma, eczema, hay fever, elevated immunoglobulin E (IgE) serum level and atopic patients was also reported. It is a common lesion in patients that present recurrent acute inflammatory conditions. Psychosomatic factors, which probably contribute to both geographic tongue and atopy, may explain the high prevalence in atopic patients (28,29). Some studies demonstrate that hypertension or hypertensive medications are factors associated with

GT (30). The normal tongue structure, which is characterized by the presence of papillae, creates a niche in which mechanical retention of bacteria is facilitated by the papillae, reducing the risk of bacteria being flushed away by the saliva. However, the most striking feature of GT is the loss of the filiform papillae. Therefore, it is possible that the niches provided by the papillae are lost in GT. Consequently, the normal ecology of the tongue is changed and, as a direct consequence, the immune system is induced to initiate inflammation. It has been shown that the changes in microbial diversity underlie the dramatic and rapid increases in chronic inflammatory and autoimmune disorders seen in high-income countries. Increasing evidence suggests that periodontal diseases represent dysbiotic states of the oral microbiome (31). Most of the literature indicates a prevalence of 10-20% of ST in the population although there is a marked variation.

Degrees of severity and number of individuals involved increase according to age and gender, more frequent in males than females, and smoking also exerts a predisposing factor (12). Establishing a system of classification of the ST allows evaluating the correlation with the systemic health and the association with the various systemic disorders as these disorders could be diagnosed previously identifying the ST at an early age (32).

The basis for the classification of the degrees of ST is represented by the location of the fissures along the median, lateral and at the edges of the tongue. The slots can be arranged longitudinally and transversely and can be ramified and diffused (3,7). ST may be, in some cases, a symptom of Melkersson Rosenthal syndrome, a rare neuro-mucocutaneous systemic granulomatous disease characterized by recurrent peripheral facial paralysis, facial gold edema and ST. The etiology of the disease is not yet well known, but a role played by infectious diseases, genetic causes, allergic conditions, benign lymphogranulomatoses, and various associations with food contact allergies has been hypothesized (33,34).

The GT language and ST are more common in patients with psoriasis than in the general population. GT is more common in early-onset psoriasis and is associated with the severity of the disease. ST is more common in late psoriasis. The oral examination should be performed routinely in the evaluation of systemic diseases (33). In elderly patients, different lesions tend to develop more rapidly and more frequently due to reduced immune response, decreased DNA repair capacity and age-related atrophy of oral tissues, particularly mucosal and salivary glands (12). ST can also occur in oncological patients following chemo and radiotherapy.

CONCLUSION

In the scientific literature, correlations between migrant glossitis, villous and scrotal tongue and various systemic pathologies have been found. In particular, the association between GT and psoriasis, diabetes, hypertension was seen; between villous tongue and tumors, radiant therapies; between scrotal tongue, fungal infections and Merkeson-Rosenthal syndrome. Although an association between elevated IgE and migrant glossitis has been documented, associations between the three lingual conditions and the presence of allergy are unclear. No association was found with the reduction of calcium levels. In the light of these important correlations, a concrete objective anamnestic collection of oral pre-therapy conditions should constitute an essential parameter in the multi-level therapeutic protocols of patients with systemic co-morbidities.

REFERENCES

1. Bai YD, Sankarapandian S, Aditi R. A wide spread red lesion on the surface of the tongue-a case report and review of differential diagnosis. J Clin Diagn Res. 2017;11(6):ZD07-9.
2. Mangold AR, Torgerson RR, Rogers RS. Diseases of the tongue. Clin Dermatol. 2016;34(4):458-69.
3. Schlager E, Claire C, Ashack K, et al. Black hairy tongue: predisposing factors, diagnosis, and treatment. Am J Clin Dermatol. 2017;18(4):563-9.
4. Jhaj R, Gour PR, Asati DP. Black hairy tongue with a fixed dose combination of olanzapine and fluoxetine. Indian J Pharmacol. 2016;48(3):318-20.
5. Thompson DF, Kessler TL. Drug-induced black hairy tongue. Pharmacotherapy. 2010;30(6):585-93.
6. Gurvits GE, Tan A. Black hairy tongue syndrome. World J Gastroenterol. 2014;20(31):10845-50.
7. Nisa L, Giger R. Black hairy tongue. Am J Med. 2011;124:816-17.
8. Jahanbani J, Sandvik L, Lyberg T, et al. Evaluation of oral mucosal lesions in 598 referred Iranian patients. Open Dent J. 2009;3:42-7.
9. Madani FM, Kuperstein AS. Normal variations of oral anatomy and common oral soft tissue lesions. Evaluation and management. Med Clin North Am. 2014;98:1281-98.
10. Pinto A, Haberland CM, Baker S. Paediatric soft tissue oral lesions. Dent Clin North Am. 2014;58:437-53.
11. Chaubal T, Bapat R. Geographic tongue. Am J Med. 2017;130(12):e533-34.
12. Feil ND, Filippi A. Frequenci of fissured tongue (*lingua plicata*) as a function of age. Swiss Dent J. 2016;126(10):886-97.
13. Jarvinen J, Mikkonen JJW, Kullaa AM. Fissured of tongue edema? Medical Hypoteses. 2014;82(6):709-12.

14. Gurvits GE, Tan A. Black hairy tongue syndrome. World J Gastroenterol. 2014;20(31):10845-50.
15. Pigatto PD, Spadari F, Meroni L, et al. Black hairy tongue associated with long-term oral erythromycin use. J Eur Acad Dermatol Venereol. 2008;22(10):1269-70.
16. Korber A, Voshege N. Black hairy tongue in an infant. CMAJ. 2012;184(1):68.
17. Thompson DF, Kessler TL. Drug-induced black hairy tongue. Pharmacotherapy. 2010;30(6):585-93.
18. Abdollahi M, Rahimi R, Radfar M. Current opinion drug-induced oral reactions: a comprehensive review. J Contemp Dent Pract. 2008;9(3):1-15.
19. Braggio C, Bocchialini G, Ventura L, et al. Linezolid-induced black hairy tongue. Acta Biomed. 2018;89(3):408-10.
20. Picciani BL, Domingos TA, Teixeira-Souza T, et al. Geographic tongue and psoriasis: clinical, histopathological, immunohistochemical and genetic correlation: a literature review. An Braz Dermatol. 2016;91(4):410-21.
21. Singh S, Nivash S, Mann BK. Matched case-control study to examine association of psoriasis and migratory glossitis in India Indian J Dermatol Venereol Leprol. 2013;79:59-64.
22. Alikhani M, Khalighinejad N, Ghalaiani P, et al. Immunologic and psychological parameters associated with geographic tongue. Oral Surg Oral Med Oral Pathol Oral Radiol. 2014;118:68-71.
23. Stoopler ET, Jaisri RT, Sollectio TP. Psychological parameters associated with geographic tongue: a clinical observation. Oral Surg Oral Med Oral Pathol Oral Radiol. 2015;119(1):122-03.
24. Ebrahimi H, Pourshahidi S, Tadbir AA, et al. The relationship between geographic tongue and stress. Iran Red Crescent Med J. 2010;12(3):313-05.
25. Wysocki GP, Daley TD. Benign migratory glossitis in patients with juvenile diabetes. Oral Surg Oral Med Oral Pathol. 1987;63:68-70.
26. Guggenheimer J, Moore PA, Rossie K, et al. Insulin dependent diabetes mellitus and oral soft tissue pathologies. I. prevalence and characteristics of non-candidal lesions. Oral Surg Oral Med Oral Pathol Endod. 2000;89:563-09.
27. Ishibashi M, Tojo G, Watanabe M, et al. Geographic tongue treated with topical tacrolimus. J Dermatol Case Rep. 2010;4:57-9.
28. Miloglu O, Goregen M, Akgul HM, et al. The prevalence and risk factors associated with benign migratory glossitis lesions in 7619 Turkish dental outpatients. Oral Surg Oral Med Oral Pathol Oral Radiol Endod. 2009;107:e29-33.
29. Scariot R, Batista TB, Olandoski M, et al. Host and clinical aspects in patients with benign migratory glossitis. Arch Oral Biol. 2017;73:259-68.
30. Dafar A, Cevik-Aras H, Robledo-Sierra J, et al. Factors associated with geographic tongue and fissured tongue. Acta Odontol Scand. 2016;74(3):210-6.
31. Dafar A, Bankvall M, Cevik-Aras H, et al. Lingual microbiota profiles of patients with geographic tongue. J Oral Microbiol. 2017;9(1):1355206.
32. Sudarshan R, Vijayabala GS, Samata Y, et al. Newer classification system for fissured tongue: an epidemiological approach. J Trop Med. 2015;2015:262079.
33. Gaudio A, Corrado A, Santoro N, et al. Melkersson-Rosenthal syndrome in a patient with psoriatic arthritis receiving etanercept. Int J Immunopathol Pharmacol. 2013;26(1):229-33.
34. Picciani BL, Souza TT, Santos VC, et al. Geographic tongue and fissured tongue in 348 patients psoriasis: correlation with disease severity. Scientific World Journal. 2015;2015:56432.