

Four communications between median and musculocutaneous nerves

Published online November 28th, 2010 © http://www.ijav.org

Lovesh SHUKLA ⁺
Gargi SONI
Neha GAUR

Department of Anatomy, Maharaja Agrasen Medical College, Agroha, Hisar (Haryana), INDIA.



⁺ Dr. Lovesh Shukla
Professor
Department of Anatomy
Maharaja Agrasen Medical College
Agroha-125047
Hisar (Haryana), INDIA.
☎ +91 1869 281781
✉ drlovesh@gmail.com

Received April 12th, 2010; accepted October 31st, 2010

ABSTRACT

The present article is in reference to a case, encountered in routine dissection, displaying four sites of communication between the musculocutaneous and the median nerves, whereas in the literature not more than two communications have been reported. © IJAV. 2010; 3: 186–187.

Key words [musculocutaneous nerve] [median nerve] [communication]

Introduction

Communications between the branches of brachial plexus is a common phenomenon and it has several clinical and surgical implications. The aim of this paper is to report a rare finding of four communications between the musculocutaneous nerve (MCN) and the median nerve (MN) in the arm, which may provide additional information for the classification of communications between the MCN and MN, as described by the earlier workers [1–3]. This would enable us to have better knowledge of the field during surgery to avoid neurological damages.

Case Report

During routine dissection of right upper limb in a 55-year-old male cadaver, it was observed that MCN did not pierce the coracobrachialis muscle (CBM). MCN gave a branch to CBM and distal to this branch, four communicating branches between MCN to MN were seen (Figure 1). All the communications were from MCN to MN. The distance of each communication from the tip of the coracoid process was measured and it was found to be 5.5 cm, 6.0 cm, 6.1 cm and 8.1 cm. The corresponding lengths of these communications from proximal to distal were 3.5 cm, 1.9 cm, 1.5 cm and 1.1 cm, respectively. Further course and relations of MCN were found to be without any variation.

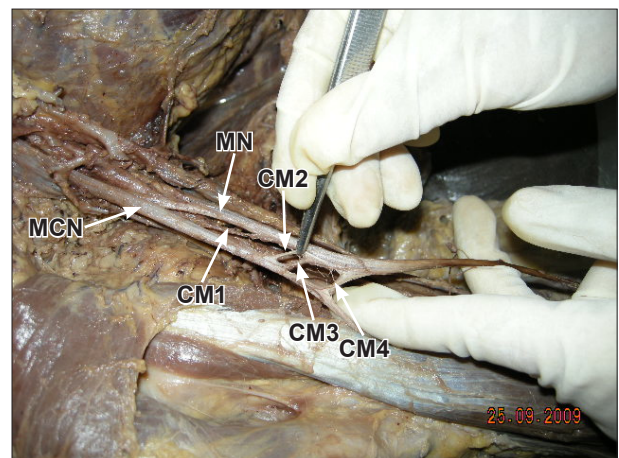


Figure 1. Photograph of the right upper limb showing four communications between musculocutaneous and median nerves. (MCN: musculocutaneous nerve; MN: median nerve; CM: communication)

Discussion

In the earlier studies done on communications between MCN and MN, a maximum of two communications have been reported [3,4]. In the present case four communications were seen, which is a rare case finding and has not been included in any of the classifications given by the earlier workers [1–3]. Le Minor has classified

the variations of MCN and MN into five types [1]. In Type I, there are no connecting fibers between the MCN and MN as described in classic textbooks. The MCN pierces the CBM and innervates it, and also the biceps brachii and brachialis muscles. In Type II, although some fibers of the medial root of the MN unite with the lateral root of the MN to form the main trunk of MN, remaining medial root fibers run in the MCN leaving it after a distance to join the main trunk of MN. In Type III, the lateral root of the MN from the lateral cord runs in the MCN and leaves it after a distance to join the main trunk of MN. In Type IV, the fibers of the MCN unite with the lateral root of the MN. After some distance, the MCN arises from the median nerve. In Type V, the MCN is absent. The fibers of the MCN run within the MN along its course. In this type the MCN does not pierce the CBM. Veinreros and Anagnostopoulou studied 79 cadavers and found communications between MCN and MN in 22 cadavers [2]. They reported the following three types of communications between MCN and MN, in relation to CBM. In Type I: the communication was proximal to the entrance of the MCN into the CBM (9/22); in Type II: the communication was distal to the muscle (10/22) and in Type III: the nerve as well as the communicating branch did not pierce the muscle (3/22). So, according to this classification the present case falls into Type III where neither the nerve nor the communicating branch pierces the CBM, but in the present case four such communicating branches were found. In a recent study by Choi et al., such communications have been broadly classified into three types [3]. In type I: the MCN and MN were fused; in type II: there was one connecting branch between the MCN and MN and in type III: two

connecting branches were present between the MCN and MN. So, the present case does not fall into any of the above-mentioned categories. Therefore, we strongly feel the need to modify the existing classifications of Veineratos and Anagnostopoulou [2] or the classification given by Choi et al [3]. To the classification given by Veineratos and Anagnostopoulou [2], a new pattern may be added as Type IV: both the MCN and more than one communicating branch did not pierce the CBM. To the classification given by Choi et al. [3], a new pattern may be added as Type IV: there are more than one communicating branches and none of the communicating branches nor MCN pierce the CBM.

Significant variations in nerve patterns may be the result of altered signaling between mesenchymal and neuronal growth cones [5] or circulatory factors at the time of fusion of brachial plexus cords [6]. The presence of such nerve communications are not just confined to man, studies on comparative anatomy have reported the existence of such connections in monkeys and in some apes. Thus suggesting that communications may represent the primitive nerve supply of anterior arm muscles [7].

These variations have clinical importance in post-traumatic evaluations and exploratory interventions of the arm for peripheral repair. The knowledge of the possible communications between musculocutaneous and median nerves is also important in the anterior approach for the fracture of the humerus and regional nerve blocks.

Acknowledgement

We thank Dr. Usha Dhall Senior Professor of Anatomy for her assistance in the preparation of this paper.

References

- [1] Le Minor JM. A rare variation of the median and musculocutaneous nerves in man. *Arch Anat Histol Embryol.*1990; 73: 33–42. (French)
- [2] Veineratos D, Anagnostopoulou S. Classification of communications between the musculocutaneous and median nerves. *Clin Anat.*1998; 11: 327–331.
- [3] Choi D, Rodriguez-Niedenfuhr M, Vazquez T, Parkin I, Sanudo JR. Patterns of connections between the musculocutaneous and median nerves in the axilla and arm. *Clin Anat.* 2002; 15: 11–17.
- [4] Yang ZX, Pho RW, Kour AK, Pereira BP. The musculocutaneous nerve and its branches to the biceps and brachialis muscles. *J Hand Surg Am.* 1995; 20: 671–675.
- [5] Kosugi K, Morita T, Koda M, Yamashita H. Branching pattern of the musculocutaneous nerve. 1. Case possessing normal biceps brachii. *Jikeikai Med J.* 1986; 33: 63–71.
- [6] Sanes HD, Reh TA, Harris WA. Development of the nervous system. 1st Ed. New York, Academic Press. 2000; 189–197.
- [7] Miller RA. Comparative studies upon the morphology and distribution of the brachial plexus. *Am J Anat.*1934; 54: 143–175.