



# Double precaval right renal artery associated with multiple left renal arteries: a rare case report

Published online July 7th, 2011 © <http://www.ijav.org>

Anupma GUPTA  
Parveen KUMAR  
Gargi SONI  
Lovesh SHUKLA †

Department of Anatomy, Maharaja Agrasen Medical College, Agroha, Hisar, Haryana, INDIA.



† Dr. Lovesh Shukla  
Professor and HOD  
Department of Anatomy  
Maharaja Agrasen Medical College  
Agroha-125047, Hisar, Haryana, INDIA.  
☎ +91 1669-281761  
✉ [drlovesh@gmail.com](mailto:drlovesh@gmail.com)

Received October 10th, 2010; accepted June 24th, 2011

## ABSTRACT

The present article is in reference to a case, encountered in routine dissection, displaying two precaval right renal arteries with a superior pole extra-hilar branch associated with four left renal arteries, second of which reaches the superior pole of left kidney, while the other three reach the hilum. © IJAV. 2011; 4: 137–138.

**Key words** [renal artery] [precaval renal artery] [multiple renal arteries]

## Introduction

Variation in number of renal arteries is though quite common [1] but is important to recognize to avoid any complications during surgical and radiological procedures. Right renal arteries are described passing posterior to the inferior vena cava, whereas in this case two right renal arteries passed anterior to inferior vena cava. Such variations are important in the diagnosis of ureteropelvic obstruction [2], minimum invasive surgeries [3] and renal transplantation [4]. In the present case we not only found two right precaval renal arteries but also four left renal arteries, these findings increase the rarity of this report.

## Case Report

During routine dissection of a male cadaver, nearly 45-year-old, we observed variations in the number of the right renal artery (RRA) and left renal artery (LRA).

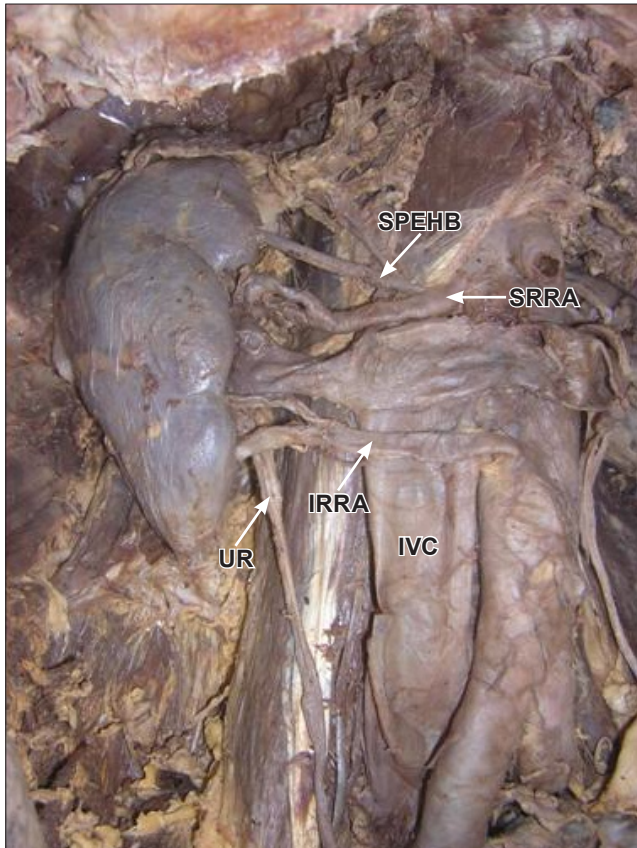
The right kidney was found to receive two RRA, superior and inferior, both arising from abdominal aorta, from it is lateral and ventral aspects, respectively; and both were reaching the hilum of right kidney (right hilar arteries) after crossing the inferior vena cava from its anterior aspect (precaval RRA). The superior right hilar artery gave a branch to the upper pole of the right kidney (superior pole extra-hilar branch). The inferior precaval RRA reached the hilum of

right kidney after crossing the ureteropelvic junction, from its anterior aspect (Figure 1).

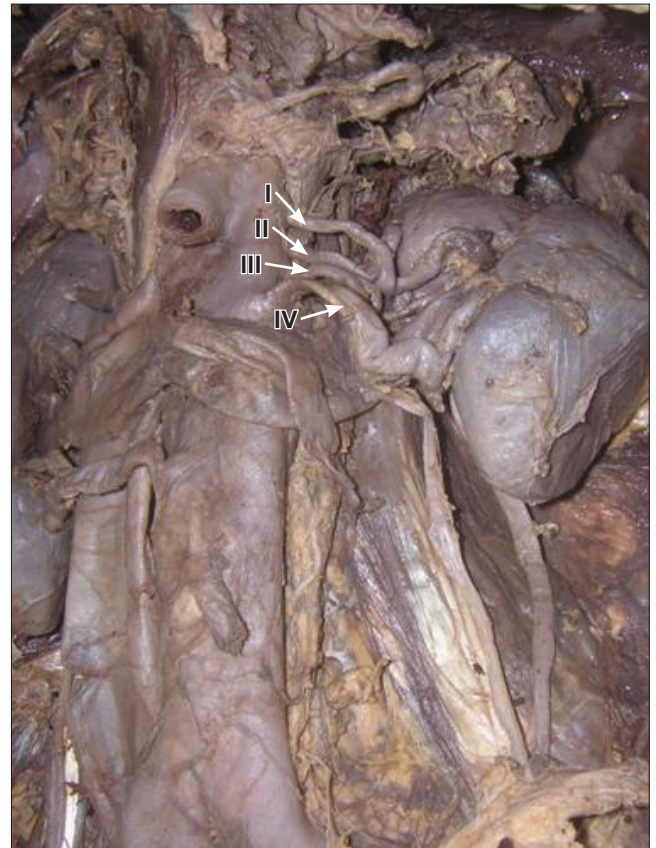On the other hand, the left kidney was found to receive four LRA; upper three were arising from lateral side of abdominal aorta while lowest one arising from ventral aspect of abdominal aorta. From superior to inferior, first, third and last LRA were reaching the hilum of left kidney. However, the second LRA was reaching the superior pole of left kidney (superior pole LRA) after crossing the first LRA from its posterior aspect (Figure 2).

## Discussion

The prevalence of RRA has been reported to be 0.8%, where 380 patients were evaluated using CT [5]. However, Yeh et al. described presence of precaval right arteries in nine of 186 patients by using spiral CT, and reported the prevalence rate to be 5% [6]. The frequency of renal artery variations shows social, ethnic and racial differences [1]. Sampaio and Passos, in their cadaveric study on 266 kidneys described presence of two hilar arteries with one superior pole extra-hilar branch, in 3.4% cases (9/266), irrespective of side [7]. This finding is similar to our finding on the right side, where the RRA are precaval and have a similar pattern. They also described the prevalence of 4 renal arteries (two hilar arteries and one superior pole artery and one inferior polar



**Figure 1.** Photograph showing right kidney. (*SPEHB*: superior pole extra-hilar branch; *SRRA*: superior right renal artery; *IRRA*: inferior right renal artery; *UR*: ureter; *IVC*: inferior vena cava)



**Figure 2.** Photograph showing left kidney with four renal arteries. (*I*: left renal artery-1; *II*: left renal artery-2; *III*: left renal artery-3; *IV*: left renal artery-4)

artery) in 0.4% of cases (1/266), irrespective of side [7]. In the present case, we also found 4 LRA; the second LRA was reaching the superior pole of left kidney. The variations in both right and left renal arteries make this case unique,

thus we conclude that the renal vascular anatomy should be studied in a large sample size to find the prevalence of such variations in the Indian population.

## References

- [1] Kadir S. Atlas of normal and variant angiographic anatomy. Philadelphia, W. B. Saunders Company. 1991; 387–429.
- [2] Corey S, Bechtold R, Dyer R. Radiological case of the month: ureteropelvic junction: diagnosis and imaging findings. *Applied Radiology*. 2005; 34: 33–37.
- [3] Bush WH, Brannen GE, Lewis GP. Ureteropelvic junction obstruction: treatment with percutaneous endopyelotomy. *Radiology*. 1988; 171: 535–538.
- [4] Brannen GE, Bush WH, Correa RJ Jr, Gibbons RP, Cumes DM. Microvascular management of multiple renal arteries in transplantation. *J Urol*. 1982; 128: 112–115.
- [5] Ozkan U, Dügüzkurt I, Tercan F, Kizilkiliç O, Koç Z, Koca N. Renal artery origins and variations: angiographic evaluation of 855 consecutive patients. *Diagn Interv Radiol*. 2006; 12: 183–186.
- [6] Yeh BM, Coakley FV, Meng MV, Breiman RS, Stoller ML. Precaval right renal arteries: prevalence and morphologic associations at spiral CT. *Radiology*. 2004; 230: 428–433.
- [7] Sampaio FJ, Passos MA. Renal arteries: anatomic study for surgical and radiological practice. *Surg Radiol Anat*. 1992; 14: 113–117.