



## Discovery of a novel variant of the stylocondrohyoideus muscle

Published online December 14th, 2010 © <http://www.ijav.org>

H. Wayne LAMBERT<sup>[1,2]</sup> ✦  
 Stavros ATSAS<sup>[1,2]</sup>  
 Taylor A. DAYTON<sup>[1,3]</sup>

Department of Neurobiology and Anatomy, West Virginia University School of Medicine, Robert C. Byrd Health Sciences Center, Morgantown, West Virginia [1], Department of Anatomical Sciences and Neurobiology, University of Louisville Health Sciences Center, Louisville, Kentucky [2], Department of Biochemistry, Virginia Polytechnic Institute and State University, Blacksburg, Virginia [3], USA.



✦ Dr. H. Wayne Lambert, PhD  
 Associate Professor  
 West Virginia University School of Medicine  
 Robert C. Byrd Health Sciences Center  
 Department of Neurobiology and Anatomy  
 HSN 4052; P.O. Box 9128  
 Morgantown, 26506-9128, WV, USA.  
 ☎ +1 (304) 293-0610  
 ✉ [wlamber1@hsc.wvu.edu](mailto:wlamber1@hsc.wvu.edu)

Received August 6th, 2010; accepted December 6th, 2010

### ABSTRACT

During routine dissection of the suprahyoid region, a duplicate stylohyoid muscle was found in a 65-year-old Caucasian female. This variant muscle arose from the base of the styloid process before proceeding to envelope and insert upon the stylohyoid ligament. While other authors have reported the presence of a stylocondrohyoideus muscle which replaced the stylohyoid ligament or inserted into the stylohyoid ligament distally, this case study presents the first reported finding of a muscle completely enveloping the stylohyoid ligament proximally and then inserting directly into the ligament itself. Due to its association with the stylohyoid ligament, this muscle is being classified as a new variant of the stylocondrohyoideus muscle. This paper also attempts to resolve the nomenclature discrepancies associated with duplicate stylohyoid muscles. © IJAV. 2010; 3: 197–199.

**Key words** [stylocondrohyoideus] [variant stylohyoid muscle] [stylohyoid ligament] [stylohyoideus profundus] [anatomical variation]

### Introduction

The stylohyoid muscle extends from the base of the styloid process of temporal bone and ends by inserting itself into the body of the hyoid bone, in proximity to the origin of its greater horn, or cornu. In concert with the posterior belly of the digastric muscle, which parallels its course, the suprahyoid muscle functions to fix the hyoid bone, and subsequently the base of the tongue, during swallowing (deglutition) and to elevate and retract the hyoid during mastication, inhalation, exhalation, and speaking [1]. Within the scope of its functions, the stylohyoid muscle has been observed to have a wide range of incarnations within the human body as its orientation, structure, and presence have been shown to vary within sample populations [1,2].

Mori cited three distinct variations in the relationship of the stylohyoid muscle to the intermediate tendon of the digastric muscle and reported their respective prevalence based upon 254 dissections [3]. During its course, the stylohyoid muscle passes medial to the intermediate tendon of the digastric muscle in 70.1% of cases. Diametrically, the stylohyoid muscle passes lateral to the same tendon in 1.9% of 254 dissections, which was initially reported by German anatomist Samuel Thomas von Sömmerring [2,3]. Finally, in 27.9% of cases, the stylohyoid muscle divided into two parts, enveloping the intermediate tendon of the digastric muscle [3,4].

In further accounts of variation, the stylohyoid muscle has been observed to be entirely absent, present in a

unilateral capacity, or present in a duplicate or triplicate fashion [1,2,4,5]. Macalister cited work by Hallet and Bohmer in 1702 for recording a complete absence of the stylohyoid muscle [2]. Macalister also credited Hallet with describing the unilateral absence of the stylohyoid muscle occurring approximately “once in two hundred cases” [2]. Moreover, Humphry stated that stylohyoid muscle is “not unfrequently absent on one or both sides” and has been called “almost supererogatory” [1]. Conversely, the literature presents a plethora of duplicate stylohyoid muscles with disparate arrangements and terminology. If a second stylohyoid muscle is present and maintains the same origin, course, and insertion as the original stylohyoid muscle, it is predominantly called the stylohyoideus profundus (or deep stylohyoid), a term credited to French anatomist Marie Philibert Constant Sappey [4,5]; however, renowned anatomist Bernhard Siegfried Albinus termed it the “stylohyoideus alter”, or second stylohyoid muscle [6], while Italian anatomist Giovanni Domenico Santorini called it the “stylohyoideus novus”, or new stylohyoid muscle [4]. The presence of a stylohyoideus profundus muscle was cited by Bartolomeo Eustachius, Govard Bidloo, Giovanni Domenico Santorini in 1724, Caspar Wistar in 1823, Albinus, Lawson Tait, and Macalister in his personal dissections [2,7]. Finally, Wenzel Leopold Gruber, a Russian anatomist, documented a triplicate stylohyoid muscle in 1848 [1,2].

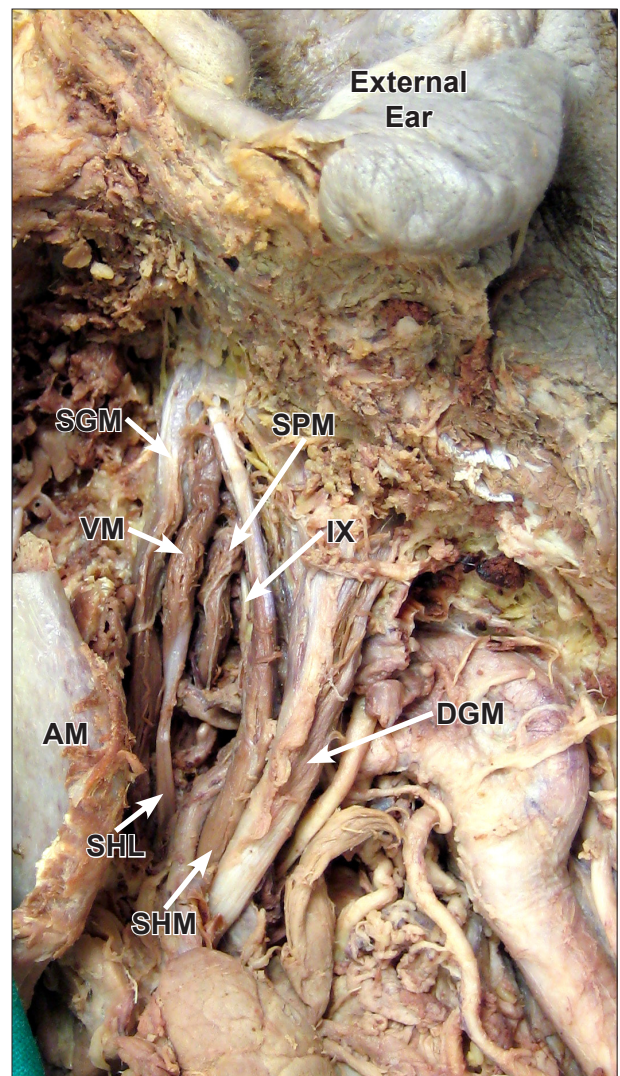
Scottish anatomist James Douglas is credited with the eponym associated with the stylocondrohyoideus muscle, yet another variation of a duplicate stylohyoid muscle [4]. Schafer et al. described the stylocondrohyoideus muscle as a “muscular slip...passing from the styloid process to the lesser cornu of the hyoid bone, accompanying or replacing the stylo-hyoid ligament” [8]. This muscle has been shown to accompany the stylohyoid ligament [9], but other documentations of this muscle by Santorini and French anatomist Hyacinthe Gavard fail to discuss its relationship to the stylohyoid ligament [2]. Replacement of the stylohyoid ligament by an “elegant small muscle” was described by British anatomist James Drake, German anatomist Josias Weitbrecht, French anatomist Philippe Frederic Blandin, and Macalister [2]. In 1950, Wang reported bilateral “accessory stylohyoidei” muscles in one cadaver specimen which replaced the stylohyoid ligament on the right side, but accompanied the stylohyoid ligament on the left side [10]. Due to their insertion into the lesser horns of the hyoid bone and association with the stylohyoid ligaments, these muscles would be called stylocondrohyoidei muscles in the current nomenclature. More recently, Joshi et al. confirmed the replacement of the ligament by the stylocondrohyoideus muscle [11]. This study curiously described this bilateral muscle as “not a variant of the stylohyoid muscle”, but it may be more accurate to state this muscle is not a variant of the stylohyoid profundus [11]. The literature creates some confusion when authors use the terms stylocondrohyoideus, stylohyoideus profundus, and accessory stylohyoideus synonymously [4,5,10].

#### Case Report

During routine dissection of the suprahyoid muscles of a 65-year-old Caucasian female in an anatomy laboratory at the University of Louisville’s School of Medicine, a variant muscle associated with the stylohyoid ligament was observed on the left side. This muscle arose from the lateral aspect of the base of the styloid process of the temporal bone and deep to the origins of the stylohyoid and styloglossus muscles. It completely enveloped the proximal aspect of the stylohyoid ligament and inserted into this ligament distally. The stylohyoid ligament inserted onto the lesser horn of the hyoid bone. The total length of this muscle-ligament complex was 7.5 cm. The muscle belly itself was 3.7 cm in length with its circumference being 1.2 cm at its widest point (Figure 1).

#### Discussion

Numerous studies have identified duplicate stylohyoid muscles, and their content highlights the controversy that exists over the nomenclature of these muscles. The variant muscle found in this study was associated with the stylohyoid ligament, so it is not the stylohyoideus profundus [5]. Moreover, this muscle displayed characteristics of the stylocondrohyoideus muscle, especially because the dissected muscle-ligament complex has the same origin and insertion as the stylocondrohyoideus [8]. However, in this study, the variant muscle enveloped and inserted into the stylohyoid ligament itself, contradicting the description of the stylocondrohyoideus muscle



**Figure 1.** The cadaveric dissection of the variant muscle, a novel stylocondrohyoideus muscle, enveloping the proximal end of, and inserting into, the stylohyoid ligament. (SGM: styloglossus muscle; SPM: stylopharyngeus muscle; VM: variant muscle; IX: glossopharyngeal nerve; DGM: digastric muscle; SHM: stylohyoid muscle; SHL: stylohyoid ligament; AM: angle of mandible)

as “accompanying or replacing the stylo-hyoid ligament” [8]. In one Chinese cadaver, Wang reported stylocondrohyoidei muscles both accompanying and replacing the stylohyoid ligament, but he identified these muscles as “accessory stylohyoidei” [10]. Clearly, the nomenclature discrepancies concerning duplicate stylohyoid muscles make of the reported cadaveric findings tedious. However, the authors feel they have identified a new variant of the stylocondrohyoideus muscle, which completely envelops the stylohyoid ligament proximally and then inserts directly into the stylohyoid ligament itself.

Variation of the suprahyoid muscles are important to acknowledge, study, and understand because of their relevance in diagnostic studies and clinical landmarks [12]. In particular, variant suprahyoid muscles may be

confused for metastatic masses during radiologic imaging of the neck and may create difficulties in establishing surgical landmarks during functional neck dissections to investigate metastatic cervical lymph nodes [13]. Furthermore, variant suprahyoid muscles may induce or contribute to idiopathic facial, neck, and ear pain which overlap with other orofacial problems, such as myofascial and neuralgiform pain [14]. Another study suggests variant suprahyoid muscles may be vulnerable to injury

during trauma, such as acute stretch during whiplash injuries, [15]. Therefore, knowledge of variations in the suprahyoid region is crucial for clinicians.

#### Acknowledgements

The authors thank Dr. Ferrell R. Campbell for his help in the dissection of this cadaveric specimen as well as Bruce Palmer and Earl Ekstrom for figure preparation.

#### References

- [1] Humphry GM. Lectures on the varieties in the muscles of man. *Br Med J*. 1873; 1: 693–696.
- [2] Macalister A. The varieties of the styloid muscles. *J Anat Physiol*. 1870; 5: 28–31.
- [3] Mori M. Statistics on the musculature of the Japanese. *Okajimas Folia Anat Jpn*. 1964; 40: 195–300.
- [4] Bergmann RA, Thompson SA, Afifi AK, Saadeh FA. *Compendium of Human Anatomic Variation*. 1st Ed., Baltimore, Urban and Schwarzenberg. 1988; 67.
- [5] Dwight T, McMurrich JP, Hamann CA, Piersol GA, White JW. *Human Anatomy: Including Structure and Development and Practical Considerations*. 4th Ed., Philadelphia, J.B. Lippincott Company. 1913; 479–480.
- [6] Barclay J. *The Muscular Motions of the Human Body*. 1st Ed., Edinburgh, Laing and Constable. 1808; 3.
- [7] Tait L. Note on unusual accessory muscles. *J Anat Physiol*. 1870; 4: 236–238.
- [8] Schafer EA, Symington J, Bryce TH. *Quain's Elements of Anatomy*. 11th Ed., Vol. III., New York, Oxford University Press. 2000; 135.
- [9] Pye-Smith PH, Howse HG, Davies-Colley JNC. Notes on abnormalities observed in the dissection room during the winter sessions of 1868-9 and 1869-70. In: Fagge CH, Durham AE, eds. *Guy's Hospital Reports*. Vol. 18(3). London, J&A Churchill. 1871; 147–164.
- [10] Wang CM. An anomalous muscle in place of the stylohyoid ligament of a Chinese. *Anat. Rec*. 1950; 107: 375–378.
- [11] Joshi SD, Waghmode PS, Joshi SS. Bilateral presence of muscle 'Stylohyoid' - A rare anomaly. *J Anat. Soc. India* 2007; 56: 39-40.
- [12] Stark ME, Wu B, Bluth BE, Wisco JJ. Bilateral accessory cleidohyoid in a human cadaver. *International Journal of Anatomical Variations (IJAV)*. 2009; 2: 122–123.
- [13] Ozgursoy OB, Kucuk B. Unique variation of digastric muscle: a confusing landmark for head and neck surgeons. *Acta Otolaryngol*. 2006; 8: 881–883.
- [14] Ozgur Z, Govsa F, Celik S, Ozgur T. An unreported anatomical finding: Unusual insertions of the stylohyoid and digastric muscles. *Surg Radiol Anat*. 2010; 32: 513–517.
- [15] Palesy P, Murray GM, De Boever J, Klineberg I. The involvement of the styloid process in head and neck pain - a preliminary study. *J Oral Rehabil*. 2000; 27: 275–287.