



Connection between radial and ulnar nerves at high humeral level

Published online April 16th, 2010 © <http://www.ijav.org>

GuInur OZGUNER
Kadir DESDICIOLU
Soner ALBAY †

Suleyman Demirel University, Faculty of Medicine, Department of Anatomy, Isparta, TURKIYE.



† Soner Albay, MD
Assistant Professor
Suleyman Demirel University
Faculty of Medicine
Department of Anatomy
Isparta, 32260 TURKIYE.
☎ +90 246 2113302
✉ soneralbay@yahoo.com

ABSTRACT

Brachial plexus variations are not rare. Also variations in its terminal branches in the arm or forearm are frequently reported. During routine dissection of a 75-year-old male cadaver, we observed a connection between ulnar and radial nerves at high humeral level. We considered it as a rare variation. It is very important to know such variations to minimize the possible complications of regional anesthesia and surgery. © IJAV, 2010; 3: 49–50.

Key words [radial nerve] [ulnar nerve] [nerve communication]

Received December 15th, 2008; accepted April 15th, 2010

Introduction

Effective brachial plexus blockade requires a thorough understanding of the anatomy of the plexus, as well as an appreciation of anatomic variations that may occur [1]. Anomalies at the high humeral level of the brachial plexus may also present as a complicating factor during surgical attempt to nerve blockade. At high humeral levels the median nerve descends from the axilla in close proximity to the brachial artery, frequently lying just lateral to the artery. Likewise, the ulnar nerve remains close to the artery to this point and is especially found just medial to the artery. The radial nerve leaves the axilla posterior to the artery and passes deep to the long head of the triceps, proceeding distally around the humerus in the spiral groove [2]. In the previous studies the connections between terminal branches of the brachial plexus in the arm or forearm have been reported, and some of them presented the percentage of the connection [3-5]. There are few studies like our case, which were about connections between ulnar and radial nerves. In the previous studies, the connections were sensorial and they were on the dorsal or palmar aspect of the hand [6,7].

Case Report

During routine educational dissection of brachial plexus at our department, a 75-year-old male cadaver was dissected. The cause of death was cardiac arrest, and there was no trauma or surgical intervention on his upper

extremity. Brachial plexus and its terminal branches, axillary and brachial vessels were exposed.

In our case, there was a unilateral connection between ulnar and radial nerves at high humeral levels on the left arm (Figure 1). The connection was 6 cm long and 3 mm wide, it was lying anteromedial to distal of the axillary artery and proximal of the brachial artery. Rest of the terminal branches of the brachial plexus and axillar artery and vein were as usual.

Discussion

Brachial plexus variations are frequently reported. Uysal et al. dissected 200 brachial plexus in human fetuses, only 93 of the brachial plexuses showed no variations [8]. In other words, the variations of brachial plexus was observed in 53.5% of the cases. Choi et al. [3] have observed a communication between the median and musculocuteneus nerves in 46.4%; Loukas and Aqueelah [4] described same communication in 63%, Venieratos and Anagnostopoulou [5] observed in 20%. Communications between the median and ulnar nerves have also been reported. Kazakos et al. [9] observed this type of communication branch between median and ulnar nerves in 10 forearms of 163 cadavers.

Bergman et al. [10] reported possible communication between radial and ulnar nerves in the arm. However, a percentage value for the communications between radial and ulnar nerves on the arm or forearm is missing in the literature. On the other hand, dorsal sensorial branch

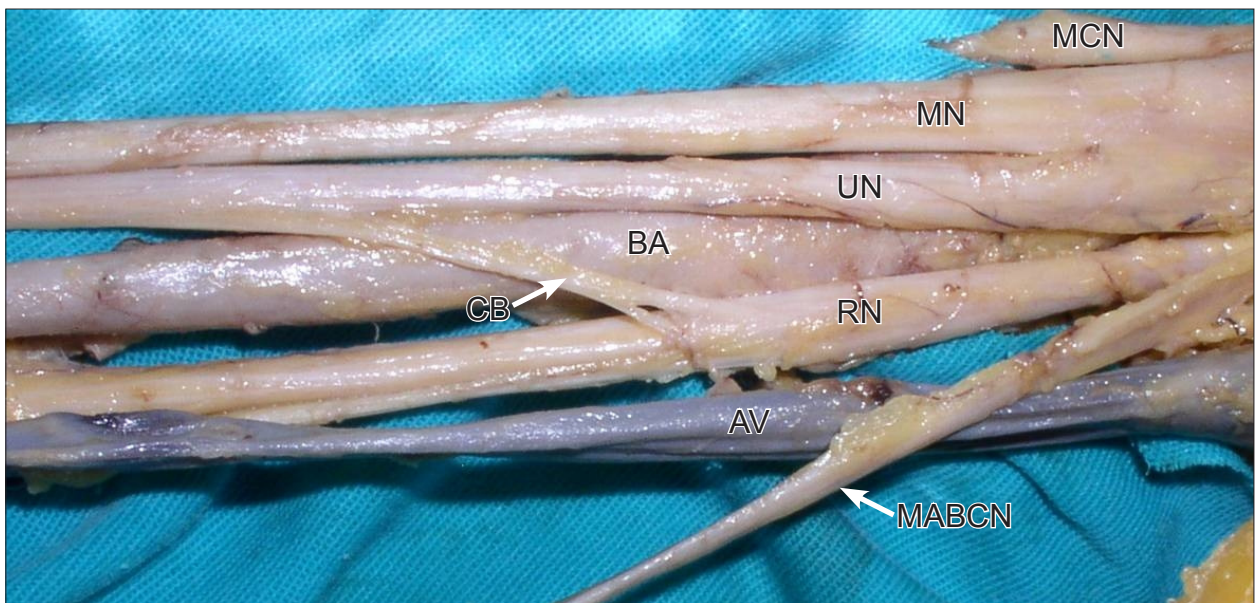


Figure 1. Figure showing the communicating branch between the ulnar and radial nerves. (MN: median nerve; RN: radial nerve; UN: ulnar nerve; CB: communicating branch; BA: brachial artery; MCN: musculocutaneous nerve; AV: axillary vein; MABCN: medial antebrachial cutaneous nerve)

communications between the radial and ulnar nerves (60%) on the dorsal surface of the hand [6], and radial nerve cutaneous innervation to the ulnar dorsum of the hand (16%) have been reported [7]. In our case, superficial structures on the hand have already been dissected and removed. Therefore, we could not observe any sensorial innervation in the hand. There was no unusual motor or sensorial innervation observed during the forearm dissection. It means that the type of the communicating branch might be probably sensorial.

Variant nerve communications may cause ineffective nerve blockade and also blockade of unexpected areas. During surgical procedure, such variations may lead to possible complications. Therefore, it is very important to know all variant communicating branches of brachial plexus for successful regional nerve blockade and operations.

References

- [1] Orebaugh SL, Williams BA. Brachial plexus anatomy: normal and variant. *ScientificWorldJournal*. 2009; 9: 300–312.
- [2] Stanesco S, Post J, Ebraheim NA, Bailey AS, Yeasting R. Surgical anatomy of the radial nerve in the arm: practical considerations of the branching patterns to the triceps brachii. *Orthopedics*. 1996; 19: 311–315.
- [3] Choi D, Rodriguez-Niedenfuhr M, Vazquez T, Parkin I, Sanudo JR. Patterns of connections between the musculocutaneous and median nerves in the axilla and arm. *Clin Anat*. 2002; 15: 11–17.
- [4] Loukas M, Aqueelah H. Musculocutaneous and median nerve connections within, proximal and distal to the coracobrachialis muscle. *Folia Morphol (Warsz)*. 2005; 64: 101–108.
- [5] Venieratos D, Anagnostopoulou S. Classification of communications between the musculocutaneous and median nerves. *Clin Anat*. 1998; 11: 327–331.
- [6] Loukas M, Louis RG Jr, Wartmann CT, Tubbs RS, Turan-Ozdemir S, Kramer J. The clinical anatomy of the communications between the radial and ulnar nerves on the dorsal surface of the hand. *Surg Radiol Anat*. 2008; 30: 85–90.
- [7] Leis AA, Wells KJ. Radial nerve cutaneous innervation to the ulnar dorsum of the hand. *Clin Neuropysiol*. 2008; 119: 662–666.
- [8] Uysal II, Seker M, Karabulut AK, Büyükmumcu M, Ziyilan T. Brachial plexus variations in human fetuses. *Neurosurgery*. 2003; 53: 676–684.
- [9] Kazakos KJ, Smyrnis A, Xarchas KC, Dimitrakopoulou A, Verettas DA. Anastomosis between the median and ulnar nerve in the forearm. An anatomic study and literature review. *Acta Orthop Belg*. 2005; 71: 29–35.
- [10] Bergman RA, Alifi AK, Miyauchi R. Radial nerve. *Illustrated Encyclopedia of Human Anatomic Variation: Opus III: Nervous System: Plexuses*. <http://www.anatomyatlases.org/AnatomicVariants/NervousSystem/Text/RadialNerve.shtml> (accessed december 2009).