



## Case Report

# Clinically significant variations of the cords of the brachial plexus in relation to axillary artery

Published online January 18th, 2011 © <http://www.ijav.org>Jamuna M <sup>+</sup>

Department of Anatomy, PSG Institute of Medical Sciences and Research, Coimbatore, Tamilnadu, INDIA.



<sup>+</sup> Dr. Jamuna M, MS  
Associate Professor  
Department of Anatomy  
PSG Institute of Medical Sciences and Research  
Peelamedu, Coimbatore  
Tamilnadu, INDIA.  
☎ +91 944 97 97588  
✉ [drjamunam@gmail.com](mailto:drjamunam@gmail.com)

Received July 16th, 2010; accepted January 4th, 2011

### ABSTRACT

Variations in the formation, course and distribution of brachial plexus are common and are well documented, but the variation of the cords of brachial plexus in relation to axillary artery is rarely documented. Here a rare variation of the cords of brachial plexus and the branches of the cords in relation to the axillary artery in the right upper limb of an adult male cadaver is reported. The lateral, medial and posterior cords were present lateral to the axillary artery and all the branches of the cords were also present lateral to the axillary artery. The musculocutaneous nerve was found not piercing the coracobrachialis muscle. The clinical significance and the embryological reasons are discussed. Clinicians and surgeons should be aware of such variations while performing surgical procedure in the axilla as the nerves are more prone for injury. © IJAV. 2011; 4: 9-11.

**Key words** [brachial plexus] [lateral cord] [medial cord] [posterior cord] [axillary artery]

### Introduction

Anatomical variations of the infraclavicular part of the brachial plexus acquire clinical importance in posttraumatic evaluations and exploratory interventions of the arm for peripheral nerve repair. In the infraclavicular part of the brachial plexus the cords lie posterior to the first part of the axillary artery but, descending posterior to pectoralis minor, they pass into positions relative to the second part of the axillary artery which correspond to their names. The plexus ends at the lower border of pectoralis minor by dividing into a number of nerves [1]. The musculocutaneous nerve arises from the lateral cord of the brachial plexus, passes inferolaterally to supply and then pierce coracobrachialis. It then descends between biceps and brachialis sending branches to both [1].

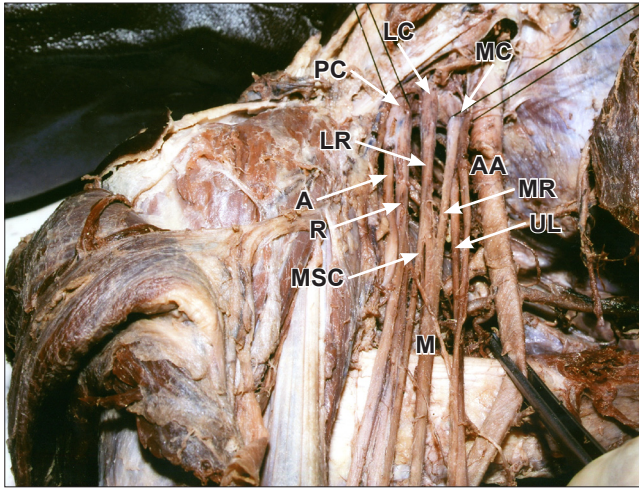
### Case Report

During routine dissection of an embalmed adult cadaver in PSG Institute of Medical Sciences and Research, Coimbatore, Tamilnadu, the present variation was observed in the right upper limb. The pectoral region, axilla and arm were dissected. The axillary artery and the cords of the brachial plexus and the branches of the cords were identified. The lateral, medial and posterior cords were found lateral to the axillary artery and the branches of the cords namely, the musculocutaneous nerve, lateral root and

medial root of median nerve, ulnar nerve, medial cutaneous nerve of forearm, radial and ulnar nerves were all present lateral to the axillary artery. The musculocutaneous nerve was not piercing the coracobrachialis muscle. The median nerve was formed by the union of lateral root from lateral cord and medial root from medial cord, and both the roots were present lateral to the axillary artery. The median nerve crossed the axillary artery from lateral to medial, anterior to the axillary artery and coursed medial to the brachial artery in the arm. The ulnar nerve from the medial cord was found to be lateral to the axillary artery and then it crossed the axillary artery from lateral to medial and further it coursed down medial to the brachial artery. The radial nerve from the posterior cord was also present lateral to the axillary artery and coursed down lateral to the axillary artery.

### Discussion

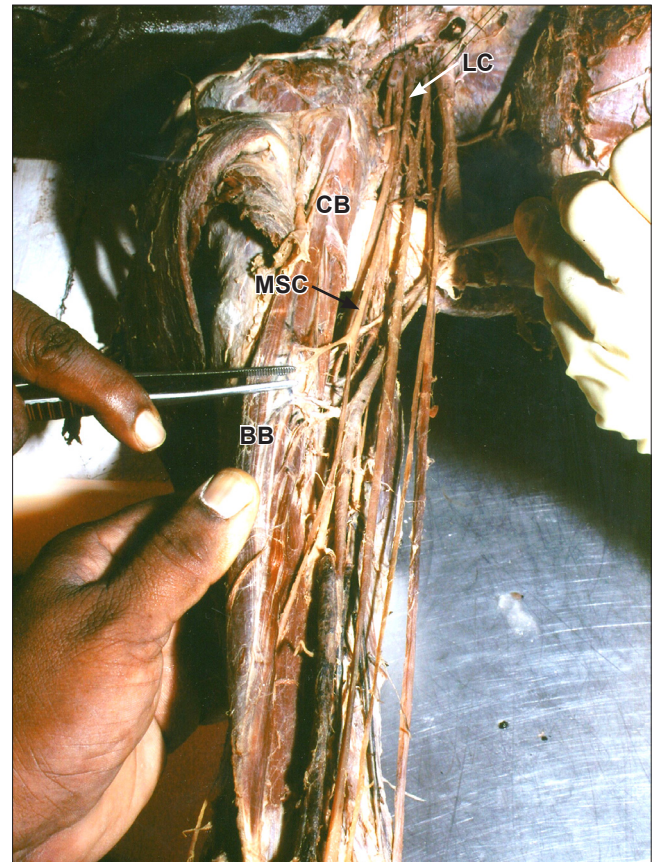Variations of the brachial plexus and its terminal branches are not uncommon and have been widely documented by several investigators [2,3]. Satyanarayana et al. reported in one case as all the three cords namely lateral, medial and posterior cords of brachial plexus were noted to be lateral to the third part of axillary artery [4]. In the present case reported here also all the three cords were present lateral to the axillary artery. The three cords of brachial plexus enter the axilla and are arranged according to their names around



**Figure 1.** Cords are related lateral to axillary artery. (*LC*: lateral cord; *PC*: posterior cord; *MC*: medial cord; *A*: axillary nerve; *R*: radial nerve; *MSC*: musculocutaneous nerve; *M*: median nerve; *UL*: ulnar nerve; *AA*: axillary artery; *LR*: lateral root of median nerve; *MR*: medial root of median nerve)

the second and third part of axillary artery. But in the first part of axillary artery, the relations are different; the lateral and posterior cords lie lateral to the axillary artery, whereas the medial cord lies behind the axillary artery [5]. In contrary to the above report, in the current case the three cords –lateral, medial and posterior were found lateral to the axillary artery. The lateral root of median nerve is the largest branch of the lateral cord of brachial plexus, while the medial root arises from the medial cord and crosses in front of the axillary artery to join the lateral root. After joining of both roots, the median nerve descends anterior to the axillary artery and upper part of brachial artery to reach the medial aspect of brachial artery in the distal half of the arm [6]. In the present case, the median nerve was formed by union of lateral and medial roots, both the roots being lateral to the axillary artery. Ulnar nerve (C7, C8, and T1) is a branch of the medial cord. In the axilla the ulnar nerve descends between the third part of axillary artery and axillary vein and lies on a more posterior plane than the medial cutaneous nerve of forearm [5]. In contrary to the above said report the ulnar nerve in the present case was present lateral to the axillary artery and then it crossed the axillary artery from lateral to medial and further coursed down medial to the brachial artery. Nayak reported in one case where the origin of the musculocutaneous nerve was very low and it was not piercing coracobrachialis [7]. There was also a report in one case where the musculocutaneous nerve did not pierce coracobrachialis in the left upper limb and the nerve descended lateral to the brachial artery. In the right upper limb the musculocutaneous nerve gave a branch to coracobrachialis and then fused with the median nerve for 2 cm after that, it separated from the median nerve and without piercing the coracobrachialis muscle, it

descended and supplied the muscles of the arm [8]. In the present report also the musculocutaneous nerve was not piercing coracobrachialis muscle and descended lateral to the brachial artery and supplied the muscles of the arm. These variations in the relationship of cords of the brachial plexus and their branches with the axillary artery can be explained embryologically. The upper limb buds lie opposite the lower five cervical and upper two thoracic segments. As soon as the buds form, the ventral primary rami of the spinal nerves penetrate into the mesenchyme of limb bud. Immediately the nerves enter the limb bud, they establish intimate contact with the differentiating mesodermal condensations and the early contact between nerve and muscle cells is a prerequisite for their complete functional differentiation [9,10]. The variations could arise from circulatory factors at the time of fusion of the brachial plexus cords [11]. In man, the forelimb muscles develop from the mesenchyme of the para-axial mesoderm during fifth week of embryonic life [10]. The axons of spinal nerves grow distally to reach the limb bud mesenchyme. The peripheral processes of the motor and sensory neurons grow in the mesenchyme in different directions. Once formed, any developmental



**Figure 2.** Musculocutaneous nerve is not piercing coracobrachialis muscle. (*LC*: lateral cord; *CB*: coracobrachialis muscle; *MSC*: musculocutaneous nerve; *BB*: biceps brachii muscle)

differences would obviously persist postnatally [9]. As the guidance of the developing axons is regulated by expression of chemoattractants and chemorepulsants in a highly coordinated site-specific fashion, any alterations in signaling between mesenchymal cells and neuronal growth cones can lead to significant variations [12]. The variations of the cords of brachial plexus and its terminal branches

become important during surgical exploration of the axilla and arm to avoid damage to the important nerves [13]. It is very important to be aware of the variations of the cords of the brachial plexus and its relation to axillary artery during neurotization of brachial plexus lesions, shoulder arthroscopy by anterior glenohumeral portal and during reconstructive surgery of the shoulder joint.

## References

- [1] Romanes GJ. *Cunningham's Manual of Practical Anatomy. Volume 1, Upper and Lower Limbs. 15th Ed., Oxford, Oxford University Press. 1990; 33–69.*
- [2] Kerr AT. The brachial plexus of nerves in man, the variations in its formation and branches. *Am J Anat.* 1918; 23: 285–395.
- [3] Miller RA. Comparative studies upon the morphology and distribution of the brachial plexus. *Am J Anat.* 1934; 54: 143–175.
- [4] Salyanarayana N, Vishwakarma N, Kumar GP, Guha R, Datta AK, Sunitha P. Variation in relation of cords of brachial plexus and their branches with axillary and brachial arteries – a case report. *Nepal Med Coll J.* 2009; 11: 69–72.
- [5] Standring S, ed. *Gray's Anatomy. 39th Ed., Philadelphia, Elsevier, Churchill Livingstone. 2005; 846–848.*
- [6] Williams PL, Bannister LH, Berry MM, Collins P, Dyson M, Dussek JE, Ferguson MWJ. *Gray's Anatomy. 38th Ed., Edinburgh, Churchill Livingstone. 1995; 1266–1274.*
- [7] Nayak S, Samuel VP, Somayaji N. Concurrent variations of median nerve, musculocutaneous nerve and biceps brachii muscle. *Neuroanatomy.* 2006; 5: 30–32.
- [8] Chitra R. Multiple bilateral neuroanatomical variations of the nerves of the arm. *Neuroanatomy.* 2007; 6: 43–45.
- [9] Brown MC, Hopkins WG, Keynes RJ. *Essentials of Neural Development. Cambridge, Cambridge University Press. 1991; 46–66.*
- [10] Larsen WJ. *Human Embryology. 2nd Ed., Edinburgh, Churchill Livingstone. 1997; 311–339.*
- [11] Kosugi K, Mortia T, Yamashita H. Branching pattern of the musculocutaneous nerve. 1. Cases possessing normal biceps brachii. *Jikeikai Medical Journal.* 1986; 33: 63–71.
- [12] Sannes DH, Reh TA, Harris WA. *Development of the Nervous System. New York, Academic Press. 2000; 189–197.*
- [13] Abhaya A, Khanna J, Prakash R. Variation of the lateral cord of brachial plexus piercing coracobrachialis muscle. *J Anat Soc India.* 2003; 52: 168–170.