

Brachial plexus variation involving the formation and branches of the cords

Published online November 28th, 2010 © <http://www.ijav.org>

Flora M. FABIAN-TAYLOR †
Kakarlapudi Sridhar VARMA

Department of Anatomy and Histology, International Medical and Technological University (IMTU), Dar-Es-Salaam, TANZANIA.



† Flora M. Fabian-Taylor
Associate Professor
Department of Anatomy and Histology
International Medical and Technological University
P.O. Box 77504, Dar-Es-Salaam, TANZANIA.
☎ +255 22 284 7045
✉ flr_fabiantaylor@yahoo.co.uk

Received May 25th, 2010; accepted August 18th, 2010

ABSTRACT

This case report is aimed at reporting a rare variation of brachial plexus involving the cords and its branches in the right upper limb. The musculocutaneous nerve was missing. The whole medial cord continued as a medial root of median nerve. The lateral cord gave off the lateral root of median nerve and an additional root joined with posterior cord to form a short common trunk. The short common trunk divided into two roots: one joined the median nerve; and the second one continued down as ulnar nerve. Median nerve supplied biceps brachii and brachialis muscles. The coracobrachialis muscle was supplied by radial nerve. The cutaneous innervation to the upper limb was derived from radial and ulnar nerves. © IJAV. 2010; 3: 191–193.

Key words [short common trunk] [missing] [musculocutaneous nerve]

Introduction

The brachial plexus is a plexus of nerves formed by anterior rami of the cervical spinal nerves from C5 – C8 and the first thoracic spinal Nerve (T1). Invariably the plexus may receive fibers from the ventral rami of C4 and T2. These ventral rami have been named as roots of the brachial plexus, which join to form trunks; the trunks divide to form posterior and anterior divisions, which finally unite again to form the posterior, medial and lateral cords of the brachial plexus in relation to the axillary artery. The brachial plexus supplies the upper limbs and the thoracic wall through its numerous branches from the roots, trunks and cords. The terminal branches from the cords form the major nerves of the brachial plexus that supply the muscles of the upper limb. The axillary and the radial nerves are the terminal branches from the posterior cord. The axillary nerve supplies the shoulder muscles, where as the radial nerve supplies extensor compartment of the upper and forearm muscles. The median nerve is normally formed by a medial root from the medial cord and a lateral root from the lateral cord and does not give any branches that supply the muscles of the upper arm but supplies the flexor compartment of the forearm, muscles and skin of the palm. The ulnar nerve is the major terminal branch from the medial cord and shares with the median nerve in supplying the muscles of the flexor compartment of the forearm and small muscles of the palm. Apart from the ulnar nerve and the medial root of the median nerve, the medial cord gives

off the medial cutaneous nerves of the arm and forearm that supply the skin on the medial and anterior aspects of the upper limb. The musculocutaneous nerve is normally given off from the lateral cord together with the lateral root of the median nerve, and supplies the flexor muscles of the upper arm namely biceps brachii, brachialis, coracobrachialis and cutaneous innervation to the skin on the lateral aspect of the upper limb.

Case Report

During the routine dissection of the upper limb for the medical undergraduates, in the Department of Anatomy and Histology at International Medical and Technological University, Dar-Es-Salaam, we examined 12 male cadavers and noted that in a 45-year-old male cadaver, there were variations in the right brachial plexus. The brachial plexus on the left side was as usual. In this case the median nerve gave off branches that supplied the muscles of the flexor compartment of the upper arm while the musculocutaneous nerve was missing. The ulnar nerve was formed from the lateral and posterior cords. The whole medial cord continued down as the medial root of the median nerve, which received a lateral root from the lateral cord (Figure 1). The lateral cord, after giving off the lateral root to the median nerve, it gave off an additional root that joined the posterior cord to form a short common trunk (Figure 2). The short common trunk divided into two: one as an additional root to the median nerve and second one continued down as ulnar nerve. Thus ulnar nerve received fibers from the lateral

and posterior cords. The posterior cord, after giving off the radial nerve, gave off a root that joined the additional root from the lateral cord to form a short common trunk (Figure 2), which divided into two; one large division joined the median nerve as an additional root and the second division formed the ulnar nerve. The median nerve supplied the biceps brachii and brachialis muscles (Figure 2). The coracobrachialis muscle was supplied by a branch from radial nerve and the cutaneous branches to the upper arm are given off by both the radial and the ulnar nerves.

Discussion

Usually, the lateral cord after giving off the lateral pectoral nerve to the pectoralis major muscle, divides into the musculocutaneous nerve that supply the muscles of the flexor compartment of the upper arm and the lateral root of the median nerve. In this case, the musculocutaneous

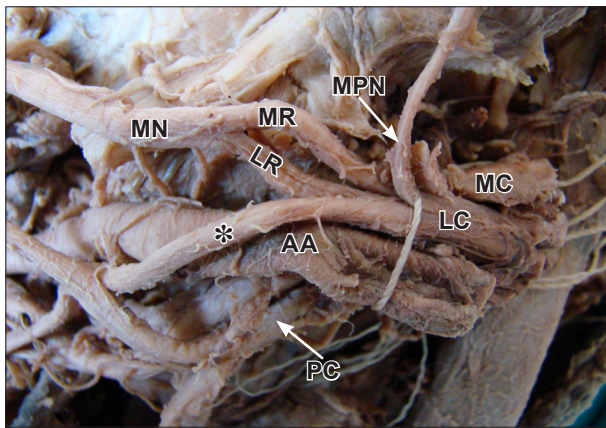


Figure 1. Photograph showing cords of right brachial plexus. (MC: medial cord; LC: lateral cord; PC: posterior cord; AA: axillary artery; MPN: medial pectoral nerve; MR: medial root of median nerve; LR: lateral root of median nerve; MN: median nerve; *: additional root arising from lateral cord)

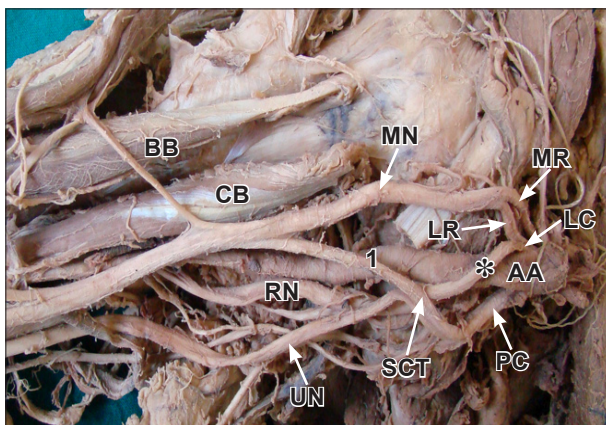


Figure 2. Photograph showing branches of right brachial plexus. (MR: medial root of median nerve; LR: lateral root of median nerve; LC: lateral cord; AA: axillary artery; PC: posterior cord; *: additional root arising from lateral cord; SGT: short common trunk; MN: median nerve; I: additional root to the median nerve; RN: radial nerve; UN: ulnar nerve; CB: coracobrachialis; BB: biceps brachii)

nerve was missing and both the ulnar and median nerves received fibers from the lateral and posterior cords, thus the median nerve supplied muscles of the upper arm. The medial cord usually gives off its first muscular branch, the medial pectoral nerve that supplies both the pectoral muscles, before it gives off the medial root of the median nerve and the ulnar nerve, both supplying the muscles of the flexor compartment of the forearm. The ulnar nerve generally does not give cutaneous branches to the upper arm; but in this case both the ulnar and radial nerves gave cutaneous branches to the upper arm, which is very rare. The contribution of the lateral cord to the posterior cord explains the radial nerve supplying the coracobrachialis muscle.

Variations in branching pattern of brachial plexus have been reported. The most commonly reported variation is the absence of musculocutaneous nerve [1–4]. Variations such as formation of the median nerve and musculocutaneous nerve and the muscles of the upper limb they supply have been reported [1,2,5]. The median nerve has been reported to receive more than one branch from the lateral cord and to have variation in its distribution to the muscles of the upper limb [6,7]. Muscles of the upper limb normally developed from somites, which have a specific effect on the position of the developing spinal nerves. These nerves are in intimate contact with the differentiating mesodermal tissues condensations that end in a myotome mass. Modification of the primitive segmental arrangement of the nerves entering the limb buds has resulted in the formation of complicated plexus, due to caudal migration of the attachment of the limb bud and intrinsic migration of its individual muscles during development [8]. Thus variations in the myotome formation are considered to be the root cause of the variations in the cords and branches of the brachial plexus. As suggested by Sannes et al., the guidance of the developing axons is regulated in a highly coordinated specific fashion. Once these developmental variations are formed they persist in postnatal life and become adulthood variations [9].

Knowledge of brachial plexus variations has important anatomical and surgical clinical applications especially in relation to trauma and surgical procedures of upper limb [10,11]. The present case report provides additional knowledge on brachial plexus variations to clinicians, which may help to avoid damage during surgical procedures related to plastic and reconstructive surgeries.

References

- [1] Apora I, Dhingra R. Absence of musculocutaneous nerve and accessory head of biceps brachii: a case report. *Indian J Plast Surg.* 2005; 38: 144–146.
- [2] Nayak S. Absence of musculocutaneous nerve associated with clinically important variations in the formation, course and distribution of the median nerve – a case report. *Neuroanatomy.* 2007; 6: 49–50.
- [3] Gumusburun E, Adiguzel E. A variation of the brachial plexus characterized by the absence of the musculocutaneous nerve: a case report. *Surg Radiol Anat.* 2000; 22: 63–65.
- [4] Sud M, Sharma A. Absence of musculocutaneous nerve and the innervation of coracobrachialis, biceps brachii and brachialis from the median nerve. *J Anat Soc India.* 2000; 49: 176–177.

- [5] Badawoud MMH. A study on the anatomical variations of median nerve formation. *Bahrain Medical Bulletin*. 2003; 25: 1–5.
- [6] Das S, Paul S. Anomalous branching pattern of lateral cord of brachial plexus. *Int J Morphol*. 2005; 23: 289–292.
- [7] Beheiry EE. Anatomical variations of the median nerve distribution and communication in the arm. *Folia Morphol*. 2004; 63: 313–318.
- [8] Moore KL, Persaud TVN. *The Developing Human. Clinically Oriented Embryology*. 8th Ed., New Delhi, Elsevier. 2008; 365–371.
- [9] Sannes DH, Reh TA, Harris WA. *Development of the nervous system*. New York, Academic Press. 2000; 189–197.
- [10] Nakatani T, Mizukami S, Tanaka S. Three cases of the musculocutaneous nerve not perforating the coracobrachialis muscle. *Kaihogaku Zasshi*. 1997; 72: 191–194.
- [11] Aydinlioglu A, Cıprak B, Akpınar F, Tosun N, Dogan A. Bilateral median nerve compression at the level of Struthers' ligament. Case report. *J Neurosurg*. 2000; 92: 693–696.