

Bilateral Variation in Origin of Thoracodorsal Artery along with Non-Piercing Variant of Musculocutaneous Nerve on Left Side

Rajeev Panwar*, A Julie Christy, N Charanya

Cawich SO, Gardner MT, Thomas DA, et al. Liver variant: A report on diaphragmatic slips and hepatic sulci. *Int J Anat Var.* 2021;14(1):39-41.

ABSTRACT

Subclavian artery continues as axillary artery in the axilla and is the principal source of blood supply of the lateral thoracic wall, axilla, scapular region, and upper limb. Thoracodorsal artery is one of the terminal branches of subscapular artery, which in turn is branch from the third part of axillary artery. Musculocutaneous nerve, a branch from lateral cord of brachial plexus, is the chief nerve supply of anterior compartment of arm, commonly seen piercing the coracobrachialis muscle before continuing as lateral cutaneous nerve of forearm.

In the current case report, thoracodorsal arteries on both sides were arising from lateral thoracic artery, branch of second part of axillary artery and the left musculocutaneous nerve was not piercing the coracobrachialis muscles. Also, there was a communication between left musculocutaneous nerve and left median nerve.

The knowledge about normal and variant pattern of origin and course of branches of axillary artery is very important as it may help the surgeons to identify the source of bleeding during surgeries in region of shoulder or axilla. Also, post-surgical complication or symptoms of nerve repair can be explained by the variation in course of musculocutaneous nerve and its communication with median nerve.

Key Words: Subclavian Artery; Musculocutaneous Nerve, Brachial Plexus

INTRODUCTION

The axillary artery is continuation of subclavian artery at the outer border of first rib till lower border of teres major muscle and it is principal source of blood supply of axilla, lateral thoracic wall, scapular region, and upper limb [1-5]. Axillary artery can be divided by pectoralis minor muscle into first, second and third part [6,7]. The first part of axillary artery gives of superior thoracic artery, the second part gives lateral thoracic and acromio-thoracic artery, and the third part gives subscapular, anterior, and posterior circumflex humeral arteries [8-10].

Thoracodorsal artery or artery to latissimus dorsi is one of the terminal branches of subscapular artery, other being circumflex scapular artery. It runs along lateral border of scapula, lying between latissimus dorsi and serratus anterior and posterior to lateral thoracic artery, a branch from second part of axillary artery. On its course, thoracodorsal supplies teres major, intercostal muscles and serratus anterior. It is accompanied by thoracodorsal nerve, a branch from posterior cord of brachial plexus. Thus, thoracodorsal artery and nerve forms principal neurovascular supply to the latissimus dorsi muscle [10].

Musculocutaneous nerve is the nerve of anterior compartment of arm, arise from lateral cord of brachial plexus and have root value of C5-7. After piercing the coracobrachialis muscle, it runs between biceps brachii and brachialis muscle. Musculocutaneous nerve is the nerve supply of the muscles of anterior compartment of arm namely coracobrachialis, biceps brachii and brachialis, humerus bone and elbow joint and then continues as lateral cutaneous nerve of forearm [11].

Detailed knowledge about origin and course of thoracodorsal arteries and other branches of axillary artery is essential for the vascular surgeons for performing surgeries in axillary or thoracic areas. The variation in the course of musculocutaneous nerve may pose significant obstacle during post-injury examinations and assessment following the nerve repair.

CASE REPORT

While doing dissection of a male cadaver of about 50 year age, for teaching the undergraduates in the Department of Anatomy in JIPMER, variation in the origin of thoracodorsal artery on both sides of the body and variation in the course of musculocutaneous nerve in the left arm was observed.

On the right side, lateral thoracic artery originated from second part of the axillary artery, continued for short course in the lateral thoracic wall and supplied the axillary pad of fat and lateral thoracic wall and then gave origin to thoracodorsal artery which was accompanied by thoracodorsal nerve. The rest of the main trunk of the lateral thoracic artery supplied the lateral thoracic wall and was accompanied by the long thoracic nerve of Bell (Figure 1).

On the left side, lateral thoracic artery took origin from second part of axillary artery, supplied the axillary pad of fat and lateral thoracic wall and continued as thoracodorsal artery and was accompanied by the thoracodorsal nerve (Figure 2).

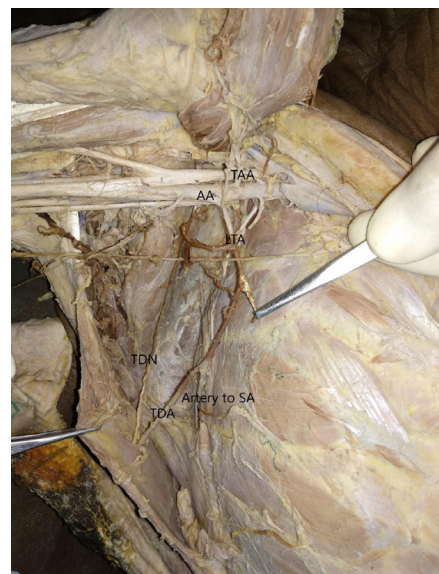


Figure 1) Showing the branches of second part of axillary artery on right side. (AA – axillary artery, TAA – thoraco-acromial artery, LTA – lateral thoracic artery, TDA – Thoraco dorsal artery, TDN – thoraco dorsal nerve, SA – serratus anterior).

Department of Anatomy, Shri Sathya Sai Medical College & Research Institute, SBV (Deemed University), Tamil Nadu, India

Correspondence: Dr. Rajeev Panwar, Department of Anatomy, Shri Sathya Sai Medical College & Research Institute, SBV (Deemed University), Tamil Nadu, India. Telephone +9462925888; E-mail:rajeevpanwar96@yahoo.com

Received: Nov 10, 2020, Accepted: Jan 29, 2021, Published: Feb 05, 2021



This open-access article is distributed under the terms of the Creative Commons Attribution Non-Commercial License (CC BY-NC) (<http://creativecommons.org/licenses/by-nc/4.0/>), which permits reuse, distribution and reproduction of the article, provided that the original work is properly cited and the reuse is restricted to noncommercial purposes. For commercial reuse, contact reprints@pulsus.com

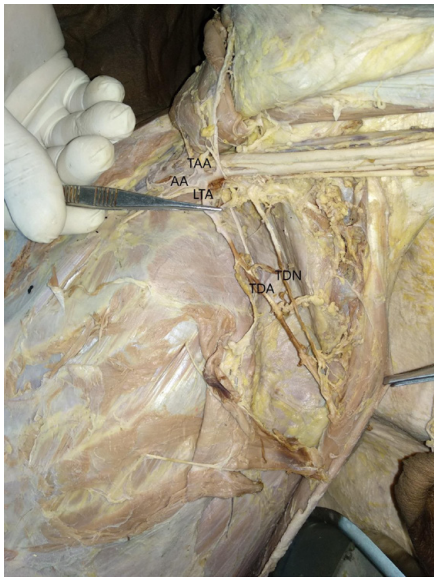

Figure 2) Showing the branches of second part of axillary artery on left side. (AA – axillary artery, TAA – thoraco-acromial artery, LTA – lateral thoracic artery, TDA – Thoraco dorsal artery, TDN – thoraco dorsal nerve).

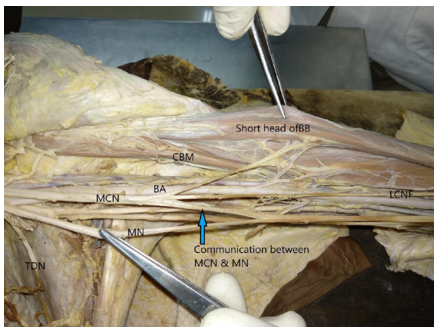


Figure 2) Showing the course of left musculocutaneous nerve. (BA – brachial artery, MCN – musculocutaneous nerve, MN – median nerve, CBM – coracobrachialis muscle, BB – biceps brachii muscle, LCNF – lateral cutaneous nerve of forearm, TDN – thoracodorsal nerve).

So, the thoracodorsal arteries on the right side was branch of and on the left side was continuation of lateral thoracic artery which originated from second part of axillary artery.

Musculocutaneous nerve on the left side did not pierce the coracobrachialis muscle. After its formation at the lateral cord, the musculocutaneous nerve supplied the coracobrachialis muscle without piercing it and then continued medial to the short head of biceps brachii muscle. After supplying the short and long head of biceps it pierced the short head of the same and continued as lateral cutaneous nerve of the forearm. A communication was observed between musculocutaneous and median nerve (Figure 3).

DISCUSSION

The variations in the branching pattern of axillary artery are not uncommon. Huelke's studied the variation in the branching pattern of axillary artery and the result included the origin of subscapular artery from the first part of axillary artery in 0.6% cases, from the second part in 15.7% cases, and from the third part in 79.2% cases, the origin of lateral thoracic artery from the first part in 10.7% cases, from the second part in 52.2% cases, and from the third part in 1.7% cases; and the origin of posterior circumflex humeral artery from the third part of axillary artery in 67.5% cases and from the subscapular artery in 15.2% cases [4]. Akhtar et al. described a common trunk originating from second part of axillary artery having lateral thoracic and subscapular artery as its branches, out of which subscapular artery was continuing as thoracodorsal artery after giving off circumflex scapular artery [1]. Bagojiet. al. found a trifurcation of third part of axillary artery having subscapular, superficial, and deep brachial artery. Thoracodorsal artery originated as one of the branches of subscapular artery [5]. Kanaka et al. studied the variation in the branching pattern of axillary artery and found anomalous origin of subscapular artery from second part of axillary artery along with usual origin from the third part of the axillary artery [6]. Natsis

et al. reported bilateral accessory thoracodorsal arteries among which the usual arteries were the terminal branches of the subscapular artery and the accessory thoracodorsal arteries originated directly from the third part of the axillary arteries [9]. These different types of variations may occur due to arrest at any developmental stage of vessels of the upper limb such as regression, retention, or reappearance of new blood vessels [3].

The knowledge about the variations in branching pattern of axillary artery and its branches play important role in preventing any unwanted complications during surgeries around pectoral and axillary regions. Surgeons utilize various microvascular grafts from branches of arteries of upper limb especially axillary artery during coronary bypass grafting as well as other reconstructive surgeries of axilla [7]. So, it is necessary for the clinician to know about the normal and variant branching pattern of axillary artery for exact diagnostic and surgical interventions.

Suma M. and Shradha I. studied the course of musculocutaneous nerve in coracobrachialis and reported three out of forty cadavers had unilateral non-piercing musculocutaneous nerve [12]. In a study by Thakur et al., the non-piercing variant of musculocutaneous nerve were found in one female and two male cadavers out of total forty cadavers (7.5%) [8]. during the development, one of the three head of coracobrachialis is disappeared, and the musculocutaneous nerve passes between the two heads, hence, the musculocutaneous nerve is seen piercing the muscle [2]. As per the classification proposed by D. Venieratos and S. Anagnostopoulou, the left musculocutaneous nerve in the present cadaver belong to type III, the nerve arose from lateral cord fibers, did not pierce the coracobrachialis muscle, later supplied the remaining two muscles of anterior compartment of arm [13].

The knowledge about the course of the musculocutaneous nerve is very important. The surgeons should be able to identify the normal or the variant musculocutaneous nerve otherwise the nerve might get injured during the surgeries of shoulder girdle or axilla. Also it may help to explain the unusual symptoms arise due to median nerve injury.

CONCLUSION

The present case report described bilateral variation in the course of thoracodorsal artery along with left side non-piercing variant of musculocutaneous nerve. It is of paramount importance to have knowledge about branching pattern of axillary artery and the course of musculocutaneous nerve since the any variation in the course of the same might lead to complication during or following the surgeries of axilla or shoulder region. Also, the information about variation the course may help in explaining the cause of uncontrolled bleeding or symptoms of median nerve injury.

CONFLICTS OF INTEREST / COMPETING INTERESTS

No conflict of interest was reported.

CONTRIBUTION

Dr Rajeev Panwar (RP) identified the variation in the cadaver and reviewed the relevant literature related to the anatomical variation. Dr Julie Christy (JC) reviewed the relevant literature related to the finding and provided suggestion in the case report. Dr N Charanya (NC) provided suggestion while writing the case report. RP, JC and NC did the proof reading.

REFERENCES

1. Akhtar MJ, Rahman S, Kumar B, et al. A Rare Variation in the Branching Pattern of Axillary Artery. *Saudi J Health Sci.* 2016;5:39-41.
2. Datta AK. *Essentials of Human Anatomy part III*, 4th ed. Calcutta: cbi; 2009;50-51.
3. Hamilton WJ, Mossman HW. *Cardiovascular system.* In: *Human Embryology.* 4th ed. Baltimore: Williams and Wilkins; 1972;271-90.
4. Huelke DF. Variation in the origins of the branches of the axillary artery. *Anat Rec.* 1959;135:33-41.
5. Bagoji IB, Hadimani GA, Bannur BM, et al. A Unique Branching Pattern of the Axillary Artery: A Case Report. *JCDR.* 2013;7:2939-40.
6. Kanaka S, Eluru RT, Basha MA, et al. Frequency of Variations in Axillary Artery Branches and its Surgical Importance. *Int J Sci Stud.* 2015;3:14.
7. Karamürsel S, Bagdatli D, Demir Z, et al. Use of medial arm skin as a free flap. *Plast Reconstr Surg.* 2005;115:2025-31.

8. Thakur KC, Jethani SL, Parsad V. Non Piercing Variation of Musculocutaneous Nerve. JEMDS. 2015;4:15515-15517.
 9. Natsis K, Totlis T, Tsikaras P, et al. Bilateral accessory thoracodorsal artery. Ann Anat. 2006;188:447-9.
 10. Standring S, editor. Gray's Anatomy: the anatomical basis of clinical practice. Forty-first edition. New York: Elsevier Limited, 2016;827-28.
 11. Standring S, editor. Gray's Anatomy: the anatomical basis of clinical practice. Forty-first edition. New York: Elsevier Limited, 2016;831.
 12. Suma M, Shradha I. International journal of general medicine and pharmacy. 2013;2:53-64.
 13. Venieratos D, Anagnostopoulou S. Classification of communications between the musculocutaneous and median nerves. Clin Anat. 1998;11:327-31.
-
-