

Case Report



Bilateral indirect inguinal hernia with bilateral corona mortis: A case study from a laparoscopic perspective

Published online September 8th, 2011 © <http://www.ijav.org>

Vipula Rasanga BATADUWAARACHCHI ✦
Sharmila THILLAINATHAN

Department of Anatomy, Faculty of Medicine, University of Colombo, Colombo 08, SRI LANKA.



✦ Vipula Rasanga Bataduwaarachchi, MBBS
Department of Anatomy
Faculty of Medicine
University of Colombo
Colombo 08, SRI LANKA.
☎ +94 077 5518470
✉ vipulal7@yahoo.com

Received November 30th, 2010; accepted August 6th, 2011

ABSTRACT

The “corona mortis” or crown of death is defined as the vascular connection between the obturator and external iliac systems crossing the superior pubic ramus. It has a great clinical significance as it could be accidentally cut during any surgery in that area causing fatal hemorrhage. We present a rare variant of bilateral arterial and venous corona mortis in a male cadaver with bilateral indirect inguinal hernia. Laparoscopic repair is indicated in bilateral case and there is a greater risk of damaging corona mortis during pre-peritoneal dissection. Surgeons must deliberately look for the above vascular variant in every case for its presence to avoid unnecessary risk to the patient. © IJAV. 2011; 4: 152–154.

Key words [corona mortis] [bilateral indirect inguinal hernia] [laparoscopic hernial repair]

Introduction

The corona mortis is defined as the vascular connection between the obturator and external iliac systems [1]. Usually, the obturator vessels originate from the internal iliac vessels and traverse the lateral pelvic wall along with the obturator nerve. There are marked variations of these vessels in relation to their origin, course and the distance from the pubic symphysis [2]. The name “corona mortis” or crown of death implies the importance of this feature, as significant hemorrhage may occur if accidentally cut and it is difficult to achieve subsequent homeostasis [3].

Laparoscopic inguinal hernioplasty has been performed by many surgeons for patients with bilateral inguinal hernia, recurrent inguinal hernia or in patients with unilateral inguinal hernia who strongly prefer this kind of operation. In such cases, if the laparoscopic repair is indicated, the surgeon must be aware of the potential presence of aberrant obturator arteries. Their unexpected presence can become a matter of great concern not only during laparoscopic repair of inguinal hernia but for anybody who may perform surgical procedures related to the superior pubic ramus.

Here we present a case of bilateral indirect inguinal hernia with a rare variant of the corona mortis to signify its vulnerability to injury during surgical repair.

Case Report

A bilateral indirect inguinal hernia was observed in a 65-year-old male cadaver during routine dissections of the inguinal region. The pelvis was separated at the level of L4-L5 articulation. Pelvic contents were carefully removed including the bowel content of the hernial sacs keeping the hernial openings intact. The external iliac vessels, psoas major muscle, lateral pelvic wall, obturator vessels and nerve were carefully dissected and the vascular elements on the superior pubic rami were evidenced (Figure 1).

On the left side, the obturator artery was arising from the anterior division of the internal iliac artery and an arterial corona mortis was found arising from the external iliac artery (Figure 2). The two arteries were anastomosing at the upper margin of the obturator foramen and passing through the foramen as a single vessel. The vein was as usual. Distance from the arch of the lacunar ligament and the pubic symphysis to the anastomosing vessel was 13.2 mm and 3.9 mm, respectively.

On the right side, the arterial component was as usual while the vein was draining to the external iliac vein crossing the superior ramus of the pubic bone as the venous corona mortis (Figure 3). The distance from the lacunar ligament and the pubic symphysis to the anastomosing vessel was 13.5 mm and 4.1mm, respectively.

The arterial corona mortis was 2 mm in diameter while the venous corona mortis was 3 mm. The venous corona mortis had divided into two branches closer to the external iliac vein.

Discussion

Variations in the origin and course of the accessory obturator vessels have attracted the attention of anatomists and surgeons because of their clinical significance. Indirect inguinal hernias, having a narrow neck are at risk of strangulation. Therefore surgical repair is usually indicated regardless of the age, and laparoscopic repair is considered in bilateral cases. The superior border of the iliopubic ramus

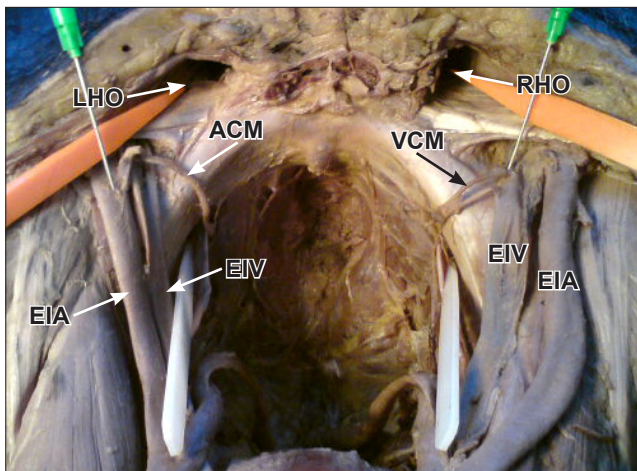


Figure 1. Cranial view of the pelvic cavity showing bilateral corona mortis and bilateral inguinal hernial orifices. (*LHO: left hernial orifice; RHO: right hernial orifice; ACM: arterial corona mortis; VCM: venous corona mortis; EIA: external iliac artery; EIV: external iliac vein*)

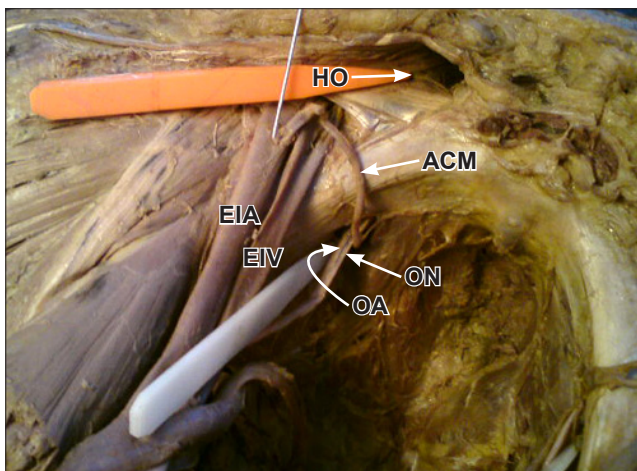


Figure 2. Left side of the pelvic cavity showing the arterial corona mortis. (*HO: hernial orifice; ACM: arterial corona mortis; EIA: external iliac artery; EIV: external iliac vein; ON: obturator nerve; OA: obturator artery*)

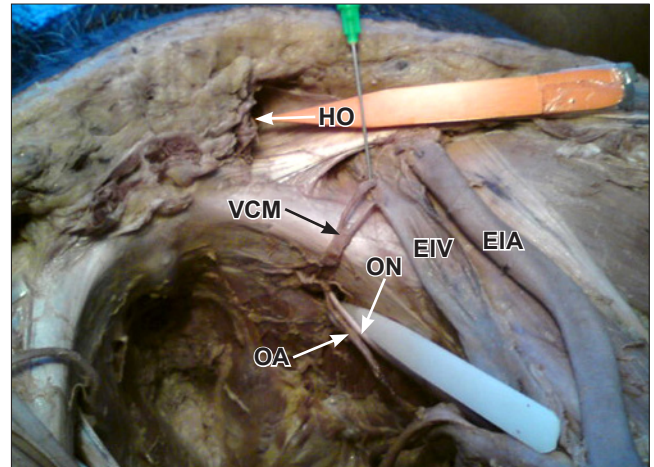


Figure 3. Right side of the pelvic cavity showing the venous corona mortis. (*HO: left hernial orifice; VCM: venous corona mortis; EIA: external iliac artery; EIV: external iliac vein; ON: obturator nerve; OA: obturator artery*)

serves as an anchoring site for inguinal hernia repairs [4]. Variable obturator vessels can be inadvertently cut during laparoscopic interventions.

Dual origin of the obturator artery from both internal and external iliac systems has been reported less frequently than single arterial origin; 5.4% by Namking et al. [5], 2% Pai et al. [2]. Compared to other topographical variations corona mortis arising directly from the external iliac artery anastomosing with the obturator artery is extremely infrequent (1.1%) [6]. The obturator artery is formed as a result of uneven growth of the anastomosis between the internal iliac and the external iliac arteries. All gradations may be found between normal arrangement and complete replacement of the original intrapelvic portion of the obturator artery by the pubic anastomosis. If both the rami are enlarged, then the condition of dual origin persists [7]. This variety seems to be more dangerous as there will be bleeding from both the ends during an accidental cut since both the normal and the accessory obturator arteries are originating from two major vessels. Venous corona mortis has been reported in higher frequency than the arterial one [1, 8]. In our specimen, venous corona mortis was wider than the arterial one and branching was seen on the superior pubic ramus. Venous corona mortis has been reported to be varying in number and the size [2]. This highlights the potential of bleeding with regard to venous corona mortis in an accidental cut.

According to the morphological classification of the corona mortis by Rusu et al., there are three patterns, as I-III. In our case, the arterial corona mortis corresponds to type I.4, which was the rarest pattern and venous corona mortis corresponds to type II.1, which was rather common [9].

A sound knowledge of retropubic pelvic vascular anatomy is vital for successful performance of laparoscopic herniorrhaphy as well as for endoscopic total extraperitoneal

inguinal hernioplasty. During the laparoscopic hernial repair the injury to corona mortis could happen during dissection of the preperitoneal space and hernial sac; the vessels can also be injured from tacker used for fixing the mesh to abdominal wall; an injury of it may need conversion from laparoscopic hernia repair to open surgery to stop the bleeding [10].

Distances from these vessels to bony landmarks are individually variable, gender-related and anthropological type related, and so, their knowledge appears to be of reduced

utility and reliability [9]. Therefore surgeons must evaluate directly, with caution, the location and intrinsic relations of the vessel(s) over the superior pubic branch to prevent a fatal hemorrhage. Furthermore, the laparoscopic repair of bilateral hernia in the presence of bilateral corona mortis can have even greater risk of accidental damage. Therefore the surgeon must deliberately look for the corona mortis in individual cases to avoid damage rather than changing the surgical procedure.

References

- [1] Berberoglu M, Uz A, Ozmen MM, Bozkurt MC, Erkuran C, Taner S, Tekin A, Tekdemir I. Corona mortis: an anatomic study in seven cadavers and an endoscopic study in 28 patients. *Surg Endosc*. 2001; 15: 72–75.
- [2] Pai MM, Krishnamurthy A, Prabhu LV, Pai MV, Kumar SA, Hadimani GA. Variability of the groin in the obturator artery. *Clinics (Sao Paulo)*. 2009; 64: 897–901.
- [3] Darmanis S, Lewis A, Mansoor A, Bircher M. Corona mortis: an anatomical study with clinical implications in approaches to the pelvis and acetabulum. *Clin Anat*. 2007; 20: 433–439.
- [4] Gilroy AM, Hermey DC, Dibenedetto LM, Marks SC Jr, Page DW, Lei QF. Variability of the obturator vessels. *Clin Anat*. 1997; 10: 328–332.
- [5] Namking M, Woraputtaporn W, Buranarugsu M, Kerdkoonchorn M, Chaijarookhanarak W. Variation in origin of the obturator artery and corona mortis in Thai. *Sriraj Med J*. 2007; 59: 12–15.
- [6] Bergman RA, Thompson SA, Alfifi AK, Saadeh F. *Compendium of Human Anatomic Variation: Text, Atlas, and World Literature*. Munich, Urban and Schwarzenberg. 1988; 84.
- [7] Piersol GA. *Human Anatomy*. 9th Ed., Philadelphia, Lippincott. 1930; 813–814.
- [8] Tornetta P 3rd, Hochwald N, Levine R. Corona mortis. Incidence and location. *Clin Orthop Relat Res*. 1996; 328: 97–101.
- [9] Rusu MC, Cergan R, Motoc AG, Folescu R, Pop E. Anatomical considerations on the corona mortis. *Surg Radiol Anat*. 2010; 32: 17–24.
- [10] Pungpapong SU, Thum-umnuayusuk S. Incidence of corona mortis; preperitoneal anatomy for laparoscopic hernia repair. *J Med Assoc Thai*. 2005; 88 Suppl 4: S51–S53.