



Bilateral accessory flexor muscle of the forearm giving rise to a variant head of the first lumbrical

Published online January 5th, 2015 © <http://www.ijav.org>

Guiyun ZHANG +
Bruce A. FENDERSON

Department of Pathology, Anatomy and Cell Biology,
Jefferson Medical College, Thomas Jefferson University,
Philadelphia, Pennsylvania, USA.



+ Guiyun Zhang, MD, PhD
Department of Pathology, Anatomy,
and Cell Biology
Thomas Jefferson University
1020 Locust Street
Room 263 Jefferson Alumni Hall
Philadelphia, PA 19107, USA.
☎ +1 (215) 503-7019
✉ guiyun.zhang@jefferson.edu

Received December 18th, 2013; accepted March 12th, 2014

Abstract

We describe a bilateral accessory deep flexor in the forearm that originated from the lateral side of the forearm. The relatively large tendon bifurcated distally to form two branches, one of which was associated with a variant head of the first lumbrical muscle. The presence of an accessory tendon and a variant muscle within the carpal tunnel may contribute to median nerve compression and development of carpal tunnel syndrome in some patients.

© *Int J Anat Var (IJAV)*. 2015; 8: 4–6.

Key words [accessory forearm flexor muscles] [carpal tunnel syndrome] [lumbricals]

Introduction

Accessory flexor muscles in the forearm were first reported by Gantzer in 1813 [1]. These small accessory muscles typically arise from the medial arm and forearm [2] and the deep surface of the flexor digitorum superficialis [3]. Gantzer muscles insert via thin tendons into the tendon of the flexor pollicis longus, digitorum superficialis, or flexor digitorum profundus [2–4].

Here, we report a bilateral accessory deep flexor in the forearm that originated from the lateral side of the forearm and the tendon bifurcated distally into two branches, one of which was associated with a variant head of the first lumbrical muscle. To our knowledge, this bilateral anatomic variation has not been reported previously.

Case Report

During routine dissection of the upper limb, a variant deep flexor muscle was noted bilaterally in the forearms of a white female cadaver. This muscle originated from the radial side of the interosseous membrane and the ulnar side of the radius. It was located between the muscle bellies of the flexor pollicis longus (FPL) and the flexor digitorum profundus (FDP) (Figure 1). This large accessory flexor muscle was unipennate

and spanned the distal three quarters of the forearm. The muscle belly was about 19 cm in length and 0.9 cm in width. The tendon of this accessory muscle was 4 cm in length; it lay between the tendons of the FPL and FDP and passed through the carpal tunnel, deep to the flexor retinaculum and median nerve.

The distal attachment of this accessory flexor muscle was examined in the carpal tunnel and palm of the hand. In this cadaver, the first lumbrical muscles showed bifid origins bilaterally, with both radial and ulnar heads (Figure 2). The radial head of the first lumbrical was continuous with and originated from the tendinous fibers of the accessory flexor tendon. The ulnar head originated from the FDP tendon to the index finger (the common anatomic pattern). A branch from median nerve was observed to innervate both heads of the first lumbricals, bilaterally (Figure 2).

After passing through the carpal tunnel, the tendon of the aberrant flexor muscle was observed to bifurcate. Most of its tendinous fibers on the radial aspect of the hand were continuous with and gave rise to the radial head of the first lumbrical muscle. The tendinous fibers on the ulnar aspect of the hand inserted into the FDP tendon and attached distally to the index finger. The anterior interosseous nerve was found

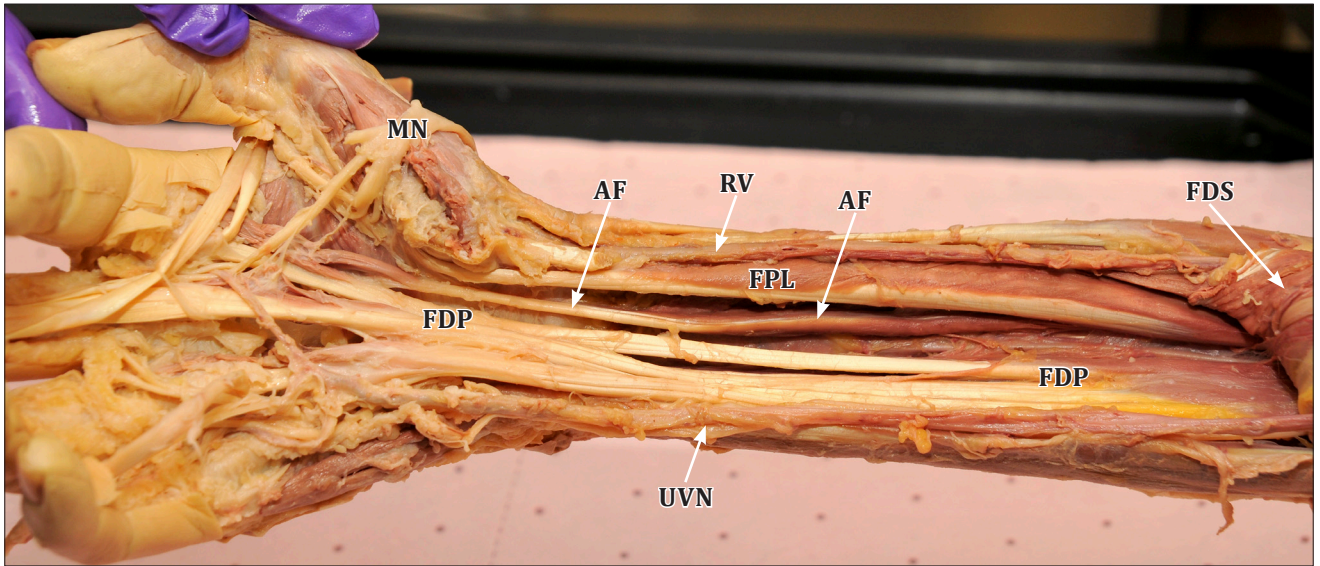
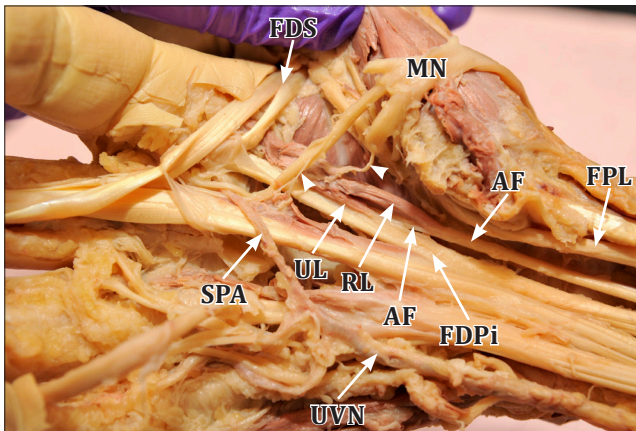
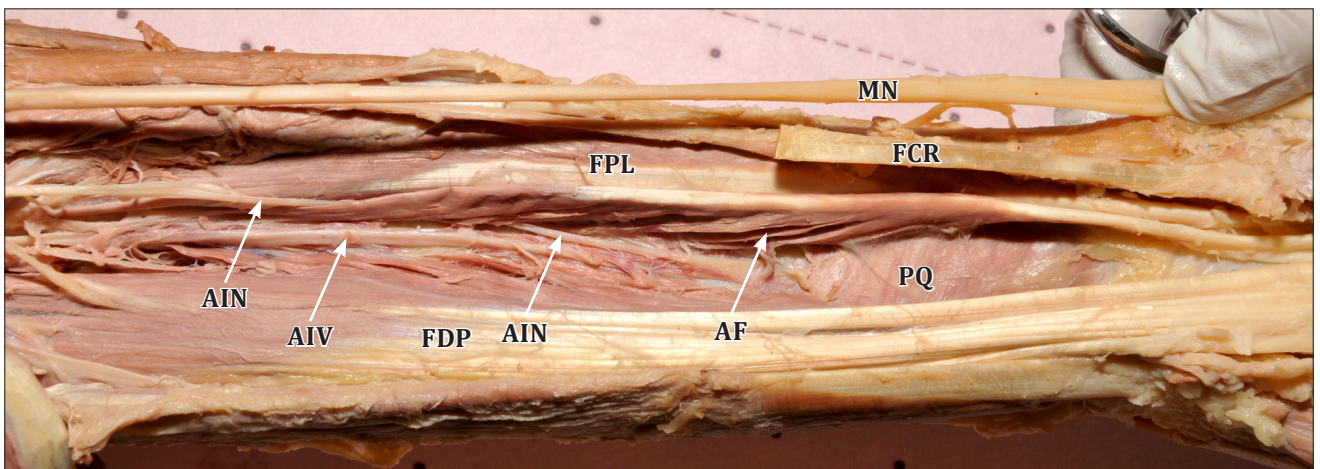


Figure 1. An accessory flexor muscle is located in the forearm between the flexor pollicis longus and the flexor digitorum profundus. This muscle is attached to the radius and interosseous membrane, and part of its tendon joins the flexor digitorum profundus in the palm of the hand. (AF: accessory flexor muscle and its tendon; FDP: flexor digitorum profundus; FPL: flexor pollicis longus; FDS: flexor digitorum superficialis -reflected; MN: median nerve -reflected; UVN: ulnar vessels and nerve; RV: radial vessels)



◀ **Figure 2.** Variant head of the 1st lumbrical muscle originates from the tendon of the accessory flexor in the hand. Branches of the median nerve innervate the radial and ulnar heads of the 1st lumbrical. (AF: accessory flexor; FDPi: flexor digitorum profundus tendon to the index finger; FDS: flexor digitorum superficialis tendon -reflected; FPL: flexor pollicis longus; MN: median nerve -reflected; white arrowheads: branches of the median nerve to 1st and 2nd lumbricals; RL: radial head of 1st lumbrical; SPA: superficial palmar arterial arch; UL: ulnar head of 1st lumbrical; UVN: ulnar vessels and nerve)

▼ **Figure 3.** The anterior interosseous nerve penetrates and innervates the accessory flexor muscle in the forearm. (AIN: anterior interosseous nerve; AIV: anterior interosseous vessels; AF: accessory flexor; FCR: flexor carpi radialis tendon; FDP: flexor digitorum profundus; FPL: flexor pollicis longus; MN: median nerve -lifted; PQ: pronator quadratus)



to penetrate and innervate this accessory deep flexor muscle in the middle of the forearm (Figure 3).

Discussion

Accessory deep flexors in the forearm are common and generally asymptomatic in most patients. However, accessory flexor muscles and tendons in the forearm and wrist may be associated with significantly increased risk for peripheral neuropathology. For example, Gantzer muscle tendons in the wrist and hand have been reported to impinge upon the median nerve causing thenar muscle weakness and other symptoms of carpal tunnel syndrome [5]. The tendon of the accessory deep flexor muscle described in this report was large (similar in size to the tendon of the FPL), suggesting that this person might have been at increased risk for median nerve compression within the carpal tunnel.

Accessory deep flexors may also impinge upon the anterior interosseous nerve in the forearm causing paralysis and muscle weakness of the wrist and hand [6]. In the case reported here, the anterior interosseous nerve was observed to pass through muscle fibers of an accessory deep flexor muscle. Thus, it is possible that contraction of the accessory flexor in this patient may have compressed this branch of the median nerve leading to paralysis and muscle weakness.

Our report also highlights the potential for neuropathy in patients with unusual and/or accessory first lumbrical muscles. Bifid or accessory first lumbricals have been reported by several authors [7, 8]. These aberrant lumbricals in the proximal hand have been associated with carpal tunnel syndrome in some patients [9, 10]. In the case reported here, the accessory head of the first lumbrical traveled through the distal portion of the carpal tunnel, deep to the median nerve, suggesting a clinically significant mechanism for median nerve compression in this person.

Acknowledgments

We wish thank the Humanity Gifts Registry and the many families who donate bodies of their loved ones for training the next generation of medical caregivers. Humanity Gifts Registry is a non-profit agency of the Commonwealth of Pennsylvania concerned primarily with the receipt and distribution of bodies donated to all medical and dental schools in the state for teaching purposes. The Registry, formerly called the Anatomical Board, has been in existence since 1883.

We, the authors, have no conflict of interest to declare.

References

- 11 Wood J. Variations in human myology observed during the winter session of 1867-68 at King's College, London. *Proc R Soc Lond*. 1867; 16: 483–525.
- 12 al-Qattan MM. Gantzer's muscle. An anatomical study of the accessory head of the flexor pollicis longus muscle. *J Hand Surg Br*. 1996; 21: 269–270.
- 13 Jones M, Abrahams PH, Sanudo JR. Case report: accessory head of the deep forearm flexors. *J Anat*. 1997; 191: 313–314.
- 14 Anita T, Kalbande S, Asha K, Dombe D, Jayasree N. A unique variation of flexor digitorum superficialis muscle and its clinical significance. *J Life Sci*. 2012; 4: 39–43.
- 15 Winkelman NZ. An accessory flexor digitorum profundus indicis. *J Hand Surg*. 1983; 8: 70–71.
- 16 Degreef I, De Smet L. Anterior interosseous nerve paralysis due to Gantzer's muscle. *Acta Orthop Belg*. 2004; 70: 482–484.
- 17 Basu SS, Hazary S. Variations of the lumbrical muscles of the hand. *Anat Rec*. 1960; 136: 501–504.
- 18 Roy S, Mehta V, Arora J, Dhuria R, Suri R, Rath G, Das S. An unusual bifid origin of 1st lumbrical muscle of hand: anatomical and clinical perspectives. *Clin Ter*. 2011; 162: 249–250.
- 19 Butler B Jr, Bigley EC Jr. Aberrant index (first) lumbrical tendinous origin associated with carpal-tunnel syndrome. A case report. *J Bone Joint Surg Am*. 1971; 53: 160–162.
- 10 Potu BK, Gorantla VR, Rao MS, Bhat KM, Vollala VR, Pulakunta T, Nayak SR. Anomalous origin of the lumbrical muscles: a study on South Indian cadavers. *Morphologie*. 2008; 92: 87–89.