



Azygos ladder and looped thoracic duct — a case report

Published online April 14th, 2011 © <http://www.ijav.org>

Naveen KUMAR
Sathesha NAYAK B⁺
Surekha SHETTY
SN SOMAYAJI

Department of Anatomy, Melaka Manipal Medical College (Manipal), International Centre for Health Sciences, Manipal University, Madhav Nagar, Manipal, Karnataka State, INDIA.



⁺ Sathesha Nayak B
Professor and Head
Department of Anatomy
Melaka Manipal Medical College (Manipal)
International Centre for Health Sciences
Manipal University, Madhav Nagar
Manipal, Karnataka State, 576104, INDIA.
☎ +91 820 2822518
✉ nayaksathish@yahoo.com

Received August 11th, 2010; accepted April 10th, 2011

ABSTRACT

Knowledge of variations in the posterior mediastinum close to the vertebral column is important for cardiothoracic surgeons, radiologists and orthopedic surgeons. We report variations of azygos veins and thoracic duct. The azygos system of veins showed a ladder pattern. The hemiazygos and accessory hemiazygos veins communicated with the azygos vein through six transverse channels across the vertebral column. The accessory hemiazygos and hemiazygos veins joined to form a common channel which opened into the azygos vein. The thoracic duct gave two branches in the posterior mediastinum and these branches joined to form a loop. © IJAV. 2011; 4: 80–82.

Key words [azygos vein] [hemiazygos vein] [accessory hemiazygos vein] [mediastinum] [thoracic duct]

Introduction

The azygos vein is the vein that drains the thoracic wall and upper lumbar region. It is the important channel connecting the two venae cavae. Its origin is variable. On developmental grounds it should originate from the posterior surface of the inferior vena cava near the renal veins. This is known as lumbar azygos vein. In the absence of lumbar azygos, it is formed by the union of ascending lumbar vein with the right subcostal vein at the T12 vertebra. The azygos vein enters the thorax either by piercing the right crus of the diaphragm or by passing through the aortic opening of the diaphragm. It ascends vertically in the posterior mediastinum in front of the lower 8 thoracic vertebrae. At the level of the T4 vertebra, it arches forwards over the root of right lung and terminates by opening into the superior vena cava. It receives the accessory hemiazygos and hemiazygos veins, right superior intercostal vein, and 5th to 11th posterior intercostal veins of right side. It also receives bronchial, esophageal, pericardial and mediastinal veins.

The thoracic duct is the largest lymphatic channel of the body. It drains the lymph from the both halves of the body below the diaphragm and the left half of the body above the diaphragm. It begins as the continuation of the cisterna chyli near the lower border of T12 vertebra and enters the thorax by passing through the aortic opening. It ascends up in the

posterior mediastinum between azygos vein and descending thoracic aorta, behind the esophagus. It crosses from right to left side at the level of T5 vertebra and ascends in the superior mediastinum to reach the neck. In the neck it arches laterally at the level of the transverse process of C7 vertebra and ends by opening into the junction between left subclavian and internal jugular veins. We noted the variations of azygos system of veins and thoracic duct, which are of importance to surgeons and radiologists.

Case Report

During routine dissection for undergraduate medical students, we found variations of azygos veins and thoracic duct in a male cadaver, aged approximately 65 years. The hemiazygos and accessory hemiazygos veins joined to form a common channel which crossed the vertebral column behind the aorta and oesophagus and terminated into the azygos vein at the level of T8 vertebra (Figure 1). There were four cross-communicating channels between accessory hemiazygos vein and azygos vein, and two with hemiazygos and azygos veins (Figure 1). A total number of six cross-communicating channels and the common channel formed by union of hemiazygos and accessory hemiazygos veins formed a venous ladder in front and to the left of the vertebral column (Figure 1). The accessory hemiazygos vein communicated with the left superior intercostal vein above.

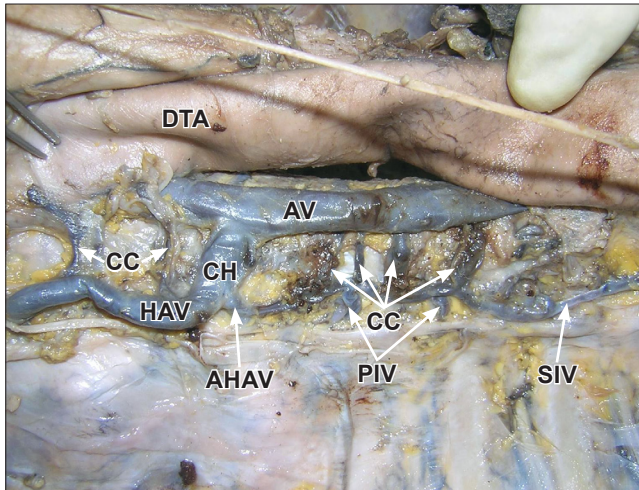


Figure 1. Dissection of the posterior mediastinum showing the azygos and hemiazygos veins. (*DTA*: descending thoracic aorta; *AV*: azygos vein; *CH*: common channel formed by joining of hemiazygos veins; *HAV*: hemiazygos vein; *AHAV*: accessory hemiazygos vein; *CC*: communicating channels between azygos and hemiazygos veins; *SIV*: left superior intercostal vein; *PIV*: posterior intercostal veins)

The thoracic duct divided into two branches at the level of T5 vertebra and the two branches joined each other to form a loop with a diameter of 2.5 cm (Figure 2). The course and relations of the thoracic duct thereafter were as usual.

Discussion

Variations of azygos vein are not very rare [1]. Bergmann et al., have reported variations of azygos veins in 26% of cases [2]. Grzybiak et al., [3] have found the variations of azygos veins in 25% of cases. Presence of preaortic interazygos

vein has been reported in the literature [4]. Presence of such interazygos vein might get damaged during manipulations in the posterior mediastinum as it is a common site of surgical interventions. A case of absence of azygos vein associated with the double superior vena cava has also been reported [5]. The azygos vein may continue as inferior vena cava and open directly in to the right atrium. Absence of superior and inferior venae cavae and azygos continuation of inferior vena has been reported [6]. Absence of accessory hemiazygos vein and termination of left 4-7th posterior intercostal veins into azygos vein has been reported by Quadros et al. [7]. A case of communication between pulmonary veins and azygos vein has been reported by Lapierre et al. [8]. Very rarely the azygos vein may terminate in the left superior vena cava. One such variation has been reported by Uemura et al. [9]. A case of azygos vein dividing into right and left roots and joining right and left superior venae cavae has also been reported [10].

The thoracic duct also shows variations and these variations may cause complications in anterior spine surgeries [11]. One of the rare variations of the thoracic duct is its duplication [12]. In the case of duplication, the two thoracic ducts end at the junction between subclavian and internal jugular veins of the corresponding side. Loukas et al., [13] have done an extensive study on the variations of cisterna chyli. In their study, the cisterna chyli was found in 83.3% of the specimens. Both of its tributaries and the location, with respect to vertebral level, demonstrated wide variations. They found the formation of cisterna chyli by union of left lumbar lymph trunk and intestinal trunk in 45% of cases, by union of right lymphatic duct and intestinal trunk in 20% of cases and by variable confluence of lymphatic trunks in 5% of cases. Thoracic duct may terminate variably. It may terminate into left internal jugular vein, left subclavian vein or right jugulo-subclavian junction [14]. In another study [15], the thoracic duct terminated as a single branch in 84.31% of cases and as two branches in 15.69% of cases.

Though there are several reported variations of azygos system of veins, a 'ladder pattern' as reported here, has not yet been reported. Knowledge of variations of the azygos venous system is necessary since this might be confused with aneurysm, lymphadenopathy and other anomalies like tumor, during radiological investigations [16]. In the current case there were communication channels between azygos and hemiazygos veins. These channels might bleed alarmingly during any surgical interventions in the posterior mediastinum especially close to the vertebral column. The thoracic duct also shows variations in the origin and termination. But the variation in the course is very rare. The looping of the thoracic duct as reported here is a very rare variation and it might get damaged during anterior spine surgeries and result in chylothorax. Hence the variations reported here could be of importance for radiologists, orthopedic surgeons and cardiothoracic surgeons.

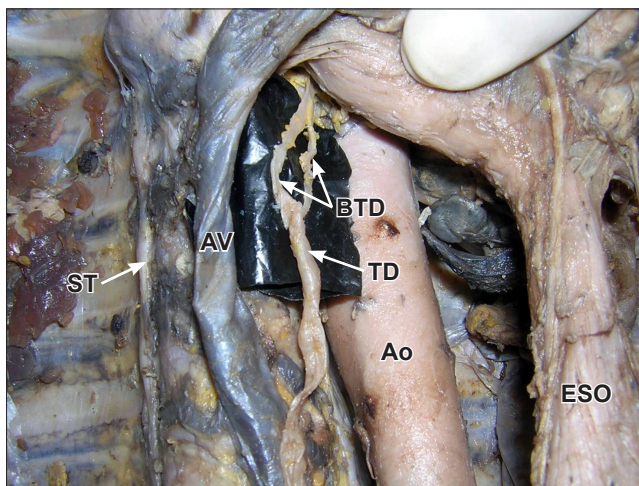


Figure 2. Dissection of the posterior mediastinum showing the loop of thoracic duct. (*TD*: thoracic duct; *BTD*: branches of thoracic duct joining to form a loop; *AV*: azygos vein; *ST*: sympathetic trunk; *Ao*: aorta; *ESO*: esophagus)

References

- [1] Mezzogiorno A, Passiatore C. An atypical pattern of the azygos venous system in man. *Anat Anz*. 1988; 185: 277–281.
- [2] Bergman RA, Afifi AK, Miyauchi R. Illustrated Encyclopedia of Human Anatomic Variation: Opus II: Cardiovascular System: Veins: Head, Neck, and Thorax. Azygos vein. <http://www.anatomyatlases.org/AnatomicVariants/Cardiovascular/Text/Veins/Azygos.shtml> (accessed August 5th, 2010)
- [3] Grzybiak M, Szostakiewicz-Sawicka H, Tredler A. Remarks on pathways of venous drainage from the left upper intercostal spaces in man. *Folia Morphol (Warsz)*. 1975; 34: 301–313.
- [4] Das S, Paul S. Preaortic interazygos vein: a case report. *Braz J Morphol Sci*. 2044; 21: 141–143.
- [5] Arslan G, Ozkaynak C, Cubuk M, Sindel T, Luleci E. Absence of the azygos vein associated with double superior vena cava – a case report. *Angiology*. 1998; 50: 81–84.
- [6] Quraishi MB, Muti O, Wase A. Absent left and right superior vena cava and azygos continuation of inferior vena cava: a rare anomaly of systemic venous return. *J Invasive Cardiol*. 2010; 22: E159–161.
- [7] Quadros LS, Potu BK, Guru A, Pulakunta T, Ray B, D'Silva SS, Sequeira S, Thomas H. Anomalous azygos venous system in a south Indian cadaver: a case report. *Cases J*. 2009; 2: 6746.
- [8] Lapierre C, Siles A, Bigras JL. Partial anomalous pulmonary venous return to the azygos vein: an unusual case. *Pediatr Cardiol*. 2010; 31: 749–750.
- [9] Uemura M, Takemura A, Ehara D, Yasumitsu H, Ohnishi Y, Suwa F. Left superior vena cava with left azygos vein. *Okajimas Folia Anat Jpn*. 2009; 86: 55–60.
- [10] Gesase AP, Fabian FM, Ngassapa DN. Double superior vena cava presenting with anomalous jugular and azygos venous systems. *Indian Heart J*. 2008; 60: 352–356.
- [11] Akcali O, Kiray A, Ergur I, Tetik S, Alici E. Thoracic duct variations may complicate the anterior spine procedures. *Eur Spine J*. 2006; 15: 1347–1351.
- [12] Chen H, Shoumura S, Emura S. Bilateral thoracic ducts with coexistent persistent left superior vena cava. *Clin Anat*. 2006; 19: 350–353.
- [13] Loukas M, Wartmann CT, Louis RG Jr, Tubbs RS, Salter EG, Gupta AA, Curry B. Cisterna chyli: A detailed anatomic investigation. *Clin Anat*. 2007; 20: 883–888.
- [14] Pena E, Zuniga J. An anatomical variation: the aberrant termination of the thoracic duct. *Biomedica*. 2009; 29: 204–208. (Spanish)
- [15] Zorzetto NL, Ripari W, De Freitas V, Seullner G. Anatomical observations on the ending of the human thoracic duct. *J Morphol*. 1977; 153: 363–369.
- [16] Kocabiyik N, Kutoglu T, Albay S, Yalcin B, Ozan H. Azygos vein system abnormality: case report. *Gulhane Tip Dergisi*. 2006; 46: 180–182.