



Atypical branching of superior mesenteric artery

Published online February 14th, 2013 © <http://www.ijav.org>

Biswa Bhusan MOHANTY¹✉
 Divya AGRAWAL¹
 Sunita SETHY²
 Prafulla Kumar CHINARA¹

Department of Anatomy, IMS & SUM Hospital, SOA University, Bhubaneswar 11, SCB Medical College, Utkal University, Cuttack 12, INDIA.



✉ Dr. Biswa Bhusan Mohanty
 Assistant Professor
 Department of Anatomy
 IMS & SUM Hospital, K-8
 Kalinganagar, B.O. Ghatikia
 Bhubaneswar, 751003, INDIA.
 ☎ +91 977 6003975
 ✉ biswamohanty16@gmail.com

Received January 12th, 2012; accepted September 22nd, 2012

Abstract

Routine dissection of a 50-year-old male cadaver revealed the unusual branching pattern of superior mesenteric artery showing the absence of right colic and inferior pancreaticoduodenal arteries, but inferior mesenteric artery was normal.

The entire jejunum-ileum was supplied by superior mesenteric artery which arose typically from abdominal aorta. It gave off branches on the right side, i.e. the right colic artery, ileocolic artery. The main stem of superior mesenteric artery terminated by anastomosing with the ileal branch of the ileocolic artery. Out of all the branches, right colic artery is the most variable branch which varies in its origin and even sometimes may be absent. Though these variations do not show any impact on the normal blood supply of the midgut, they exhibit variation in the continuity of the marginal artery of Drummond. Hence, having an idea on anatomical variations of the artery helps the surgeon a lot.

© *Int J Anat Var (IJAV)*. 2013; 6: 26–27.

Key words [superior mesenteric artery] [gut] [anastomose]

Introduction

Superior mesenteric artery is the artery of midgut. It supplies all the derivatives of midgut, namely duodenum below the opening of bile duct, jejunum, ileum, appendix, caecum, ascending colon, right two-third of transverse colon and lower half of head of pancreas.

The superior mesenteric artery originates from the aorta about 1 cm below the coeliac trunk at the level of the intervertebral disc between the first and second lumbar vertebrae. It runs inferiorly and anteriorly, anterior to the uncinate process of the pancreas and the third part of the duodenum and posterior to the splenic vein and body of pancreas. As it descends in the root of mesentery, it crosses anterior to the inferior vena cava, right ureter and right psoas major. The caliber of the vessel steadily decreases as branches are given off to the loops of jejunum and ileum. It ends in a terminal branch which anastomoses with the ileocolic artery. The superior mesenteric artery gives off the middle colic, right colic, ileocolic, jejunal and ileal branches.

The inferior mesenteric artery is the artery of hindgut and it supplies left one-third of transverse colon, descending colon, sigmoid colon, rectum and part of anal canal above the anal valves. The inferior mesenteric artery arises from the anterior or left anterolateral aspect of the aorta at about the level of third lumbar vertebra 3 or 4 cm above the aortic bifurcation

and posterior to the horizontal part of duodenum. It descends deep to the peritoneum initially anterior and then to the left of aorta. It crosses the origin of left common ileac artery medial to the left ureter and then continues in the root of sigmoid mesocolon as superior rectal artery. The principal branches are the left colic, sigmoid and superior rectal artery.

Case Report

During routine dissection of a 50-year-old male cadaver in the Department of Anatomy at IMS and SUM Hospital, a variation in the distribution of superior mesenteric artery was found. The case was thoroughly dissected, displayed and photographed. Superior mesenteric artery was seen to be dividing into ileocolic and middle colic arteries on the right side, and many ileal and jejunal branches on the left side. The right colic and the inferior pancreaticoduodenal arteries were absent. The ileocolic artery was seen as the distal continuation of the superior mesenteric artery in the root of the mesentery after the origin of the last ileal artery. The middle colic artery which is one of the first branches of superior mesenteric artery was arising just inferior to the uncinate process of pancreas and ascending in the root of transverse mesocolon slightly to the left of midline (Figure 1). On the other hand, inferior mesenteric artery was absolutely normal having the usual branching pattern.

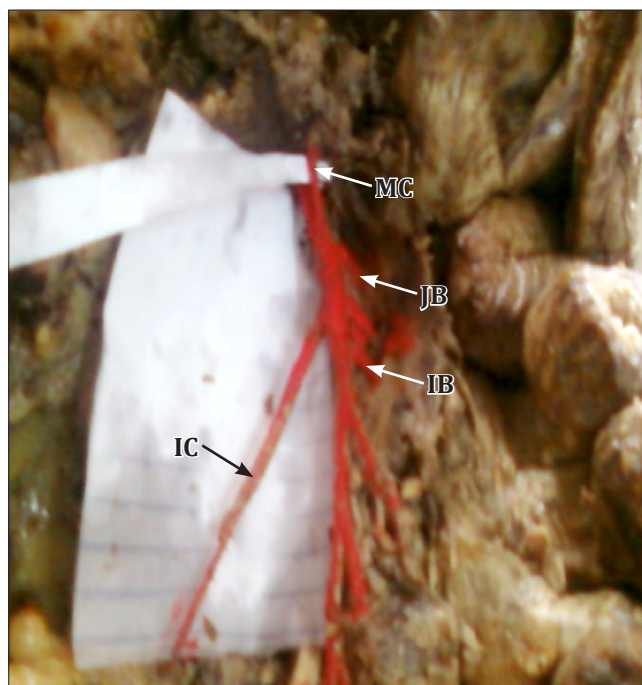


Figure 1. Photograph of branching pattern of superior mesenteric artery as observed. (IC: ileocolic artery; MC: middle colic artery; JB: jejunal branches; IB: ileal branches)

Discussion

Superior mesenteric artery is the main artery of midgut. It gives out four branches namely right colic, ileocolic, middle colic and inferior pancreaticoduodenal arteries, out of which right colic artery is the most variable branch. Most commonly it arises from right side of superior mesenteric artery (50%), but it may also arise from middle colic artery (30%) or from ileocolic artery (12%). When it arises from ileocolic artery, it is called as accessory right colic artery. In 18% cases there may be no branch corresponding in course and distribution to right colic artery; in that case a vessel to the ascending colon is present and is then designated as right colic artery [2]. The right colic artery runs transversely, downwards towards ascending colon. As it approaches medial margin of ascending colon, it divides into ascending and descending

branch. The ascending branch anastomoses with the right branch of middle colic artery and the descending branch anastomose with the colic branch of ileocolic artery. In general, the right colic artery supplies the upper two-third of ascending colon and a small right portion of transverse colon.

Middle colic artery normally arises from superior mesenteric artery (88%) when it lies behind the pancreas or as it emerges at the lower border of pancreas, but it may arise in common with inferior pancreatico-duodenal artery [1] or in common with right colic artery (25%). A variable distance from the wall of colon which may vary from 3–11 cm, usually it is about 5–7 cm. The artery divides into right and left branches. But sometimes it may divide into three branches. The right branch anastomoses with ascending branch of right colic artery, and the left branch anastomose with ascending branch of left colic artery. It is found that in 9% cases, an accessory ileocolic artery arise from superior mesenteric artery and in 3% cases, there may be no middle colic artery where it is replaced by a large branch from left colic artery [3].

Ileocolic artery arises from the right side of superior mesenteric artery (63%). It runs diagonally towards right and downwards to end by branching above the ileocecal junction. It gives off five branches namely anterior and posterior caecal, appendicular, ileal branch and colic branches. Sometimes, a branch from it also supplies the gall bladder [3].

Sometimes, hepatic artery arises from superior mesenteric artery [7]. Rarely inferior mesenteric artery arises from superior mesenteric artery [4, 6]. In some cases, hepatic arises from superior mesenteric artery [5].

Conclusion

Detailed knowledge of the different anatomical variations of the superior mesenteric artery is of extreme clinical importance, particularly, when performing laparoscopic surgery, and radiological procedures in the abdomen, and in surgical procedures such as right hemicolectomy, resection of the transverse colon and en bloc resection of the head of the pancreas. The study of superior mesenteric vessels is of much importance when pancreatic head carcinoma invades the superior mesenteric vein.

References

- 11 Hollinshead WH. *Anatomy for Surgeons. Vol. 2. The thorax, abdomen and pelvis.* New York, Hoeber-Harper Book. 1961; 502.
- 12 Steward JA, Rankin FW. Blood supply of the large intestine: its surgical consideration. *Arch Surg.* 1933; 26: 843–891.
- 13 Katada Y, Kishino M, Ishihara K, Takeguchi T, Shibuya H. Anomalous arterial supply to the gallbladder from the superior mesenteric artery: angiography and computed tomography findings in two cases. *Acta Radiol.* 2008; 49: 987–990.
- 14 Yoo SJ, Ku MJ, Cho SS, Yoon SP. A case of the inferior mesenteric artery arising from the superior mesenteric artery in a Korean woman. *J Korean Med Sci.* 2011; 26: 1382–1385.
- 15 Osawa T, Feng XY, Sasaki N, Nagato S, Matsumoto Y, Onodera M, Nara E, Fujimura A, Nozaka Y. Rare case of the inferior mesenteric artery and the common hepatic artery arising from the superior mesenteric artery. *Clin Anat.* 2004; 17: 518–521.
- 16 Kitamura S, Nishiguchi T, Sakai A, Kumamoto K. Rare case of the inferior mesenteric artery arising from the superior mesenteric artery. *Anat Rec.* 1987; 217: 99–102.
- 17 Jimura A, Oguchi T, Shibata M, Takahashi T. An anomalous case of the hepatic artery arising from the superior mesenteric artery. *Okajimas Folia Anat Jpn.* 2007; 84: 61–65.