



Case Report

Asymmetrical bilateral ossification of stylohyoid chains — a case report with embryological review

Published online July 7th, 2011 © <http://www.ijav.org>Pranab MUKHERJEE^[1] +Sukanya PALIT^[2]Arunabha TAPADAR^[1]Hironmoy ROY^[1]

Department of Anatomy, North Bengal Medical College, Siliguri [1], Department of Anatomy, Midnapore Medical College, Paschim Medinipur [2], WB, INDIA.



+ Dr. Pranab Mukherjee
Associate Professor
Department of Anatomy
North Bengal Medical College
Siliguri, WB, INDIA.
☎ +91 943 4568024
✉ pranabanatomy@gmail.com

Received March 30th, 2011; accepted June 26th, 2011

ABSTRACT

‘Stylohyoid chain’ consisting of the four parts as cranio-caudally as tympanohyal, stylohyal, ceratohyal and hypohyal parts having same embryological origin existing as proximally ossified as styloid process, and distal stylohyoid ligament, which seldom gets ossified heralding severe pharyngeal pain, dysphagia as well as dysphonia. The present report is a follow-up history of a young lady of 26 years presenting with foreign body sensation and vague pain in the throat for last two years more to the left side and subsequently diagnosed to have asymmetrically ossified or calcified stylo-hyoid chain in digital x-ray of the skull. Detailed study of the calcified stylohyoid chain revealed bilateral different pattern, which is quite rare as searched for. Resection was done for excess styloid processes in two settings of one-year gap by intraoral approach. Symptoms subsided in post-operative period. © IJAV. 2011; 4: 134–136.

Key words [elongated styloid process] [stylalgia] [stylohyoid chain]

Introduction

Styloid process is the bony projection from the base of the skull closely related to the stylo-mastoid foramen. Its normal length varies from 2.5–3 cm with mean of 2.8 cm. It has two embryological parts as tympanohyal in proximal and stylohyal distally. Tympanohyal part ossifies before birth, whereas that for stylohyal part occurs after birth. Stylohyoid ligament connects the styloid process with the lesser horn of the hyoid bone. All three structures, i.e. styloid process, stylohyoid ligament and lesser horn of the hyoid bone are derived from the cartilaginous element of the second branchial arch (Reichert’s cartilage) and altogether constitute the ‘stylohyoid chain’ or ‘stylohyoid complex’ [1].

Length of the styloid process when exceeds 3 cm it is said to be elongated and often found in 4% individual [2, 3]. Clusters of symptoms produced by elongated styloid process include foreign body sensation in the neck, hypersalivation, dysphagia as described by Eagle in 1937 as ‘Eagle’s syndrome’ [4]. Bilateral elongation was noted in only 50% of patients having Eagle’s Syndrome and only half of them had bilateral symptoms as reported by Harma [5]. Keur et al. assessed 1135 edentulous patients clinically and radiologically to establish relationship between cause and symptoms [6].

Bafaqueeh described two different groups of patients according to symptoms. First one is called ‘classical type’

with pharyngeal pain and other is the ‘carotid artery type’ with repeated syncopal attack and ipsilateral pain in the side of the neck [7].

Case Report

A 24-year-old female presented with foreign body sensation in throat more to the left side along with dysphagia and excessive salivation, vague pharyngeal pain radiating to mastoid region aggravating on rotation of head for about last two years. Palpation of the tonsillar fossa revealed elongated styloid process on both sides. On injecting 1% lignocaine (0.5 ml) temporarily could reduce the pain through the anterior pillar of the tonsillar fossa, supporting the diagnosis of stylalgia. Digital x-ray of the skull revealed asymmetrical ossification of bilateral stylohyoid chains. In the left side it was of two components with long styloid process as proximal and calcified stylohyoid ligament as distal part having total length of 4.7 cm (approximately) with prominent ‘pseudoarticulation’. On the other hand, that on right side with totals 4.5 cm (approximately) length having distal portion as calcified stylohyoid ligament, but the proximal elongated styloid process is again divided in two parts representing its tympanohyal and stylohyal components (Figures 1 and 2).

Palpation through the tonsillar fossa confirmed the situation. Symptoms of the left side was well collaborated with the more

elongated structure. An intra-oral approach for resection of excess bony projection was planned by ENT surgeon after checking the complete hemogram, ASO titer and C reactive protein test. During operation a first routine tonsillectomy was done followed by proper achievement of hemostasis by ligating the paratonsillar vein. Anatomical structures like the superior constrictor muscle and the buccopharyngeal fascia were retracted to expose the styloid process (Figure 3). On seeing the styloid process, approximately 2 cm of it was resected. Postoperative period was uneventful. Symptoms subsided on the operated side. Follow up was done by the team as the case was anatomically and embryologically unique. After one year the patient presented with aggravated symptoms as earlier on the right side and resection was done by similar approach. Gradually the patient became absolutely free of any symptoms.

Discussion

The entire 'stylohyoid chain' can be zoned as the tympanohyal (part enclosed by vaginal plates), stylohyal (forming major portion of styloid process), ceratohyal (the stylohyoid ligament) and hypohyal part (which is actually the minor horn of hyoid bone) [2].

Pathogenesis of elongation and mineralization of the stylohyoid chain is poorly understood as described in

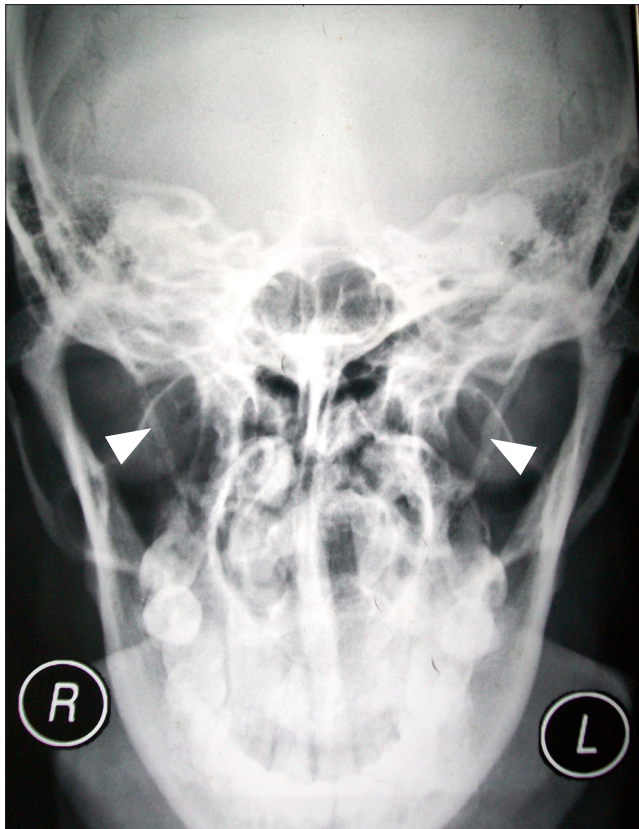

Figure 1. Photograph shows the bilateral asymmetrical ossification of the stylohyoid chain (*white arrowheads*).

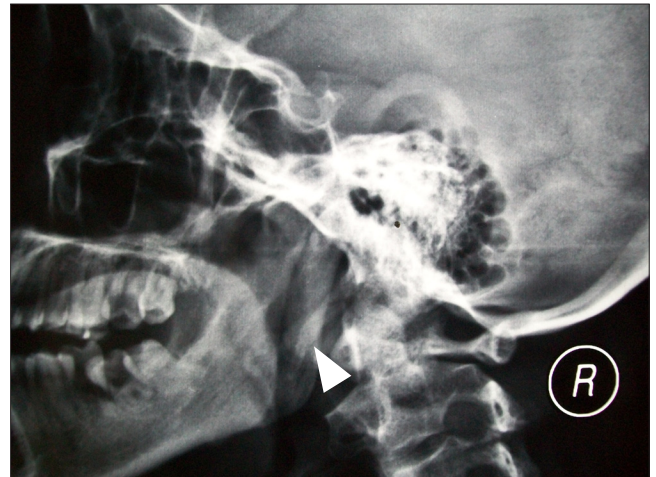

Figure 2. Photograph shows the pseudo-articulation of proximal and distal parts of ossified right stylohyoid chain (*white arrowhead*).

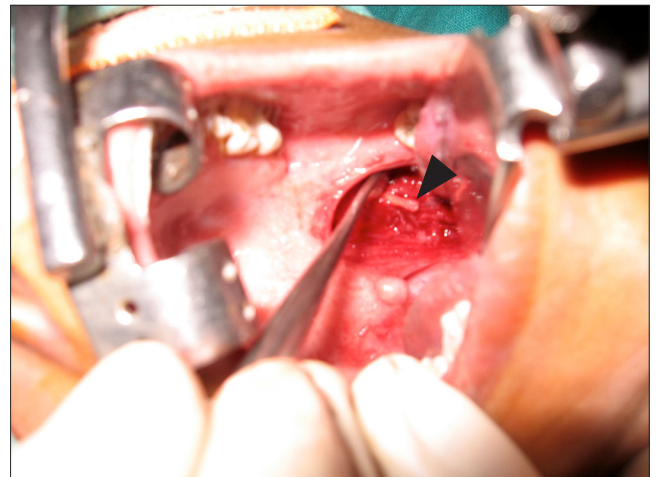


Figure 3. Intra-operative photograph showing the exposure of the left elongated styloid process just before resection (*black arrowhead*).

literature [8]. Some authors opined it as the degenerative change running with the spondylosis of cervical vertebra [9], which again got contradicted by others as a non-age dependent degeneration [10].

There are some theories supporting the fact as congenital elongation of the styloid process due to persistence of the cartilaginous analog in stylohyal, calcification of stylohyoid ligament, and thirdly, the growth of osseous tissue at the insertion in the stylohyoid ligament referred as 'calcification tendonitis' may be the cause of such. In the adult the styloid ligament, normally composed of dense fibrous connective tissue may retain some of its embryonic cartilage and this has the potential to become partially or completely ossified [11].

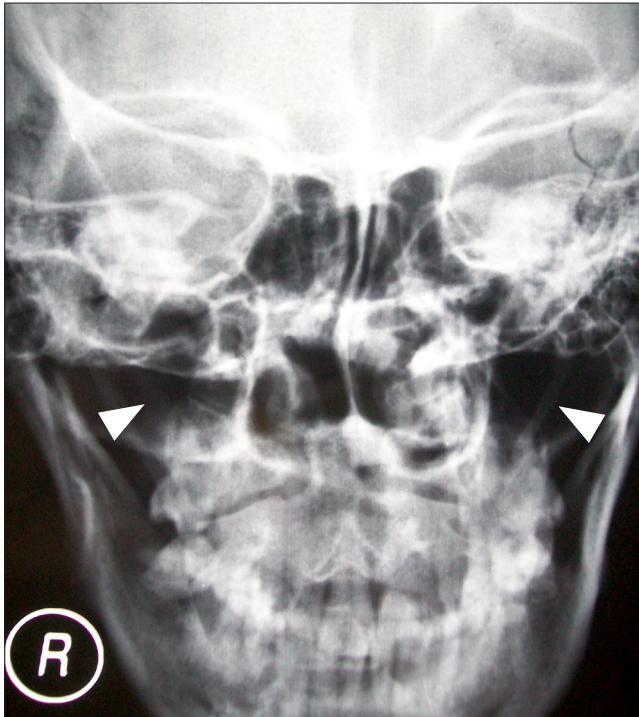


Figure 4. Post-operative photograph of the patient showing the left over periosteum of the stylohyoid chains (white arrowheads).

Langlais et al. described an elongated and mineralized stylohyoid complex and proposed classification with a case report [12]. Digital x-ray of the present case shows that on the left side styloid process and the stylohyoid ligament overlap each other at the point described by, which present a pseudoarticular variety i.e. Type- II. On the right side the pattern is quite different where there were three separate non-continuous components, i.e. tympanohyal, stylohyal and stylohyoid ligament (ceratohyal) were vivid belonging to Type-III category. Such a bilateral asymmetrical ossification of the stylohyoid chain is extremely rare as sorted in current literature.

References

- [1] Collins P. Second pharyngeal arch. Embryology & Development. Williams P, Bannister L, Collins P, Dyson M, Dussek J, Ferguson M, eds. Gray's Anatomy. 38th. Ed., Philadelphia, Churchill Livingstone, 1995; 284.
- [2] Magotra R, Razdan S. Elongated styloid process: anatomical variations. JK Science: Journal of Medical Education & Research. 2008; 20: 203–205.
- [3] Hollinshead WH. Anatomy for Surgeons. 3rd Ed., Philadelphia. J.B. Lippincott Co. 1982; 52–53.
- [4] Eagle WW. Elongated styloid process. Arch Otolaryngol. 1937; 25: 584–587.
- [5] Harma R. Stylogia: clinical experiences of 52 cases. Acta Otolaryngol. 1966; Suppl 224: 149–155.
- [6] Keur JJ, Campbell JP, McCarthy JF, Ralph WJ. The clinical significance of the elongated styloid process. Oral Surg Oral Med Oral Pathol. 1986; 61: 399–404.
- [7] Bafaqeh SA. Eagle syndrome: classic and carotid artery types. J Otolaryngol. 2000; 29: 68–64.
- [8] Murtogh RD, Caracciolo JT, Fernandez G. CT findings associated with Eagle syndrome. AJNR Am J Neuroradiol. 2001; 22: 1401–1402.
- [9] Guo B, Jaovisitha S, Sartoris DJ, Ryu KN, Berthiaume MJ, Clopton P, Brossman J, Resnick D. Correlation between ossification of the stylohyoid ligament and osteophytes of the cervical spine. J Rheumatol. 1997; 24: 1575–1581.
- [10] Chandler JR. Anatomical variations of the stylohyoid complex and their clinical significance. Laryngoscope. 1977; 87: 1692–1701.
- [11] Bozkir MG, Boga H, Dere F. The evaluation of elongated styloid process in panoramic radiograph in edentulous patients. Tr J Med Sci. 1999; 29: 481–485.
- [12] Langlais RP, Miles DA, Van Dis ML. Elongated and mineralized stylohyoid ligament complex: a proposed classification and report of a case of Eagle's syndrome. Oral Surg Oral Med Oral Pathol. 1986; 61: 527–532.
- [13] Strauss M, Zohar Y, Laurian N. Elongated styloid process syndrome: intraoral versus external approach for styloid surgery. Laryngoscope. 1985; 95: 976–979.
- [14] Infante-Cossío P, García-Perla A, González-García A, Gil-Peralta A, Gutiérrez-Pérez JL. Compression of the internal carotid artery due to elongated styloid process. Rev Neurol. 2004; 39: 339–343. (Spanish)

As in this case patients with elongated styloid process as well as the ossified entire chain usually present with symptoms like glossopharyngeal neuralgia, otalgia, pharyngeal pain, carotidynia, dysphonia, dysphagia which can be explained with their intimate anatomical relationship with glossopharyngeal nerve and indirect irritation of chorda tympani, auriculotemporal, vagus nerves.

Precise measurement of the length and angulations could not be measured due to infrastructural limitation. So far the surgical approaches are concerned, it has been described that the intraoral and extra-oral approaches have some advantages and disadvantages. But truly speaking intraoral approach is cosmetically better; though it has increased risk of hemorrhage and infections so far the limited dissection field is concerned demanding more precautions. But being cosmetically more acceptable it is preferred for women and so why it is done in present case [13]. Extra-oral approach is specifically chosen in 'carotid artery type' (neurovascular variant), where tip of the styloid process compresses the sympathetic plexus and the internal carotid artery [14].

Conclusion

Elongated styloid process or the calcified stylohyoid chain should always be considered in differential diagnosis of cervico-facial pain. Bilateral existence of it is though reported in some articles but bilateral asymmetrical pattern never found in literature till searched for. For anatomical point of view digital radiograph and CT scan with Doppler study can be applied to relate compression caused by the various structures. Though to avoid hemorrhage the extra-oral approach is done, but cosmetically intra-oral approach is more acceptable, until demanded by the condition.

Acknowledgement

Authors sincerely acknowledge Prof. Tapas Bhattacharya, Principal of N.B. Medical College, Prof. Amit Mallik, HOD and other faculties of the Department of Anatomy of N.B. Medical College and Dr. Ranjal Pal, ENT surgeon for their necessary helps, guidance and permissions.