

Aneurysm of abdominal aorta in a young woman aged 27 years

Barry Ibrahim Sory¹, Camara Abdoulaye^{1*}, Samoura Aly¹, Samoura Sana¹, Sylla Djibril², Koivogui Diarra¹, Doumbouya Mohamed¹, Soumaoro Morlaye¹, Balde Elhadj Yaya¹, Beavogui Mariama¹, Balde Mamadou Dadhi¹, Conde Mamady¹

Sory BI, Abdoulaye C, Aly S, et al. Aneurysm of abdominal aorta in a young woman aged 27 years. Clin Cardiol J. 2019;3(1):25-26.

AIM: The purpose of this study is to describe abdominal aortic aneurysm in a 27-year-old hypertensive woman.

CASE PRESENTATION: The patient is a 27-year-old female, hypertensive housewife, since 1 year and seen for palpitations, epigastric pain, headache, buzzing ears. Evolution: 1 month. Cardiovascular risk factor: hypertension. Cardiac Auscultation, BDC regular at 100 bpm with a B2 flush at the aortic focus. 170/100 mmHg blood pressure with both arms. Soft abdomen with

a moving painful moving mass sitting at the epigastrium whose auscultation finds a systolic diastolic murmur. The rest of the exam is peculiar.

CONCLUSION: Aneurysm of the abdominal aorta is a pathology rarely diagnosed in our environment and yet frequently associated with atheroma risk factors. It must be suspected in front of a pulsatile abdominal mass to be confirmed by abdominal ultrasound. Thus, the ideal treatment remains surgical.

Key Words: Aneurysm; Aorta; Abdominal; Young; Female; Guinea Conakry

INTRODUCTION

Abdominal aortic aneurysm (AAA) is a severe vascular disease that consists of a permanent, localized dilatation of the aorta with a diameter exceeding 3 cm. AAA is 3 to 11 times more common among men than women, with prevalence among people over 50 ranging from 4.2% to 8.8% and 0.6% to 1.4% respectively (1).

CASE PRESENTATION

The patient is a 27-year-old female hypertensive housewife known since 1 year for palpitations, epigastric pain, headache, buzzing ears. Evolution 1 month. Cardiovascular risk factor: hypertension. Cardiac Auscultation, BDC regular at 100 bpm with a B2 flush at the aortic focus. 170/100 mmHg blood pressure with both arms. Soft abdomen with a moving painful moving mass sitting at the epigastrium whose auscultation finds a systolic diastolic murmur. The rest of the exam is peculiar.

RESULTS

Electrocardiogram: Records left ventricular hypertrophy.

Front chest X-ray: Shows aortic flow (Figure 1).

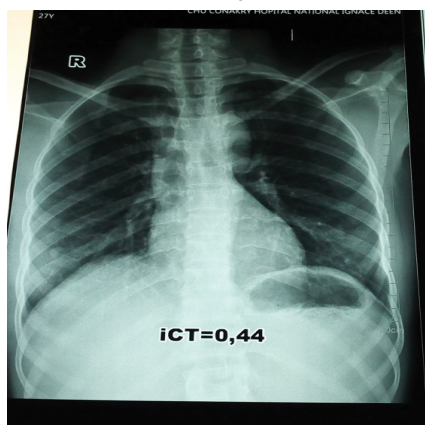


Figure 1) Telescope chest showing an aortic procedure

Abdominal ultrasound: concludes a huge aneurysmal arteriovenous sac at the expense of the abdominal aorta and vena cava measuring 6.50 cm × 5.87 cm (Figure 2).

Biology: Without particularity

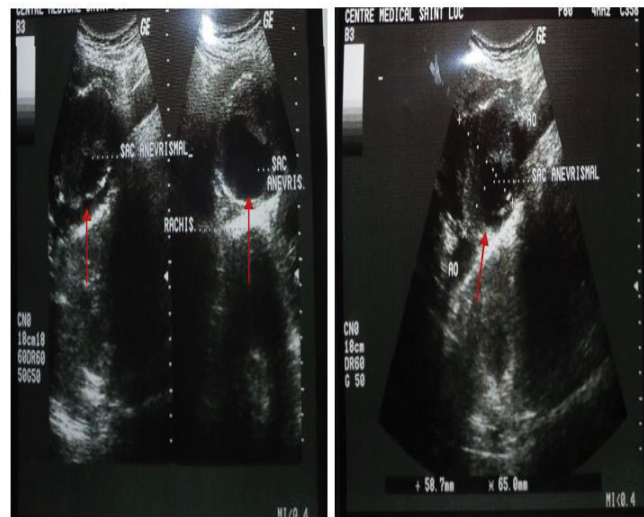


Figure 2) Abdominal ultrasound showing a huge aneurysm sac.

DISCUSSION

We report the case of a hypertensive 27-year-old woman who had an abdominal aortic aneurysm suspected clinically and confirmed by abdominal ultrasonography.

Studies in various European countries and in the United States estimate that the prevalence of AAA is between 4.2 and 8.8% for men, and between 0.6 and 1.4% for women over 50 years old (2,3). Etiologies include atheroma, syphilis, trauma, congenital and inflammatory arteritis (Takayashu's, Horton's, Kawasaki's disease) (4). Whatever the cause and location, the aortic aneurysm is a life-threatening threat because of the risk of rupture (5).

Age, male sex, high blood pressure, smoking, and family history are the main factors associated with AAA (6-8). On the contrary, diabetes is a protective factor for the evolution of aneurismal disease because it increases arterial resistance (4). In our patient, the associated cardiovascular risk factor (FRCV) is arterial hypertension discovered for 2 years. Indeed, these FRCV promotes the development and progression of atheroma which is the most common etiology of AAA.

¹Cardiac Service, Ignace Deen CHU, Conakry, Republic of Guinea, ²Medico-surgical Emergency Service of Donka, Republic National Hospital of Guinea, Republic of Guinea.

Correspondence: Camara Abdoulaye, Cardiac Service, Ignace Deen CHU, Conakry, Republic of Guinea, Telephone +(224) 621226681, e-mail: mariboudou@gmail.com

Received: July 01, 2019, Accepted: August 22, 2019, Published: August 30, 2019



This open-access article is distributed under the terms of the Creative Commons Attribution Non-Commercial License (CC BY-NC) (<http://creativecommons.org/licenses/by-nc/4.0/>), which permits reuse, distribution and reproduction of the article, provided that the original work is properly cited and the reuse is restricted to noncommercial purposes. For commercial reuse, contact reprints@pulsus.com

Aneurysms constitute an atheroma zone because atherosclerosis is accompanied by a modification of the mechanical properties of the arterial wall with formation of a zone of less resistance linked to the destruction of the elastic fibers of the media, which favors the dilatation of the vessels (4).

In the majority of cases, AAA is asymptomatic and accidentally discovered during a systematic review (4). In our case the patient complained of epigastric pain and palpitations. Abdominal aneurysm can be detected by bimanual palpation of a pulsatile mass located between the xiphoid appendage and the umbilicus (9). In our patient palpation revealed a beating mass at the epigastrium with a systole-diastolic murmur. Universally available abdominal ultrasound has emerged as the simplest, least invasive and most reproducible method, not only to detect an aneurysm in an obese patient, but also to assess its exact size in all patients. Only anteroposterior and transverse diameters should be retained (9). In our case the abdominal ultrasound shows a huge arteriovenous aneurysmal sac at the expense of the abdominal aorta and the vena cava measuring 6.50 cm × 5.87 cm as shown in Figure 2.

The natural course of AAA is characterized by progressive structural deterioration of the aortic wall associated with a gradual expansion of the aneurysm by about 10% per year (10) and eventual rupture.

All aneurysms do not rupture at the time of diagnosis, about 80% of the aneurysms are asymptomatic, 15% are symptomatic, and 5% are broken. In fact, rupture is the most serious complication, since it results in death in almost 50% of patients who come to life in hospital (11).

Three treatment options are available to patients with AAA: open surgery, endovascular repair, or optimized medical treatment (active surveillance and risk factor control). The choice of one or the other of the options depends on the patient's state of health (age, general condition and life expectancy), eligibility for open surgery, AAA characteristics (height, pace growth and morphology) and symptomatology. Although the traditional treatment of AAA greater than 5 cm is mainly surgical, medical treatment to slow down its growth rate is being studied more and more (12-15). In our patient we have initiated a drug treatment based on a beta blocker non-cardio selective type Atenolol 50 mg per day and a statin type Atorvastatin 40 mg per day pending surgery. In our environment, cardiovascular surgery is a real stumbling block in the management of cardiovascular diseases like this one.

CONCLUSION

Aneurysm of the abdominal aorta is a pathology rarely diagnosed in our environment and yet frequently associated with atheroma risk factors. It must be suspected in front of a pulsatile abdominal mass to be confirmed by abdominal ultrasound. Thus, the ideal treatment remains surgical.

REFERENCES

1. Brigitte C, Jean-Marie RL, Michel L. Systematic screening of abdominal aortic aneurysm by ultrasound, *ETMIS* 2010;6:1.
2. Derubertis BG, Trocciola SM, Ryer EJ, et al. Abdominal aortic aneurysm in women: Prevalence, risk factors, and implications for screening. *J Vasc Surg* 2007;46:630-5.
3. Jamrozik K, Norman PE, Spencer CA, et al. Screening for abdominal aortic aneurysm: Lessons from a population-based study. *Med J Aust* 2000;173:345-50.
4. Besse B, Lellouche N, Attias D. National classifying trial, cardiology and vascular diseases; aneurysm of the abdominal aorta. 2006;489-91.
5. Calligaro KD, Dougherty MJ, Hollier LH. Diagnosis and treatment of aortic and peripheral arterial aneurysms. W.B. Saunders Co. Philadelphie, 1999;19106.
6. Le Maire SA, Russell L. Epidemiology of thoracic aortic dissection. *Nat Rev Cardiol* 2011;8:103-13.
7. Golledge J, Eagle KA. Acute aortic dissection. *Lancet* 2008;372:55-66.
8. Landenhed M, Engström G, Gottsäter A, et al. Risk profiles for aortic dissection and ruptured or surgically treated aneurysms: a prospective cohort study. *J Am Heart Assoc* 2015;4:e001513.
9. Alain V. Aneurysms of the thoracic and abdominal aorta: a clinical surgeon's point of view, the clinician. 2002.
10. Bengtsson H, Bergqvist D, Ekberg O, et al. A population based screening of abdominal aortic aneurysms (AAA). *Eur J Vasc Surg* 1991;5:53-7.
11. Tambyraja A, Murie J, Chalmers R. Predictors of outcome after abdominal aortic aneurysm rupture: Edinburgh Ruptured Aneurysm Score. *World J Surg* 2007;31:2243-7.
12. Guessous I, Periard D, Lorenzetti D, et al. The efficacy of pharmacotherapy for decreasing the expansion rate of abdominal aortic aneurysms: A systematic review and meta-analysis. *PLoS ONE* 2008;3:e1895.
13. Aoki H, Yoshimura K, Matsuzaki M. Turning back the clock: Regression of abdominal aortic aneurysms *via* pharmacotherapy. *J Mol Med* 2007;85:1077-88.
14. Golledge J, Powell JT. Medical management of abdominal aortic aneurysm. *Eur J Vasc Endovasc Surg* 2007;34:267-73.
15. Rentschler ME, Baxter BT. Medical therapy approach for treating abdominal aortic aneurysm. *Vascular* 2007;15:361-5.