



Case Report

Anatomical variations in the ulnar nerve and hypothenar muscles

Published online July 1st, 2011 © <http://www.ijav.org>Mounir N. GHABRIEL ⁺

Philip H. MAKAR

Discipline of Anatomy and Pathology, School of Medical Sciences, The University of Adelaide, South Australia, AUSTRALIA.



⁺ Mounir N Ghabriel
Associate Professor
Discipline of Anatomy and Pathology
School of Medical Sciences
The University of Adelaide
South Australia 5005, AUSTRALIA.
☎ +618 8303 5481
✉ mounir.ghabriel@adelaide.edu.au

Received April 13th, 2011; accepted May 25th, 2011

ABSTRACT

Trifurcation of the ulnar nerve proximal to Guyon's canal was seen in the left hand of a cadaver. The nerve divided into deep and superficial divisions and a separate muscular branch that supplied three heads for the abductor digiti minimi. An unusual loop of the dorsal cutaneous branch of the ulnar nerve communicated with this muscular branch and with the digital sensory branches of the superficial division of the ulnar nerve. The connection to the muscular branch is novel and has not been described previously. The abductor digiti minimi had three overlapping heads. The median nerve above the flexor retinaculum appeared on the ulnar side of a radially positioned palmaris longus tendon. These combinations of neuromuscular variations are essential knowledge that should be made available to surgeons and practitioners. © IJAV. 2011; 4: 131–133.

Key words [ulnar nerve] [deep branch] [dorsal branch] [abductor digiti minimi] [hand surgery]

Introduction

Variations in the ulnar nerve have been reported in cadaveric dissections [1, 2] and clinical practice [3, 4]. Variant communications from the dorsal cutaneous branch of the ulnar nerve to the sensory palmar digital branches or rarely with the motor division of the ulnar nerve have been described [3, 5]. In the current study a novel variant of the ulnar nerve was discovered in a cadaveric dissection together with variation in the abductor digiti minimi.

Case Report

Dissection of the left hand of a cadaver of a 79-year-old Caucasian male who died of prostate cancer, revealed anatomical variations in the hypothenar muscles, the ulnar nerve and its dorsal cutaneous branch (Figures 1, 2).

The flexor digiti minimi brevis was large and almost overlapped the abductor digiti minimi. It originated from flexor retinaculum, the hook of hamate and a tendinous arch extending to the pisiform bone. It inserted with the abductor digiti minimi in the medial aspect of the base of the proximal phalanx of the little finger. The abductor digiti minimi had three heads, which partially overlapped, a superficial head most lateral, an intermediate head, and deepest and most medial was the deep head. The deep head originated from the medial aspect of the pisiform bone, the

intermediate head from the distal and lateral aspects of the pisiform bone, the superficial head from the hook of hamate and pisohamate ligament.

The ulnar nerve entered the hand superficial to the flexor retinaculum in Guyon's canal, undercover of the volar carpal ligament and palmaris brevis muscle. It divided just proximal to the pisiform bone into three branches: superficial, deep and muscular branches. The superficial, passing deep to the palmaris brevis divided into palmar digital branch proper to medial side of the little finger, and a common palmar digital branch for the fourth interosseous space. The deep branch crossed the pisohamate ligament and passing deep to the fibrous arch of the flexor digiti minimi brevis it penetrated the opponens digiti minimi. The muscular branch entered the hypothenar eminence lateral to the pisiform bone and supplied the deep, intermediate and superficial heads of the abductor digiti minimi. The deep branch supplied the flexor digiti minimi brevis, opponens digiti minimi and another branch to the superficial head of abductor digiti minimi.

The dorsal branch of ulnar nerve divided into three branches above the level of the pisiform bone. The lateral two were distributed to the skin of the dorsum of the hand. The most medial branch crossed the medial side of the pisiform bone, looped through the belly of the deep head of abductor digiti minimi and established three communications: (1) with the

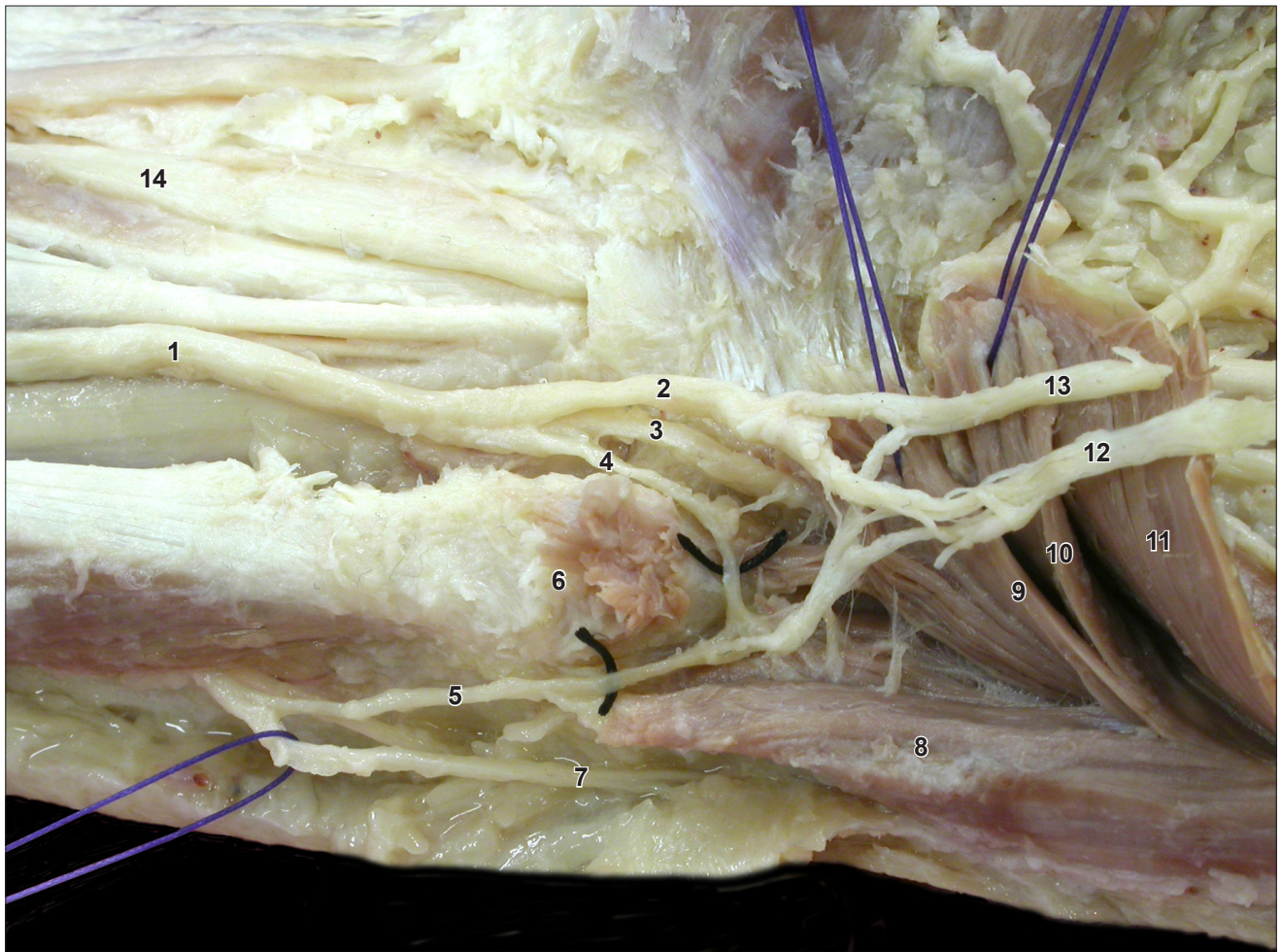


Figure 1. Ulnar nerve (1) trifurcation into superficial (2) and deep (3) division, and muscular branch (4). Medial branch (5) of the dorsal branch of the ulnar nerve (7) forms a loop with the muscular branch distal to the pisiform bone (6). Abductor digiti minimi has three heads: deep (8), intermediate (9) and superficial (10), located deep to flexor digiti minimi brevis (11). The palmar digital nerve proper to the little finger (12) and the common palmar digital nerve to the fourth interosseous space (13) also communicate with the dorsal branch of the ulnar nerve. (14: median nerve)

palmar digital branch proper of the medial side of little finger; (2) with the common palmar digital branch to the little and ring fingers; (3) with the muscular branch of the ulnar nerve. The dissection also showed radial deviation of the palmaris longus tendon and the median nerve therefore appeared on the medial aspect of the palmaris longus tendon above the flexor retinaculum.

Discussion

Classical descriptions of ulnar nerve branching state that it divides into deep and superficial branches, a pattern seen in 78% of cases [1] as the nerve passes in Guyon's canal resting on the pisohamate ligament and covered by the transverse volar ligament [6]. The current case showed trifurcation of the ulnar nerve just proximal to the pisiform bone. Trifurcation was reported previously in 11 out of 50 cases, and in four of these, the trifurcation occurred in Guyon's canal [1]. In that study, the ulnar nerve divided into a deep

branch and two superficial branches, a proper digital nerve for the medial side of the little finger and a common palmar digital nerve to the ring and the little fingers. However, our current study showed a fundamental difference in that in addition to the classical deep and superficial branches the third was a muscular branch innervating the three heads for the abductor digiti minimi.

Communications between the dorsal branch of the ulnar nerve and ulnar digital nerves of the fingers have been referred to as Kaplan's anastomoses [7]. Anastomoses between the dorsal branch and sensory branches of the ulnar nerve in the palm as seen in the current case were also reported in a rare case where the dorsal branch had a high origin from the ulnar nerve near the medial epicondyle [8]. A more extensive overlap of the dorsal branch on to the palmar surface has been reported where the medial most palmar digital branch to the little finger arose completely

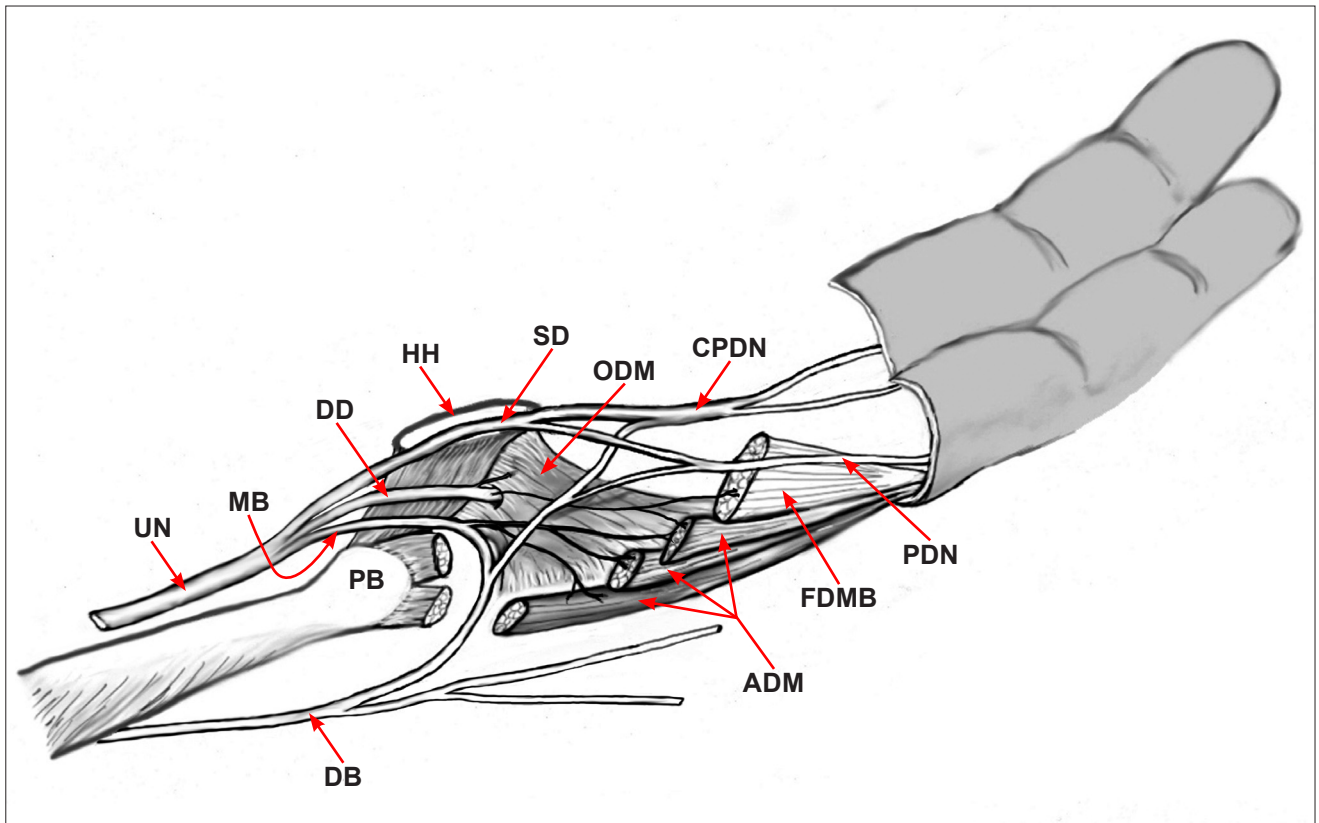


Figure 2. Illustration showing ulnar nerve (UN) trifurcates just proximal to the pisiform bone (PB) into superficial (SD) and deep divisions (DD), and a muscular branch (MB) to three heads of the abductor digiti minimi (ADM). The deep division supplies the flexor digiti minimi brevis (FDMB), superficial head of ADM and the opponens digiti minimi (ODM). The dorsal branch of the ulnar nerve (DB) communicates with the muscular branch, the palmar digital nerve (PDN) to the medial side of the little finger and the common palmar digital nerve (CPDN) of the fourth interosseous space. (HH: hook of hamate)

from the dorsal branch [2]. This may represent a more dominant dorsal dermatome distribution.

Whilst in previously published variants of Kaplan's nerve the communications were between sensory nerves, in the current case definite communication was also present between the dorsal branch and the muscular branch of the ulnar nerve, which was the principal variant in the current case. Anastomosis of the dorsal branch of the ulnar nerve with the deep (motor) division of the ulnar nerve was considered

a rare finding [3]. Therefore, the variant described here where the dorsal branch of the ulnar communicated with the muscular branch is unique and as far as we can tell has not been described previously and has not been listed in the classification system of dorsal to palmar communications described previously [3]. The combination of trifurcation of the ulnar nerve and the loop communication with the muscular branch of the ulnar nerve on the palmar surface may be a considered a very rare variation.

References

- [1] Bonnel F, Vila RM. Anatomical study of the ulnar nerve in the hand. *J Hand Surg Br.* 1985; 10: 165–168.
- [2] Bozkurt MC, Cezayirli E, Tagil SM. An unusual termination of the ulnar nerve in the palm. *Ann Anat.* 2002; 184: 271–273.
- [3] Hankins CL, Flemming S. A variant of Kaplan's accessory branch of the dorsal cutaneous branch of the ulnar nerve: a case report and review of the literature. *J Hand Surg Am.* 2005; 30: 1231–1235.
- [4] McCarthy RE, Nalebuff EA. Anomalous volar branch of the dorsal cutaneous ulnar nerve: a case report. *J Hand Surg Am.* 1980; 5: 19–20.
- [5] Kaplan EB. Variation of the ulnar nerve at the wrist. *Bull Hosp Joint Dis.* 1963; 24: 85–88.
- [6] McFarlane RM, Mayer JR, Hughll JV. Further observations on the anatomy of the ulnar nerve at the wrist. *Hand.* 1976; 8: 115–117.
- [7] Paraskevas G, Ch Gekas C, Tzaveas A, Spyridakis I, Stoitidou A, Ph Tsitsopoulos P. Kaplan anastomosis of the ulnar nerve: a case report. *J Med Case Reports.* 2008; 2: 107.
- [8] Lama P, Potu BK, Bhat KM. High origin of dorsal branch of the ulnar nerve and variations in its branching pattern and distribution: a case report. *Cases J.* 2009; 2: 8130.