



Case Report

Anatomical variation of the origin of the right lingual artery

Published online April 11th, 2011 © <http://www.ijav.org>

Surekha D JADHAV +

Manoj P AMBALI

Raosaheb J PATIL

Krishna Institute of Medical Sciences Deemed University (KIMSOU), Karad, Maharashtra, INDIA.



+ Dr. Surekha D Jadhav
Assistant Professor
Department of Anatomy
Krishna Institute of Medical Sciences
Deemed University
Karad, Dist. Satara, Maharashtra
415110, INDIA.
☎ +91 982 3373960
✉ dpsurekha_32@yahoo.in

Received July 17th, 2010; accepted March 1st, 2011

ABSTRACT

This paper presents and describes an anatomical variation of the lingual artery originating from the right common carotid artery. This variation was found in a male cadaver at Krishna Institute of Medical Sciences Deemed University, Karad (MS), India, during routine dissection classes for medical undergraduate students. On right side the lingual artery was originated from common carotid artery 6 mm below its bifurcation. In this case, we reported high division of common carotid artery at the tip of the styloid process. However, arterial branching pattern and point of bifurcation on left side were as usual. © IJAV. 2011; 4: 75–76.

Key words [common carotid artery] [lingual artery]

Introduction

The carotid arteries provide the major source of blood to the head and neck. The right common carotid artery (CCA) originates from the brachiocephalic trunk in the neck while the left arises in the thorax from the aortic arch. Normally, it gives two terminal branches, external and internal carotid arteries at the level of superior border of thyroid cartilage in carotid triangle [1]. Anatomical variations in the point of bifurcation and branching pattern of CCA are known and documented by several authors. It may provide one or more branches usually derived from the external carotid artery. Examples are superior thyroid artery, thyroidea ima, and cases have been reported in which a vertebral, inferior thyroid, occipital or ascending pharyngeal as a branch of CCA. Rarely, the CCA may be absent or it may not bifurcate but provide branches usually derived from the external carotid as it ascends in the neck [2]. It is important for surgeons and radiologists to be aware of the normal anatomy of CCAs and their branches because variations among these arteries are quite common. In this report, a rare variation of the origin of lingual artery from right CCA is reported in a male cadaver along with high bifurcation of right CCA.

Case Report

During routine dissection classes for medical undergraduate students in our department, variation in the origin of lingual

artery from right CCA was observed in a male cadaver. The lingual artery was originating from medial side of right CCA, 6 mm below the level of its bifurcation point. The lingual artery was running medially and upwards forming a loop which was crossed by hypoglossal nerve (Figures 1, 2). The superior thyroid artery arose from right external carotid artery, which was running downwards deep to hypoglossal nerve and superficial to lingual artery (Figure 3). The right CCA divided at higher level coinciding with the level of tip of the styloid process, and hypoglossal nerve was crossing it at its bifurcation. However, on the left side the lingual artery was a branch of the external carotid artery and bifurcation of CCA was at the superior border of thyroid cartilage.

Discussion

Normally, the common carotid artery does not give any collateral branches except its terminal branches external and internal carotid arteries [1]. Variations in branching pattern of CCA are well known. Kaneko et al. observed that the superior thyroid, lingual and facial arteries arose from the common carotid artery, and the posterior auricular, maxillary and superficial temporal arteries arose from the common carotid artery by a common trunk. The occipital and ascending pharyngeal arteries arose from the internal carotid artery. There was no specific external carotid artery [3]. Unusual case of origin of the superior thyroid, lingual

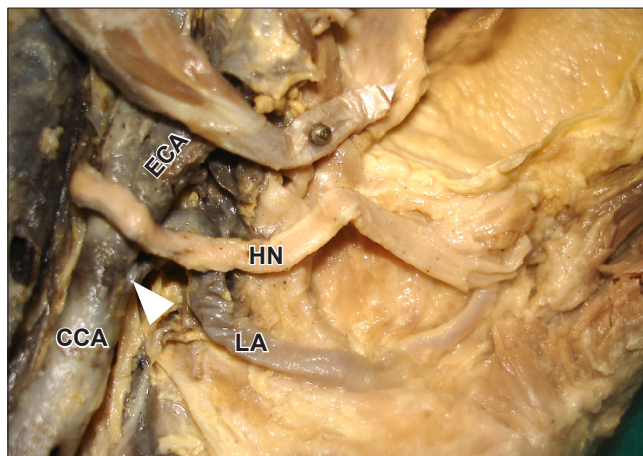


Figure 1. Figure shows loop of lingual artery crossed hypoglossal nerve. (LA: lingual artery; HN: hypoglossal nerve; CCA: common carotid artery; ECA: external carotid artery; white arrowhead: origin of lingual artery)

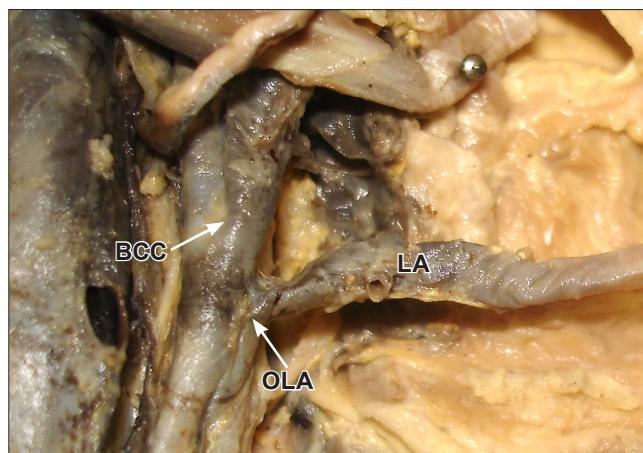


Figure 2. Figure shows origin of lingual artery from right common carotid artery. (LA: lingual artery; OLA: origin of lingual artery; BCC: bifurcation point of common carotid artery)

and facial from the common carotid by a common trunk was also described by Arthur Thomson in his notes on unusual variations [4]. Babu [5] and Budhiraj and Rastogi [6] reported variant origin of thyrolingual trunk from right and left CCA, respectively. Mahendrakar reported unilateral agenesis lingual artery [7].

The lingual artery is typically the second branch arising anteriorly from the external carotid artery and may arise either below or under cover of posterior belly of digastric [8]. The lingual artery arises from a common trunk with the facial (linguofacial trunk) in 10–20% of cases; a rare combination branch of the external carotid is thyrolingual trunk [2]. In the present case, the lingual artery was arising from medial side of the right CCA, 6 mm below its bifurcation which is a rare anatomical variation. Variation in branching

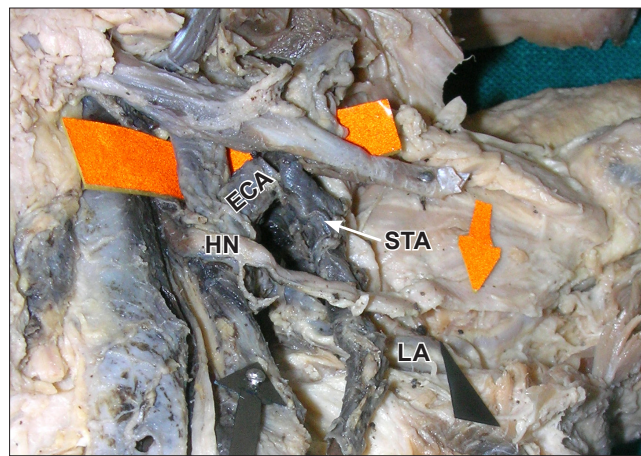


Figure 3. Figure shows origin of superior thyroid artery. (STA: superior thyroid artery; HN: hypoglossal nerve; LA: lingual artery; ECA: external carotid artery)

patterns and bifurcation point of CCA may increase risk of accidental vascular trauma during surgical procedures in the neck such as extraoral ligation of the lingual artery, carotid endarterectomy and catheter insertion of CCAs.

Conclusion

The variations of the branches of the carotid artery are of paramount importance not only in clinical practice but also in theoretical considerations. Knowledge of variation of the common carotid artery bifurcation point and branching pattern and its position is mandatory to avoid complications during various surgical procedures for surgeon and also for radiologist while evaluating radiographs. Noting this variation may be beneficial for surgeons, ENT surgeons and radiologists.

Acknowledgements

We are thankful and grateful to our Department Head and Vice Principal Dr. B. N. Umaraji Sir and Dr. (Mrs.) M. A. Doshi for their advice and support.

References

- [1] Standring S, ed. Gray's Anatomy. 40th Ed., New York, Churchill Livingstone. 2008; 444–445.
- [2] Bergman RA, Afifi AK, Miyauchi R. Illustrated Encyclopedia of Human Anatomic Variation: Opus II: Cardiovascular System: Arteries: Head, Neck, and Thorax. Common Carotid Arteries. <http://www.anatomyatlases.org/AnatomicVariants/Cardiovascular/Text/Arteries/CarotidCommon.shtml> (accessed June 15th, 2010)
- [3] Kaneko K, Akita M, Murata E, Imai M, Sowa K. Unilateral anomalous left common carotid artery; a case report. *Ann Anat.* 1996; 178: 477–480.
- [4] Thomson A. Notes on some unusual variations in human anatomy. *Anat Physiol.* 1885; 19: 328–332.
- [5] Babu BP. Anomalous origin of thyrolingual trunk from right common carotid artery – a case report. *J Anat Soc India.* 2001; 50: 47–48.
- [6] Budhiraja V, Rastogi R. Variant origin of thyrolingual trunk from left common carotid artery. *International Journal of Anatomical Variations.* 2010; 3: 44–45.
- [7] Mahendrakar MA. Variation in the branching pattern of external carotid artery: a case report. *J Anat Soc India.* 2007; 56: 47–51.
- [8] Hollinshead WH. *Anatomy for Surgeons.* Vol. 1. 3rd Ed., Philadelphia, Harper and Row. 1982; 374–375.