



Anatomical variation of the flexor digitorum brevis muscle revisited: a case report from South Indian population

Published online December 21st, 2010 © <http://www.ijav.org>

Rajesh THANGARAJAN ⁺
 Pugazhandhi BAKTHAVATCHALAM
 Bhagath Kumar POTU
 Huban Rajaratnam THOMAS

Department of Anatomy, Kasturba Medical College, Manipal University, Manipal, Karnataka, INDIA.



⁺ Rajesh Thangarajan
 Department of Anatomy
 Kasturba Medical College
 Manipal University
 Manipal, Karnataka, 576104, INDIA.
 ☎ +91 991 6820819
 ✉ rajeshhhms@gmail.com

Received May 17th, 2010; accepted August 18th, 2010

ABSTRACT

We observed a variation in the flexor digitorum brevis muscle of a 50-year-old female cadaver in our routine dissection. In the sole of right foot, we found that flexor digitorum brevis was giving only three tendons for middle three toes. The tendon of flexor digitorum brevis for the little toe was missing. The absent 4th tendon of the flexor digitorum brevis to little toe in the right foot was replaced by an isolated flexor muscle arising from the medial margin of the tendinous plate of the flexor digitorum brevis. The tendon of isolated flexor muscles inserted in to base of distal phalanx of the little toe. Variation of the flexor digitorum brevis may be important to plastic surgeons because of reconstruction of the heel pad by flexor digitorum brevis musculocutaneous flap transfer. © IJAV. 2010; 3: 211–213.

Key words [variation] [musculocutaneous flap transfer] [heel pad]

Introduction

The flexor digitorum brevis muscle (FDB) lies immediately deep to the central part of the plantar aponeurosis. It takes origin from the central part of the plantar aponeurosis, medial tubercle of calcaneal tuberosity and from the medial and lateral intermuscular septa. The FDB divides into four tendons for the lateral four toes. Each tendon is divided into two slips at the base of their proximal phalanges, to allow the flexor digitorum longus (FDL) tendons, and finally attaches to both sides of the shaft of the middle phalanx [1]. There are some reports available in literature on variations of the FDB reported by various authors [2–5]. To the best of our knowledge, the variant FDB, what we are reporting here is the first case from south Indian population.

Case Report

A separate small flexor muscle with missing FDB tendon to the little toe of right foot were found in 50-year-old female cadaver during the routine dissection classes for undergraduate medical students in Department of Anatomy, Kasturba Medical College, Manipal University. The FDB was exposed after the removal of plantar skin, adipose tissue and the central part of plantar aponeurosis.

In the sole of right foot, FDB had 3 muscle bellies inserting into second, third and fourth toes, and the 4th tendon of FDB muscle was absent (Figure 1). The lacking 4th tendon of FDB to little toe in the right foot was

replaced by an isolated flexor muscle originating from the medial margin of the tendinous plate of FDB and passing medial to lateral, superficial to FDB (Figure 2). The tendon of isolated flexor muscle inserted into base of distal phalanx of the little toe along with the tendon of FDL for the fifth toe.

Discussion

In the study of Nathan and Gloobe, a part of the muscle and tendon inserting into the fifth and/or to the fourth and fifth toes was absent in 23 and 3% of cases, respectively. In addition, they reported, the muscular slip for the fifth toe, or for the fifth and fourth toes, were much smaller and the tendons were thinner than for the other toes. In their report, the muscle for the fifth toe, or the fourth and fifth toes, originated solely from the tendon of the FDL in 5% of cases. In addition, in one foot (1%), the muscle for the fifth toe arose from the intermuscular septum and its tendon fused with the corresponding tendon of the FDL without dividing into two slips [3]. Although we found a similar variation, the tendon in our case not divided into two slips, which inserted into the tendon of the FDL for the fifth toe. According to Bergman et al., in 21% of cases, FDB was absent but may be replaced by a small fusiform belly arising from long flexor tendon, as well as 63% of all limbs variation of the FDB was present [6]. In the left foot of the case reported by Claassen and Wree, the FDB had a reduced portion for the fifth toe with a small muscle belly and a thin tendon [4]. A tendon to the fifth toe was missing in the FDL and an isolated flexor to

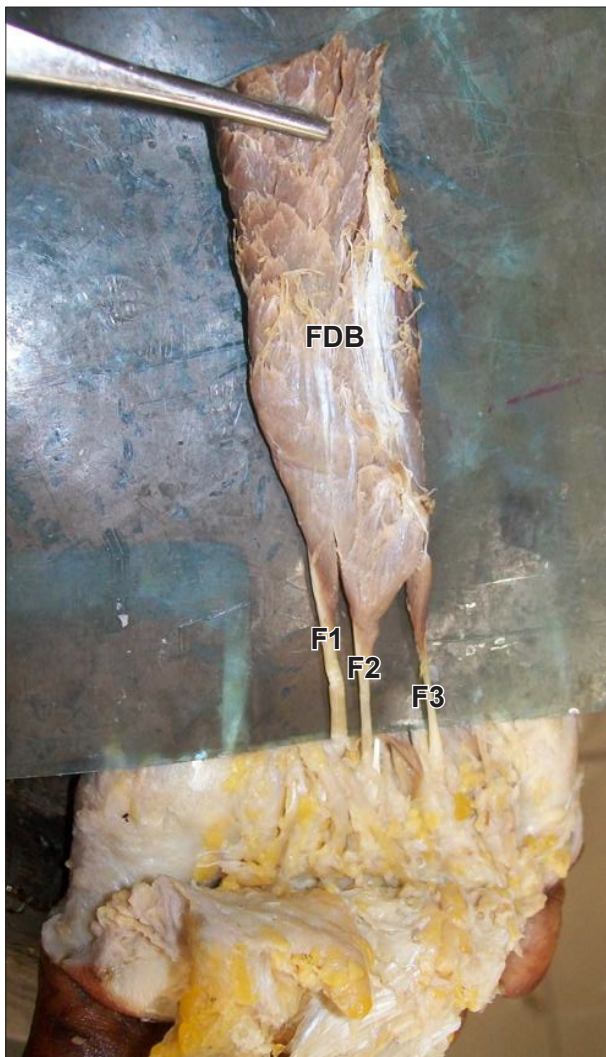


Figure 1. Flexor digitorum brevis muscle (FDB) and its tendons for second (F1), third (F2) and fourth (F3) toes. FDB for the little toe is missing.

the fifth toe arose from the medial and lateral tubercles of calcaneum with connections to the tendinous plate of the FDL and to the quadratus plantae [4]. In the right foot of their case, Claassen and Wree reported that, for both FDB and FDL, the tendon to the fifth toe was missing and an isolated flexor to the fifth toe arose from the medial part of the medial tubercle of calcaneus [4].

In a study by Yalcin and Ozan, out of 33 feet they found that in 12 feet the muscle belly for the fifth toe was much smaller than the others and it was missing in six feet. They also found that in the left foot of one female cadaver, FDB was formed by a superficial and a deep head, which had three muscle bellies and four tendons. In the right foot, a separated muscle belly for the fifth toe was very thin and originated from the intermuscular septum as a flat fascia under the FDB. In another case (male), three heads (lateral, intermediate and medial) formed the quadratus plantae and the lateral and intermediate heads fused with the FDB. In the study of Yalcin and Ozan, 55% of FDB

showed variation from the standard description explained in anatomical textbooks [5].

The missing of 4th tendon of FDB may be as a result of bipedal evolution thus there is gradual reduction in the usage of little toe [7].

The question can be raised whether the observed isolated flexor muscles belong to FDB, the FDL or the quadratus plantae. By its location, we postulate that the isolated flexor muscle is not a part of FDB, but must belong to the group of the deep muscles. Although variations of FDB have little functional importance, their knowledge may be important for the reconstruction of the heel pad by FDB musculocutaneous flap transfer [8,9].

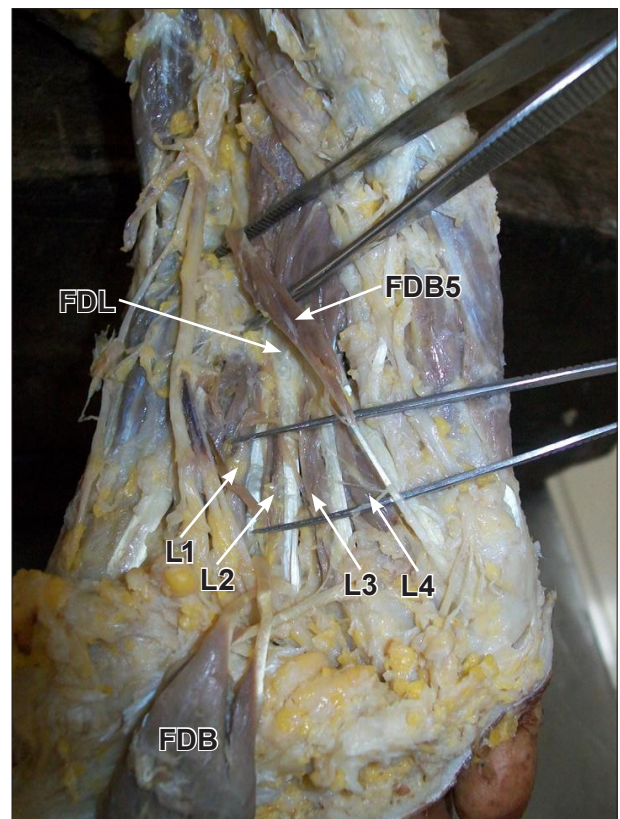


Figure 2. Flexor digitorum longus muscle (FDL) tendons with lumbrical muscles L1, L2, L3 and L4. (FDB5: flexor digitorum brevis muscle for little toe; FDB: flexor digitorum brevis muscle, reflected)

References

- [1] Williams PL, Warwick R. Gray's Anatomy. 36th Ed., Edinburgh, Churchill Livingstone. 1980; 614.
- [2] Meckel JF. Handbuch der menschlichen anatomie. Bd. 2. Besondere Anatomie. Knochenlehre. Bänderlehre. Muskellehre. Buchhandlungen des Hallischen Waisenhauses, Halle und Berlin. 1816; 599–601.
- [3] Nathan H, Gloebe H. Flexor digitorum brevis-- anatomical variations. *Anat Anz*. 1974; 135: 295–301.
- [4] Claassen H, Wree A. Isolated flexor muscles of the little toe in the feet of an individual with atrophied or lacking 4th head of the M. extensor digitorum brevis and lacking the 4th tendon of the M. extensor digitorum longus. *Ann Anat*. 2003; 185: 81–84.
- [5] Yalcin B, Ozan H. Some variations of the musculus flexor digitorum brevis. *Anat Sci Int*. 2005; 80: 189–192.
- [6] Bergman RA, Thompson SA, Afifi AK, Saadeh FA. *Compendium of Human Anatomic Variation: Text, Atlas and World Literature*. Baltimore, Munich, Urban & Schwarzenberg. 1988; 28.

- [7] Lobo SW, Menezes RC, Mamata S, Baral P, Humnargi SA, Kanchan T, Bodhe AV, Bhat NB. Phylogenetic variation in flexor digitorum brevis: a Nepalese cadaveric study. *Nepal Med Coll J.* 2008; 10: 230–232.
- [8] Ikuta Y, Murakami T, Yoshioka K, Tsuge K. Reconstruction of the heel pad by flexor digitorum brevis musculocutaneous flap transfer. *Plast Reconstr Surg.* 1984; 74: 86–86.
- [9] Garcia-Gonzalez A, Bayod J, Prados-Frutos JC, Lose-Iglesias M, Jules KT, Becerro de Bengoa-Vallejo R, Doblare M. Finite-element simulation of flexor digitorum longus or flexor digitorum brevis tendon transfer for the treatment of claw toe deformity. *J Biomech.* 2009; 42: 1697–1704.