



## Anatomic variation of the iliacus and psoas major muscles

Published online February 21st, 2011 © <http://www.ijav.org>

Philip A. FABRIZIO †

Mercer University, Department of Physical Therapy, Atlanta, Georgia, USA.



† Philip A. Fabrizio, PT, DPT, MS  
111 Davis Building  
Department of Physical Therapy  
College of Pharmacy and Health Sciences  
Mercer University  
3001 Mercer University Drive  
Atlanta, Georgia 30341-4155, USA.  
☎ +1 (678) 547-8178  
✉ [fabrizio\\_pa@mercer.edu](mailto:fabrizio_pa@mercer.edu)

Received October 4th, 2010; accepted January 17th, 2011

### ABSTRACT

Routine dissection has identified a previously unrecorded unilateral variation of the iliacus and psoas muscles in a 91-year-old female cadaver. A variant iliacus muscle belly originated from the superior lateral aspect of the iliac fossa and after traversing the iliac fossa in a nearly horizontal plane, inserted into the psoas major muscle forming a blended iliacus-psoas muscle. The femoral nerve coursed laterally behind the muscle variant to the superior edge of the blended iliacus-psoas. The femoral nerve then coursed over the anterior aspect of the muscle variant and continued inferiorly in a typical course toward the inguinal ring. The current findings and clinical significance are discussed. © IJAV. 2011; 4: 28–30.

**Key words** [iliacus muscle] [psoas muscle] [femoral nerve]

### Introduction

Customary dissection in the Physical Therapy Anatomy Laboratory yielded a unilateral right-sided iliopsoas variation in a single cadaver. The embalmed specimen was a 91-year-old Caucasian female. The variation included an unusual arrangement of the iliacus muscle attached to the psoas major muscle with a resultant alteration in the course of the femoral nerve. Although iliacus and psoas muscle variations have been reported in the literature, to the author's knowledge, there are none identical to the current case.

### Case Report

The iliacus muscle in the current case demonstrated the typical proximal attachments from the iliac fossa, medial lip of the iliac crest and the iliolumbar and sacroiliac ligaments. However, the superior fibers of the iliacus, beginning approximately 2 cm inferior to the iliac crest, coursed medially and attached to a tendinous border along the posterolateral aspect of the psoas major muscle. The remaining fibers of the iliacus coursed inferomedially to attach to the posterolateral aspect of the psoas major (Figure 1). The iliacus and psoas major muscles were blended together giving the impression of being one muscle extending from the superior 1/3 of the ilium and the lateral aspect of the lumbar spine (Figure 2). The blended iliacus-psoas muscle

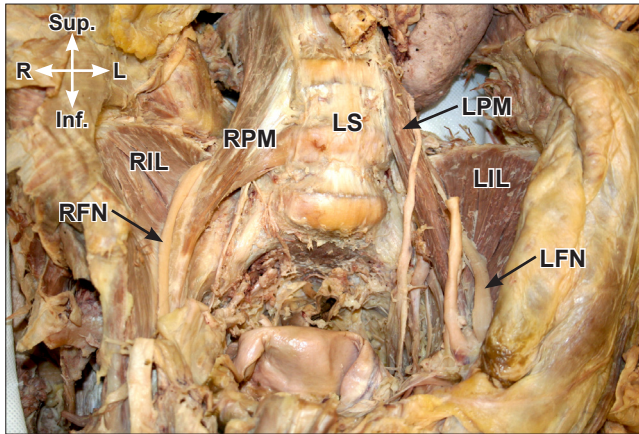
inserted distally as one tendon on the lesser trochanter of the femur.

The femoral nerve was identified as traversing the superior margin of the blended iliacus-psoas at the uppermost connection. The nerve coursed along the anterior surface of the combined iliacus-psoas tendon and then followed the typical path through the inguinal region.

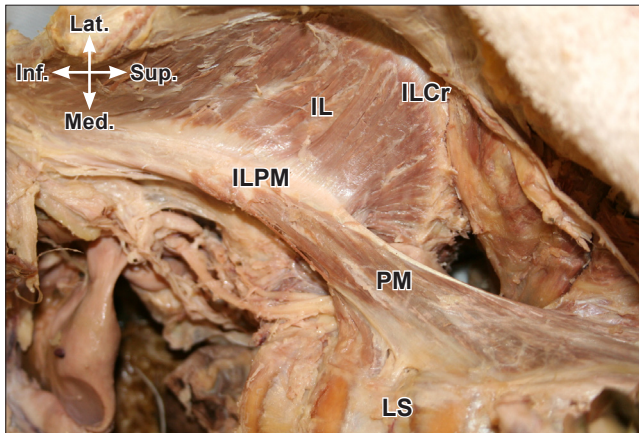
The belly of the psoas major was dissected to reveal that the lumbar plexus formed, as it is typically found, within the psoas muscle belly. However, upon exiting the psoas major muscle the femoral nerve coursed laterally for a short distance behind the blended iliacus-psoas fibers. The nerve then coursed over the superior edge of the iliacus-psoas tendon and passed inferiorly to lie on the anterior surface of the blended muscles. The severity of the altered course of the nerve over the variant muscle arrangement left a compression indentation on the femoral nerve at the point of changing course over the superior border of the blended muscles (Figure 3).

### Discussion

The typical arrangement of the muscles of the iliac region have been described as consisting of the psoas major and minor and the iliacus. The psoas major typically has a proximal attachment from the anterior surfaces of the



**Figure 1.** Anterior posterior view of the posterior abdominal wall of the specimen. (*RIL*: right iliopsoas; *LIL*: left iliopsoas; *RPM*: right psoas major; *LPM*: left psoas major; *LS*: lumbar spine; *RFN*: right femoral nerve; *LFN*: left femoral nerve)



**Figure 2.** Anterior view of the blended iliopsoas muscle variation. (*ILCr*: iliac crest; *IL*: iliopsoas; *PM*: psoas major; *ILPM*: blended connection between the iliopsoas and psoas muscles; *LS*: lumbar spine)

transverse processes, bodies and intervertebral discs of all of the lumbar vertebrae and the twelfth thoracic vertebra. The iliopsoas has a typical proximal attachment from the upper 2/3 of the iliac fossa, the medial lip of the iliac crest, the iliolumbar and sacroiliac ligaments, and the lateral aspect of the sacrum. The fibers of the iliopsoas and psoas major muscles converge to form a combined tendon, which has a distal attachment to the lesser trochanter of the femur [1,2]. The psoas minor, when present arises from the sides and bodies of the twelfth thoracic and first lumbar vertebrae and intervening disc and has its distal attachment as the pecten of the pubis and iliopubic ramus [1].

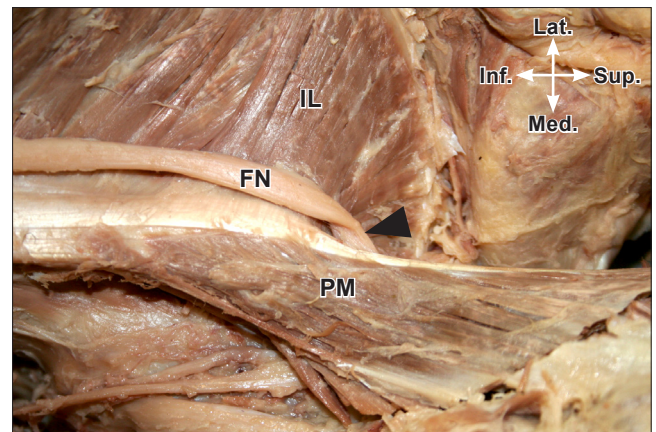
The lumbar plexus lies within the substance of the psoas major. The femoral nerve is formed by the dorsal divisions of lumbar rami two, three and four. The femoral nerve

typically emerges from the inferior portion of the psoas major to lie between psoas major and iliopsoas [1].

The literature describes few variations of the iliopsoas. A small detached portion of iliopsoas, the iliopsoas minor or iliopsoas capsularis, has been described as having a proximal attachment from the anterior inferior iliac spine and distal attachment into the lower part of the intertrochanteric line of the femur or into the iliopsoas ligament [3]. The “iliopsoas minor” has been further proposed by Spratt et al. who described two similar cases of iliopsoas variations [4]. The variations described by these authors included unilateral slips of iliopsoas seen in two specimens. The proximal attachments of the slips included the iliolumbar ligament in one specimen and the ala of the sacrum in the second. Each slip had a common distal attachment to the lesser trochanter with the first specimen also demonstrating a distal attachment in an unidentified distal region of the shaft of the femur. The iliopsoas minor muscles were distinct and discrete slips of muscle lying anterior to the iliopsoas proper [4]. In each case above the course of the femoral nerve was not altered by the muscle slips.

Variations of the iliopsoas interrupting or altering the course of the femoral nerve have been described [5,6]. A case of bilateral iliopsoas and psoas variations as described by Jeleu et al. demonstrated a “split” femoral nerve in a case involving an accessory psoas major muscle. Further, an accessory iliopsoas was also noted on the same side of the specimen. However, these accessory muscles were demonstrated as distinct and separate muscle bellies that were separate from the typical iliopsoas and psoas major muscles and were not consistent with the present case [5].

D’Costa et al. described a case involving an accessory iliopsoas muscle slip with a proximal attachment from the iliac crest and distally attaching to the lesser trochanter. The



**Figure 3.** Close-up anterior view demonstrating compression of the femoral nerve caused by the variation. Note that the femoral nerve was cut distal to the variant muscle in order to slack the nerve thus allowing the view into the slight posterior aspect of the compression site. (*Black arrowhead*: compression site; *IL*: iliopsoas; *FN*: femoral nerve; *PM*: psoas major)

femoral nerve was interrupted by the accessory iliacus slip [6]. In the present case, the iliacus and psoas major muscles were connected more proximally than has been typically seen. The course of the femoral nerve was altered due to the variation; however, the blood vessels appeared to maintain the typical course and arrangement.

The variation in the present case could have several clinical implications including altered abdominal imaging, mimicking of lumbar disc herniation, and increased pain with neurodynamic testing. The occurrence of tumors in the iliac region has been reported to be rare, however, because of the complexity of the region these tumors are often inaccessible [7]. The current variation, if present in a suspected case of iliopsoas compartment tumor, could have appeared as a mass or unidentified structure thus complicating interpretation of the imaging study. Further, the blended iliacus-psoas in the current study could have complicated surgical accessibility to an existing iliopsoas tumor. Symptoms of iliopsoas compartment tumor can

include pain along the femoral nerve distribution, vascular compromise, local pain, and weakness with hip flexion [7]. These symptoms are similar to the symptoms of patients who present with lumbar disc herniation at L3. A patient with the blended muscle seen in the current study may have presented with symptoms similar to that of a lumbar intervertebral disc herniation at the L3 level due to tension/compression of the femoral nerve at the superior border of the blended iliacus-psoas. The symptoms for intervertebral disc herniation at L3 include pain in the lumbar area, weakness of iliopsoas and quadriceps muscles, positive neural tension testing (prone knee flexion), and altered sensation over the anterior aspect of the thigh and medial aspect of the leg [8,9]. Compression or tension insult to the femoral nerve as that caused by the altered course of the femoral nerve in the present case could have mimicked a disc herniation. Knowledge of this variant may assist with differential diagnosis of patients with iliac region pathology or lumbar disc disease especially in those cases where conservative treatment is ineffective.

## References

- [1] Standring S, Borley NR, Healy JC, Collins P, Crossman AR, Gatzoulis MA, Johnson D, Mahadevan V, Newell R, Wigley CB, eds. *Gray's Anatomy: The Anatomical Basis of Clinical Practice*. 40th Ed., London, Elsevier. 2008; 1387–1388.
- [2] Moore KL, Dalley AF, Agur AMR. *Clinically Oriented Anatomy*. 6th Ed., Baltimore, Lippincott Williams & Wilkins. 2010; 311–313.
- [3] Bergman RA, Thompson SA, Afifi AK. *Catalog of Human Variations*. Baltimore, Urban & Schwarzenberg. 1984; 51–52.
- [4] Spratt JD, Logan BM, Abrahams PH. Variant slips of psoas and iliacus muscles, with splitting of the femoral nerve. *Clin Anat*. 1996; 9: 401–404.
- [5] Jeleu I, Shivarov V, Surchev L. Bilateral variations of the psoas major and the iliacus muscles and the presence of an undescribed variant muscle – accessory iliopsoas muscle. *Ann Anat*. 2005; 187: 281–286.
- [6] D'Costa S, Ramanathan LA, Madhyastha S, Nayak SR, Prahhu LV, Rai R, Saralaya VV, Prakash. An accessory iliacus muscle: a case report. *Rom J Morphol Embryol*. 2008; 49: 407–408.
- [7] Behranwala KA, A'Hern R, Thomas JM. Primary malignant tumors of the iliopsoas compartment. *J Surg Oncol*. 2004; 88: 78–83.
- [8] Kim DS, Lee JK, Jang JW, Ko BS, Lee JH, Kim SH. Clinical features and treatment of upper lumbar disc herniations. *J Korean Neurosurg Soc*. 2010; 48:119–124.
- [9] Dutton M. *Orthopedic Examination, Evaluation and Intervention*. New York, McGraw Hill Publishing. 2004; 945–957.