

An Unusual Variation in the Sternocleidomastoid Muscle – A Case Report

M. Meenakshi Mohan*

Meenakshi Mohan M. An Unusual Variation in the Sternocleidomastoid Muscle – A Case Report. *Int J Anat Var.* 2021;15(2):161-162.

ABSTRACT

The variations of the sternocleido mastoid are a rare case of 4 slips in the origin and inserted in to angle of mandible along with usual attachment and intermittent tendon of omohyoid fuse with the one additional clavicular head fiber was found during our routine dissection on the left side of the neck in an elderly female cadaver. The clinical and embryological significance of the

variation is discussed. this type of cases may be important for head and neck surgeons, plastic surgeon doing muscle graft surgeries, physiotherapist doing the treatment of sternocleidomastoid syndrome, torticollis, upper crossed syndrome, neck shoulder strain conditions, functional limitation of neck flexion.

Key Words: *Sternocleidomastoid (SCM); Clavicular head; Sternal head; Intermittent tendon of omohyoid; Torticollis; Upper crossed syndrome; Sternocleidomastoid syndrome.*

INTRODUCTION

The muscle name called sternocleidomastoid (SCM) because of its origin from manubrium sterni (sterno) and clavicle (cleido) and its insertion at the mastoid process of the temporal bone. The SCM extends obliquely across the side of the neck and divides the neck into anterior and posterior triangle. The SCM is the key muscle in the neck region because of important structures of the neck like great vessels and branches of cervical plexus are overlapped by the muscle [1].

SCM takes origin by two heads (sternal and clavicular head). Sternal head arises from the anterior surface of manubrium sternum, clavicular head arises from the superior surface of medial third of clavicle and gets inserted into lateral surface of mastoid process of temporal bone and lateral part of superior nuchal line [2]. Nerve supply of SCM from the spinal root of accessory nerve (motor) and ventral rami of c2 and c3 (proprioception) [3].

Action of this muscle-if unilateral muscle is contract, same side lateral flexion and rotation to opposite side. If bilateral contracts flexion of neck. Additionally, it involves accessory muscles of inspiration, maintain posture of neck and body and allows a correct function of temporo mandibular joint. If spasm of the muscle, in turns to flexion deformity of the neck is called wry neck or torticollis [4].

CASE REPORT

While doing a routine dissection cervical region of 60-year-old embalmed female cadaver in the department of Anatomy, Shri Sathya Sai medical college &RI, I found a rare and unusual variation in the origin, insertion, separated muscle belly and intermittent tendon of omohyoid was noted on the left side of the neck region [5-8].

Here I noted in one sternal head and three clavicular head origin and few fibres gets inserted into angle of mandible along with usual attachment and intermittent tendon of omohyoid is fused with the clavicular head of SCM muscle [9].

DISCUSSION

In other articles several variations of sterno cleido mastoid were reported on its origin. The variations in the insertion and fusion of intermittent tendon of omohyoid with the additional clavicular head fibres only few variations are published [10]. Sternocleidomastoid muscle variations with regard to the additional heads were reported many times in the literature [11]. In other article sternal and clavicular heads are separated and fused to form single belly but in this case all the heads having separated belly and sternal fibres

and c1 fibres inserted into angle of mandible and other fibres inserted into mastoid process and lateral part of superior nuchal line [12] (Figure 1).

In (Figures 2,3) intermittent tendon of omohyoid fuse with the clavicular fibres of sternocleidomastoid muscle.it is very rare variations.

The nerve supply of omohyoid is c2 and c3 and proprioception of SCM is c2 and c3 both of them supply from the cervical plexus.

Developmentally sternocleidomastoid derives from the paraxial mesoderm (HOX D4+), occipital somite and also from the neural crest along with trapezius from the posterior sixth brachial arches.

This type of cases may be important for head and neck surgeons, plastic surgeons doing muscle graft surgeries, physiotherapist doing neck treatments of SCM syndrome, torticollis, upper crossed syndrome, neck shoulder strain, functional limitations of neck flexion .

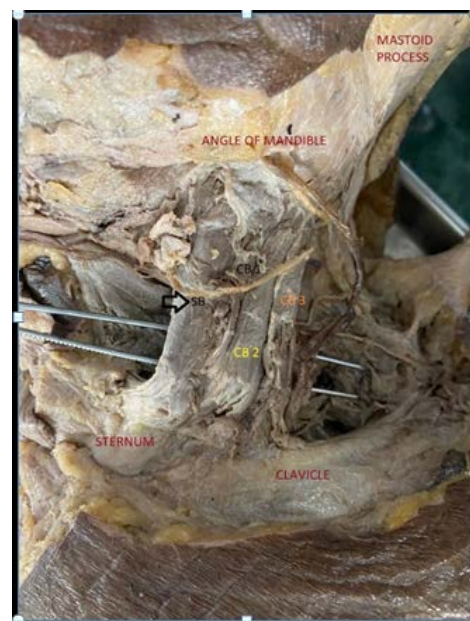


Figure 1) 4 bellies of sterno cleido mastoid muscle: SB- Sternal Belly, CB1-Clavicular fiber1, CB2-Clavicular head 2, CB3-Clavicular head 3.

Department of Anatomy, Shri Sathya Sai Medical College &RI, Ammapettai, Chengalpet-603108, Tamilnadu, India

Correspondence: M.Meenakshi Mohan, Department of Anatomy, Shri Sathya Sai Medical College &RI, Ammapettai, Chengalpet-603108, Tamilnadu, India. Telephone: 8778740230; E-mail: sunandaalluru@gmail.com.

Received: 01-Feb-2022, Manuscript No. *ijav-22-4349*, Editor assigned: 04-Feb-2022, PreQC No. *ijav-22-4349* (PQ), Reviewed: 18-Feb-2022, QC No: *ijav-22-4349*, Revised: 24-Feb-2022, Manuscript No: *ijav-22-4349* (R), Published: 28-Feb-2022, DOI: 10.37532/*ijav.2022.15(2).181*



This open-access article is distributed under the terms of the Creative Commons Attribution Non-Commercial License (CC BY-NC) (<http://creativecommons.org/licenses/by-nc/4.0/>), which permits reuse, distribution and reproduction of the article, provided that the original work is properly cited and the reuse is restricted to noncommercial purposes. For commercial reuse, contact reprints@pulsus.com

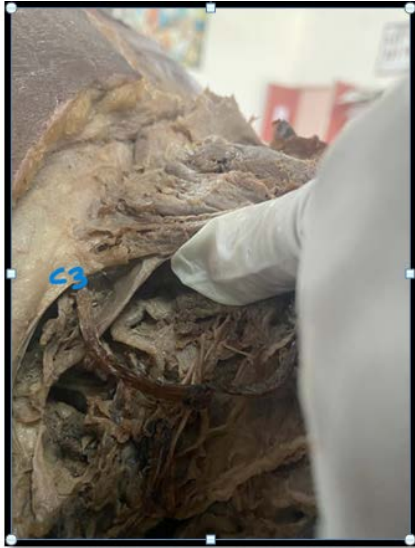

Figure 2) C3-3rd Clavicular head.

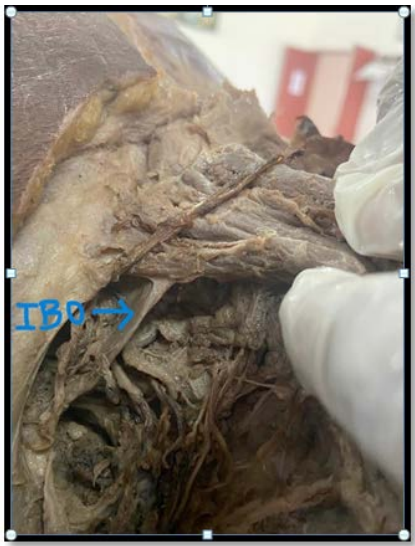

Figure 3) IOB- Inferior Belly of omohyoid.

REFERENCES

1. Coskun N, Yildirim FB, Ozkan O. Multiple muscular variations in the neck region - Case study. *Folia Morphol (Warsz)*. 2002;61:317-319.
2. Moore KL. *Clinically Oriented Anatomy*. 3rd Ed., Philadelphia, Williams & Wilkins. 1992; 786-987.
3. Standring S. *Gray's Anatomy: The Anatomical Basis of Clinical Practice*. 40th Ed., London, Elsevier, Churchill Livingstone. 2008; 441.
4. Ramesh RT, Vishnumaya G, Prakashchandra SK et al. Variation in the origin of sternocleidomastoid muscle. A case report. *Int J Morphol*. 2007; 25: 621-623.
5. Cherian SJ, Nayak S. A rare case of unilateral third head of sternocleidomastoid muscle. *Int J Morphol*. 2008; 26: 99-101.
6. Kumar MSJ, Sundaram SM, Fenn A et al. Cleido-occipital platysma muscle: a rare variant of sternocleidomastoid muscle. *Int J Anat Var (IJAV)*. 2009; 2: 9-10.
7. Bergman RA, Thompson SA, Afifi AK et al. *Compendium of Human Anatomic Variation*. Baltimore, Urban & Schwarzenberg. 1988; 32-33.
8. Conley J, Gullane PJ. The sternocleidomastoid muscle flap. *Head Neck Surg*. 1980; 2: 308-311.
9. Sebastian P, Cherian T, Ahamed MI et al. The sternomastoid island myocutaneous flap for oral cancer reconstruction. *Arch Otol Head Neck Surg*. 1994; 120: 629-632.
10. Matsuoka T, Ahlberg PE, Kessar N et al. Neural crest origins of the neck and shoulder. *Nature*. 2005; 436: 347-355.
11. Hassan T. Variations of the Sternocleidomastoid Muscle: A Literature Review. *The Int J of Human Anat*. 2011; 1: 2-3.
12. Anubha S, Shyamash M, Sandip C et al. Morphological study of the attachment of the sternocleidomastoid muscle. *Med J* 2014; 55(1): 45-47.