



Case Report

An unusual case of axillary arch bridging across the anterior and posterior axillary folds in the distal part of axilla

Published online June 28th, 2011 © <http://www.ijav.org>

Mohandas RAO KG ⁺
Somayaji SN
Narendra PAMIDI
Surekha D SHETTY

Department of Anatomy, Melaka Manipal Medical College, Manipal University, Manipal, INDIA.



⁺ Dr. Mohandas Rao KG
Associate Professor of Anatomy
Melaka Manipal Medical College (Manipal Campus)
Manipal University
Manipal, 576 104, INDIA.
☎ +91 984 4380839
✉ mohandaskg@gmail.com

Received September 30th, 2010; accepted June 14th, 2011

ABSTRACT

Axillary arch is an additional muscle slip extending usually from the latissimus dorsi in the posterior fold of the axilla, to the pectoralis major or other neighboring muscles and bones. In the present case presence of such unusual axillary arch innervated by the fine twigs of musculocutaneous nerve has been reported. During routine dissection of axilla region in one of the upper limbs, the occurrence of axillary arch was observed. The muscle fibers were posteriorly continuous with the belly of latissimus dorsi and anteriorly were merging with fleshy fibers of pectoralis major on its deeper surface. The fibers of the axillary arch were innervated by fine twigs from the musculocutaneous nerve. Position of the axillary arch and its critical relationship with neurovascular bundle has been discussed. Further, a detailed literature review was done and the surgical and clinical importance of the case was discussed. © IJAV. 2011; 4: 128-130.

Key words [axillary arch] [musculocutaneous nerve] [axilla] [latissimus dorsi] [pectoralis major]

Introduction

Axillary arch is an additional muscle bundle of various dimensions extending from latissimus dorsi in the posterior fold of the axilla, to the pectoralis major in the anterior fold, to the short head of the biceps brachii or to the coracoid process [1, 2]. Ramsay, in 1795, described the axillary arch for the first time. He gave the description of a muscle bundle connecting pectoral muscle and latissimus dorsi [3]. However, the muscle has been named after Langer who gave the first description of the muscle in 1846 [4]. Incidence of axillary arch is stated to be present in 7% of subjects [5, 6]. Merida-Velasco et al. have reported 4 cases of axillary arch in their study of 64 upper limbs [7]. Various origin, course, insertion, nerve supply, dimensions; structure have been described by different authors. The axillary arch being reported in the present case is unique in its location, relationship with axillary neurovascular bundle and innervation.

Case Report

During routine dissection of the axilla for undergraduate teaching in the Department of Anatomy, Melaka Manipal medical College, Manipal India, an axillary arch crossing the distal part of axillary artery and vein as well as the nerves related to them was observed on the right upper limb of a 55-year-old male cadaver (Figures 1, 2). The fleshy fibers of axillary arch were attached posteriorly to

the belly of latissimus dorsi just proximal to its insertion. Anteriorly the fibers were merging with the fleshy fibers of pectoralis major on its deeper surface. The muscle slip was about 5 cm in length and was passing superficially across the neurovascular bundle (3rd part of axillary artery, distal part of axillary vein, median nerve, and medial cutaneous nerve of forearm and ulnar nerve which are sandwiched between the artery & vein) of the axilla. The fleshy fibers of the axillary arch were innervated by the small twigs of musculocutaneous nerve (Figures 1, 2).

Discussion

The axillary arch is considered as one of the common variations in the axillary region [4]. It has a prevalence of 7–27% [4]. However, the origin, course, insertion, tissue composition, and dimensions of the axillary arch are variable [4]. There are reports of combination of pectoralis quartus and an axillary arch in about 9% of cases [4, 8]. Lee et al. have reported a case of coexistence axillary arch with the variations of the brachial plexus [9].

The axillary arch may arise from the latissimus dorsi muscle, either directly or indirectly with an interposed tendon [4]. An origin of axillary arch from the serratus anterior muscle has also been reported [4]. The most common insertion of axillary arch is as a single muscular band into the muscles including

pectoralis major, pectoralis minor, coracobrachialis, short head of the biceps brachii, teres major or to the coracoid process or to the neighboring axillary or brachial fascia [4, 10, 11]. Tobler reported couple of cases where in one of the cases it was inserted into the fascia covering the biceps brachii and the coracoid process and in the other case insertion was into the pectoralis major tendon (muscular part) and coracoid process (aponeurotic part) [4]. Similarly, the cases of up to three tendinous insertions were reported by Langer and Dharap [4, 12]. An axillary arch reported by Turgut et al., was unique in its attachment. It was originating from the coracoid process of the scapula and extending to the long head of triceps brachii muscle [13]. A case of axillary arch with two slips entrapping neurovascular bundle in axilla is reported by Koshy et al. [14]. Though the attachments of the axillary arch reported in this case are similar to the previous reports, its position and close approximation with the distal part of axillary neurovascular bundle makes it clinically interesting.

Many reports are available describing the innervation of axillary arch by various nerves of axilla. In most of the cases it is innervated by the lateral pectoral nerve [4]. However, Dubreuil-Chambardel found that the nerve supply is variable with five different patterns of innervation in 32 axillary arches [4]. Innervation of axillary arch by a direct branch of pectoral loop was reported by Afshar and Gotalipour [15]. A case of dual slip of axillary arch and their innervation by median nerve is also reported [14]. In the present case it was innervated by musculocutaneous nerve, which is being reported for the first time.

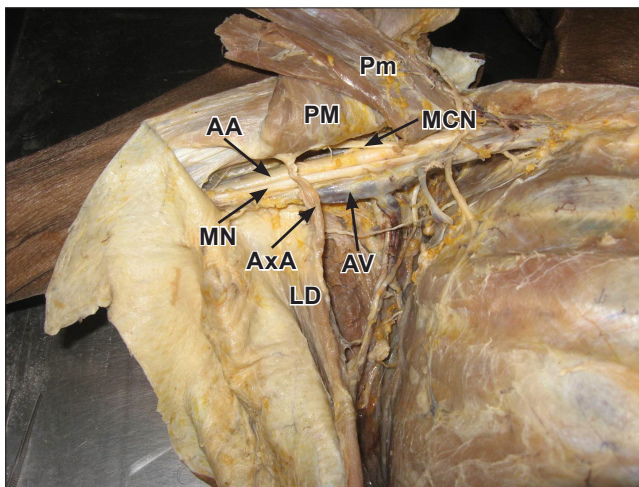


Figure 1. Dissection of the right axilla where the axillary pad of fat and axillary group of lymph nodes have been cleared to expose the axillary arch (AxA), axillary artery (AA), axillary vein (AV) and brachial plexus. Note that the axillary arch is passing anterior to the axillary artery, axillary vein and branches of brachial plexus especially median nerve (MN). (PM: pectoralis major; Pm: pectoralis minor; MCN: musculocutaneous nerve; LD: latissimus dorsi)

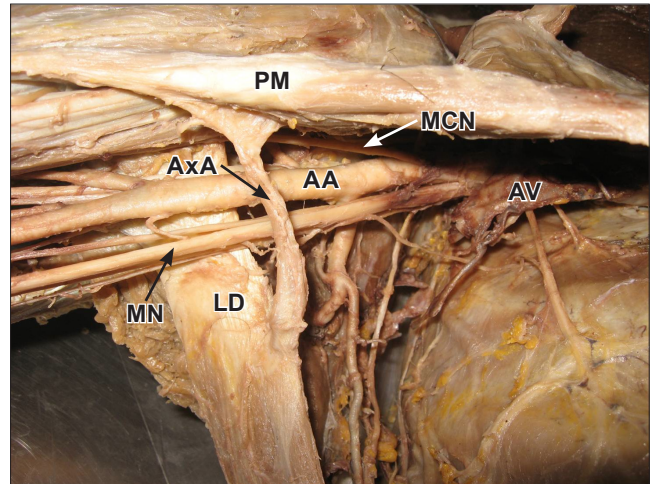


Figure 2. Dissection of the right axilla where the axillary pad of fat and axillary group of lymph nodes have been cleared to expose the axillary arch (AxA) and axillary artery (AA). Axillary vein (AV) has been cut to expose some of the branches of brachial plexus. Note that the axillary arch is passing anterior to the axillary artery, axillary vein and branches of brachial plexus especially median nerve (MN). (PM: pectoralis major; MCN: musculocutaneous nerve; LD: latissimus dorsi)

The most commonly proposed view regarding the phylogenetic origin of axillary arch is that the axillary arch is a remnant of the panniculus carnosus [4]. According to Cihak there are 4 fundamental phases in the ontogenesis of muscle pattern [16]. The axillary arch could have arisen during phases 3 and 4 of ontogenesis of the muscles in the axilla. During phase 3 some muscle primordia from different layers fuse to form a single muscle. However, Grim stated that some muscle primordia disappear through cell death, despite the fact that the cells within them have differentiated to the point of containing myofilaments [17]. Persistence of some cells between latissimus dorsi and teres major may account for the muscular slip in the form of axillary arch. During phase 4, one of the prominent features is the formation of connective tissue elements and their integration with the muscle fibers; the multiple connective tissue attachments in the present case probably formed during this stage.

Knowledge of possible variations in the region of axilla especially axillary arch is essential for the clinicians and surgeons during the clinical examinations and when dealing with any investigative surgical procedures or a case of injury to the axilla. Axillary arch may obscure lymph nodes and may be responsible for compressive pathologies of the axillary vessels and brachial plexus. Hence, surgeons have to keep them in mind during axillary lymphadenectomy [3, 18, 19]. Axillary arch crossing the axillary vessels and causing an obstruction has also been reported [1, 20]. Lin reported a case of contracture of the axillary arch [21]. An axillary arch muscle may be palpable in living subjects and should be borne in mind during clinical examination of the axilla as it may be mistaken for a tumor [4]. In addition,

it is necessary for the radiologist to note the possible variations in the axillary arch as it can be recognized as a soft tissue shadow [22]. According to Ucerler et al., presence of muscular axillary arch causes difficulties in staging lymph nodes, axillary surgery, thoracic outlet syndrome, shoulder instability or cosmetic problems; it should be kept in mind for axillary pathologies [23]. Compression by the muscular axillary arch should be considered in the differential diagnosis of patients with thoracic outlet and hyperabduction syndromes [24]. The potential presence of an axillary arch presents several clinical considerations for the physical therapist. The existence of an axillary arch should be considered in patients with signs and symptoms consistent with upper extremity neurovascular compromise similar to thoracic outlet syndrome. Including this variant in the differential diagnostic process may assist physical therapists in the management of patients with signs and symptoms consistent with thoracic outlet syndrome [25].

The axillary arch reported here adds to the long list of such cases reported earlier. However, the case appears to be

unique as it is a very short slip of fleshy fibers entrapping the axillary neurovascular bundle in the narrow distal part of the axilla. Such compression of these structures would lead to paresthesia, wasting of flexor compartment muscles of the forearm due to the involvement of median nerve (Figure 1). In such patients with entrapment syndrome, surgeon who is aware of the possible variations of the arch can diagnose the case with much ease and safely resect the arch as no functional value for the muscle belly [26]. Being in close relationship with the axillary artery, during any surgical intervention in the axilla, the axillary arch may mislead the surgeons for the application of a ligature. Accidental ligation of the vessels and the nerves may occur during dissection of the axilla, if such a variation is not thought for.

To conclude, we would like to state that it is very essential not only for the anatomists but also for the clinicians and surgeons to be aware of the probable variations of the axillary arch for proper diagnosis and planning of operative treatment. Our observations in the present case will supplement the knowledge of variations.

References

- [1] Kalaycioglu A, Gumusalan Y, Ozen H. Anomalous insertional slip of latissimus dorsi muscle: arcus axillaris. *Surg Radiol Anat.* 1998; 20: 73–75.
- [2] Yuksel M, Yuksel E, Surucu S. An axillary arch. *Clin Anat.* 1996; 9: 252–254.
- [3] Bertone VH, Ottone NE, Lo Tartaro M, García de Quirós N, Domínguez M, Gonzalez D, López Bonardi P, Florio S, Lissandrello E, Biasi E, Medan C. The morphology and clinical importance of the axillary arch. *Folia Morphol (Warsz)*. 2008; 67: 261–266.
- [4] Bonastre V, Rodríguez-Niedenführ M, Choi D, Sañudo JR. Coexistence of a pectoralis quartus muscle and an unusual axillary arch: case report and review. *Clin Anat.* 2002; 15: 366–370.
- [5] Williams P, Bannister L, Collins P, Dyson M, Dussek J, Ferguson M, eds. *Gray's Anatomy*. 38th. Ed., London, Churchill-Livingstone. 1995; 836–837.
- [6] Takafuji T, Igarashi J, Kanbayashi T, Yokoyama T, Moriya A, Azuma S, Sato Y. The muscular arch of the axilla and its nerve supply in Japanese adults. *Kaibogaku Zasshi.* 1991; 66: 511–523. (Japanese)
- [7] Mérida-Velasco JR, Rodríguez Vázquez JF, Mérida Velasco JA, Sobrado Pérez J, Jiménez Collado J. Axillary arch: potential cause of neurovascular compression syndrome. *Clin Anat.* 2003; 16: 514–519.
- [8] Bergman RA. Doubled pectoralis quartus, axillary arch, chondroepitrochlearis, and the twist of the tendon of pectoralis major. *Anat Anz.* 1991; 173: 23–26.
- [9] Lee JH, Choia IJ, Kima DK. Axillary arch accompanying variations of the brachial plexus. *J Plast Reconstr Aesthet Surg.* 2009; 62: e180–e181.
- [10] Schramm U, von Keyserlingk DG. Latissimus arc of the upper arm. *Anat Anz.* 1984; 156: 75–78. (German)
- [11] Loukas M, Noordeh N, Tubbs RS, Jordan R. Variation of the axillary arch muscle with multiple insertions. *Singapore Med J.* 2009; 50: e88–e90.
- [12] Dharap A. An unusually medial axillary arch muscle. *J Anat.* 1994; 184: 639–641.
- [13] Turgut HB, Peker T, Güleken N, Anil A, Karaköse M. Axillopectoral muscle (Langer's muscle). *Clin Anat.* 2005; 18: 220–223.
- [14] Shajan K, Rao MKG, Krishnaswamy N, Somayaji SN. Unilateral axillary arch with two slips entrapping neurovascular bundle in axilla and its innervation by the median nerve. *International Journal of Anatomical Variations (IJAV).* 2009; 2: 113–115.
- [15] Afshar M, Golalipour MJ. Innervation of muscular axillary arch by a branch from pectoral loop. *Int J Morphol.* 2005; 23: 279–280.
- [16] Cihák R. Ontogenesis of the skeleton and intrinsic muscles of the human hand and foot. *Ergeb Anat Entwicklungsgesch.* 1972; 46: 5–194.
- [17] Grim M. Development of the primordia of the latissimus dorsi muscle of the chicken. *Folia Morphol (Praha).* 1971; 19: 252–258.
- [18] Petrasek AJ, Semple JL, McCready DR. The surgical and oncologic significance of the axillary arch during axillary lymphadenectomy. *Can J Surg.* 1997; 40: 44–47.
- [19] Miguel M, Llusá M, Ortiz JC, Porta N, Lorente M, Gützens V. The axillopectoral muscle (of Langer): report of three cases. *Surg Radiol Anat.* 2001; 23: 341–343.
- [20] Sachatello CR. The axillopectoral muscle (Langer's axillary arch): a cause of axillary vein obstruction. *Surgery.* 1977; 81: 610–612.
- [21] Lin C. Contracture of the chondroepitrochlearis and the axillary arch muscles. A case report. *J Bone Joint Surg Am.* 1988; 70:1404–1406.
- [22] Koshy S, Rabi S, Indrasingh I. Supernumerary cleidocervicalis (levator clavicularae) muscle: case report of its rare incidence with clinical and embryological significance. *Eur J Anat.* 2005; 8: 103–106.
- [23] Ucerler H, Ikiz ZA, Pinar Y. Clinical importance of the muscular arch of the axilla (axillopectoral muscle, Langer's axillary arch). *Acta Chir Belg.* 2005; 105: 328–328.
- [24] Rizk E, Harbaugh K. The muscular axillary arch: an anatomic study and clinical considerations. *Neurosurgery.* 2008; 63: 316–319.
- [25] Smith RA Jr, Cummings JP. The axillary arch: anatomy and suggested clinical manifestations. *J Orthop Sports Phys Ther.* 2006; 36: 425–429.
- [26] Hafner F, Seinst G, Gary T, Tomka M, Szolar D, Brodmann M. Axillary vein compression by Langer's axillary arch, an aberrant muscle bundle of the latissimus dorsi. *Cardiovasc Pathol.* 2010; 19: e89–e90.