



Case Report

An unusual case of asymmetrical formation and distribution of median nerve

Published online March 27th, 2011 © <http://www.ijav.org>

Bharat R. SONTAKKE ⁺
Aaditya M. TARNEKAR
Jwalant E. WAGHMARE
Indira V. INGOLE

Department of Anatomy, Mahatma Gandhi Institute of Medical Sciences, Sevagram
 Wardha (Maharashtra), INDIA.



⁺ Dr. Bharat R. Sontakke
 Lecturer
 Department of Anatomy
 Mahatma Gandhi Institute of Medical Sciences
 Sevagram, 442102
 Wardha (Maharashtra), INDIA.
 ☎ +91 7152 284341/ext. 261
 ✉ drbharatsontakke@gmail.com

Received August 12th, 2010; accepted January 29th, 2011

ABSTRACT

During routine dissection of upper extremity of a 70-year-old male cadaver, variation was found in the formation and distribution of median nerve on both sides. On right side, median nerve received contribution from lateral cord twice, once in the axilla as lateral root of median nerve-1 and again in the arm as lateral root of median nerve-2. Lateral root of median nerve-1 contributed most of its fibers to ulnar nerve.

On left side, median nerve had its two roots as usual, lateral root of median nerve and medial root of median nerve. However the lateral root of median nerve crossed the axillary artery anteriorly and formed the median nerve medial to the axillary artery. There was total absence of musculocutaneous nerve on the left side. The muscles of the anterior aspect of the arm, received nerve supply from the median nerve. © IJAV. 2011; 4: 57–60.

Key words [median nerve] [musculocutaneous nerve] [variation]

Introduction

Brachial plexus variations are frequently reported [1–3]. Such variations usually remain asymptomatic and are detected only during surgery, autopsy or cadaveric dissection but rarely they may present clinically with gross functional alteration. Since the emergence of newer diagnostic tools such as computed tomography and magnetic resonance imaging, anatomical variations are more frequently encountered and have much clinical significance [4].

Variations of peripheral nerves of the limbs are revealed better by dissection of limb than by investigative procedures since better exposure of the part provides ready accessibility for detailed morphometry. Purpose of this study was to provide concise and most relevant information about the variation which was detected during dissection with morphometric details.

Case Report

Variations were noted incidentally during routine undergraduate dissection of a 70-year-old male cadaver. The brachial plexus was dissected and the course and distribution of its branches were carefully traced. Following points were noted in the limbs:

Right side: Median nerve received contribution from lateral cord twice, once in axilla as lateral root of median nerve-1

(LRM-1) and again in the arm as lateral root of median nerve-2 (LRM-2) (Figures 1, 2).

LRM-1 passed downwards and medially and crossed 2nd part of axillary artery anterior to it. Few of its fibers then joined with medial root of median nerve (MRM, from medial cord of brachial plexus) to form median nerve-a (MN-a) on the medial aspect of 2nd part axillary artery (Figure 3), while most of the fibers of LRM-1 passed to the ulnar nerve (Figure 4, Table 1). MN-a passed downwards, maintaining medial relation with third part of axillary artery and upper part of brachial artery.

Musculocutaneous nerve and LRM-2 were given off from the lateral cord (Figures 1, 2, 3) about 25 mm below the point of beginning of LRM-1. Course and distribution of musculocutaneous nerve was as usual. LRM-2 passed downwards remaining in close lateral relation to axillary artery. LRM-2 joined with MN-a inside an arterial fork formed by brachial artery anteriorly and profunda brachii posteriorly (Figure 5). Median nerve-b (MN-b) was thus formed behind the brachial artery, 25 mm below the origin of profunda brachii artery, a little below the lower border of teres major muscle (Figure 3). In lower 1/3rd of arm MN-b passed medial to the brachial artery maintaining its usual relationship in cubital fossa (Figure 1). MN-b then continued

in forearm as definitive median nerve along its usual course and distribution.

Left side: Median nerve had its two roots as usual, the lateral root (LRM) and medial root (MRM). There was complete absence of musculocutaneous nerve on this side. LRM passed downwards and medially and crossed 2nd part of axillary artery anteriorly and then united with MRM to form median nerve (MN) on the anteromedial aspect of 2nd part of axillary artery (Figure 6). Coracobrachialis received a branch from MRM, which passed in front of 2nd part of axillary artery and then behind the LRM to reach coracobrachialis (Figure 7). Just after formation of MN, a common nerve trunk arose from it and passed downwards anterolateral to axillary and brachial artery. This trunk provided three motor branches to coracobrachialis, biceps brachii and brachialis and continued as lateral cutaneous nerve of forearm that emerged from the lateral border of biceps as usual.

Discussion

Understanding the embryologic development of the brachial plexus is of importance in explaining the anatomic variations.

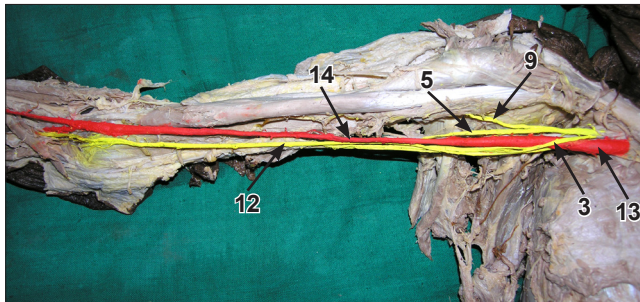


Figure 1. Panoramic view showing relationship of median nerve with brachial artery (right arm). (3: lateral root of median nerve 1; 5: lateral root of median nerve 2; 9: musculocutaneous nerve; 12: median nerve-b; 13: axillary artery; 14: brachial artery)

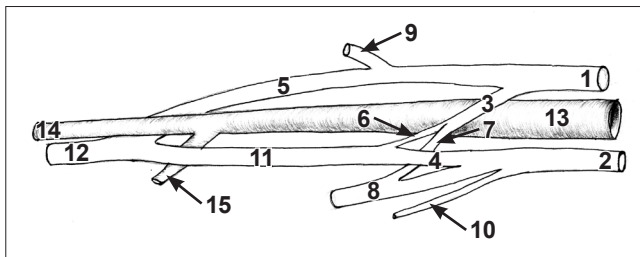


Figure 2. Sketch of right limb showing the scheme of relationship of nerves in axilla and front of arm (guide to figures 3, 4, 5). (1: lateral cord of brachial plexus; 2: medial cord of brachial plexus; 3: lateral root of median nerve 1 [LRM 1]; 4: medial root of median nerve; 5: lateral root of median nerve 2; 6: LRM 1 contributing to median nerve; 7: LRM 1 contributing to ulnar nerve; 8: ulnar nerve; 9: musculocutaneous nerve; 10: medial cutaneous nerve of forearm; 11: median nerve-a; 12: median nerve-b; 13: axillary artery; 14: brachial artery; 15: profunda brachii artery)

The human upper limb bud appears at about 26–27 days of embryonic life and axons of motor neurons of the spinal cord enter the limb buds during the fifth week. Formation of the brachial plexus is evident at about 34–35 days as a single radicular cone in the upper limb. Between 38th and 40th days, the major branches of the brachial plexus such as median, radial and ulnar nerves are visualized which are seen to enter the hand plate. The musculocutaneous nerve arises as an offshoot of median nerve. At about 46th–

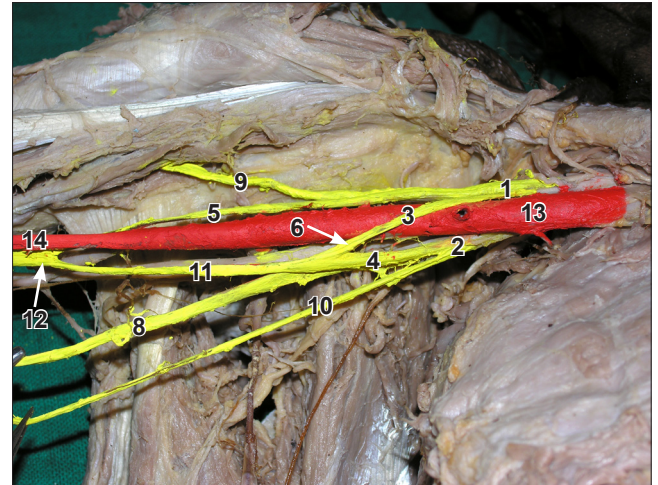


Figure 3. Formation of median nerve from two lateral and one medial roots (right arm). (1: lateral cord of brachial plexus; 2: medial cord of brachial plexus; 3: lateral root of median nerve 1 [LRM 1]; 4: medial root of median nerve; 5: lateral root of median nerve 2; 6: LRM 1 contributing to median nerve; 8: ulnar nerve; 9: musculocutaneous nerve; 10: medial cutaneous nerve of forearm; 11: median nerve-a; 12: median nerve-b; 13: axillary artery; 14: brachial artery)

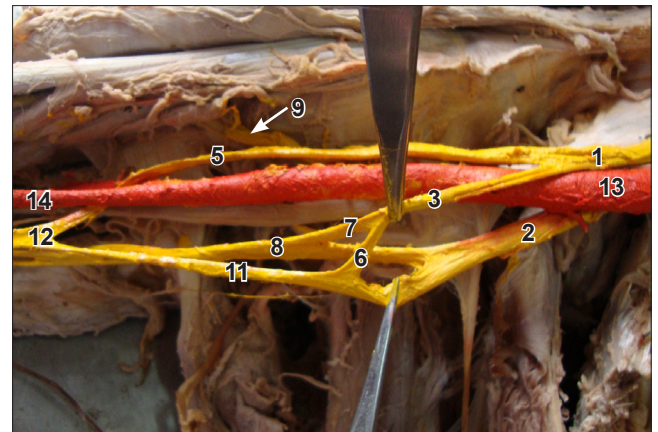


Figure 4. Contribution of lateral root of median nerve 1 (LRM-1) to ulnar nerve and median nerve-a (right arm). (1: lateral cord of brachial plexus; 2: medial cord of brachial plexus; 3: LRM-1; 5: lateral root of median nerve 2; 6: LRM 1 contributing to median nerve; 7: LRM 1 contributing to ulnar nerve; 8: ulnar nerve; 11: median nerve-a; 12: median nerve-b; 13: axillary artery; 14: brachial artery)

Table 1. Morphometric details of relevant nerves.

Name (as per text)	Distance of point of beginning from the reference point* (mm)	Distance of point of termination from the reference point* (mm)	Length (mm)	Circumference (mm)
LRM 1	35	50	48	7 (before contribution to ulnar)
				5 (contributing to ulnar)
LRM 2	28	100	81	10
MRM	42	50	23	10
MCN	28	65	52	10
MN-a	50	100	63	11
MN-b	100	continued in forearm	–	17
Ulnar	42	continued in forearm	–	14

(* Reference point: tip of coracoid process)

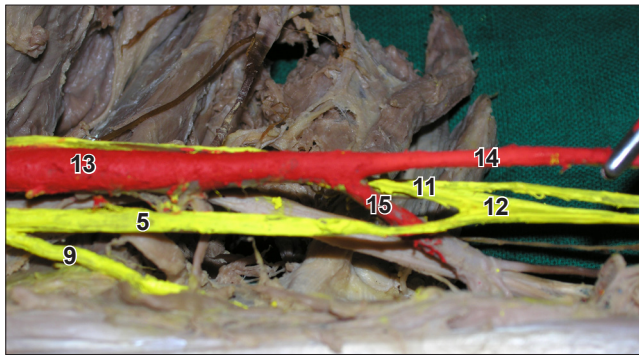


Figure 5. Formation of median nerve-b (MN-b) inside an arterial fork formed by brachial artery anteriorly and profunda brachii posteriorly (right arm). (5: lateral root of median nerve; 9: musculocutaneous nerve; 11: median nerve-a; 12: median nerve-b; 13: axillary artery; 14: brachial artery; 15: profunda brachii artery)

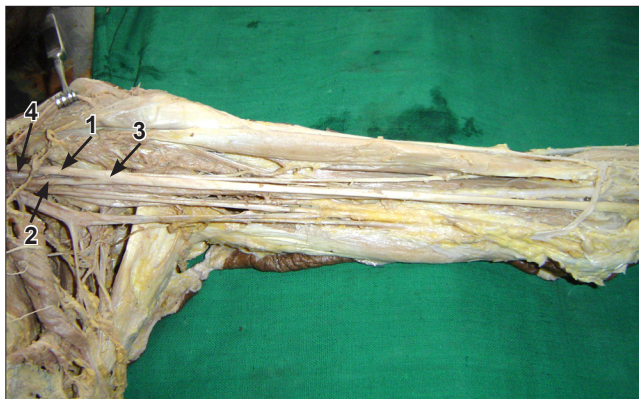

Figure 6. Formation of median nerve anteromedial to axillary artery (left arm). (1: lateral root of median nerve; 2: medial root of median nerve; 3: median nerve; 4: axillary artery)

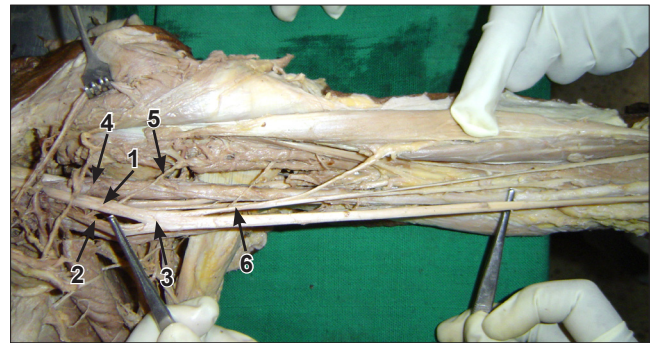


Figure 7. Formation of median nerve anteromedial to axillary artery (left arm). (1: lateral root of median nerve; 2: medial root of median nerve; 3: median nerve; 4: axillary artery; 5: branch to coracobrachialis [from MRM]; 6: common stem from median nerve)

48th days, the upper limb nerves attain definitive adult pattern [5]. The need of brachial plexus arises for ease of distribution of peripheral nerves as each nerve can receive contribution from several spinal segments and one spinal segment can be distributed to several peripheral nerves [6]. Plexus is a complex of branching, reunion and reseparation of nerve fibers that usually happens near the root of limbs, which is axilla for the upper limb. The complex network is sometimes extending in to the arm. The roots of MCN and the LRM are same, i.e. C5, C6 and C7. In the present case in absence of MCN the same roots have travelled through the LRM and are distributed in the muscles of the front of arm via median nerve. However, our finding of a branch of MRM given to the coracobrachialis point to two possibilities either MRM has received C5 root or the myotomes of the coracobrachialis originated from C8 or T1 segments. There is neither any such report available in literature nor could we trace any connection of C5 or C6 roots with medial cord of

brachial plexus on left side. There is a change in relationship of LRM with axillary artery on left side where the LRM has crossed the front of artery from lateral to medial side to form the median nerve anteromedial to axillary artery, unlike the usual case of MRM crossing the artery from medial to lateral to form the median nerve anterolateral to axillary artery. The change in relationship between cords of brachial plexus and axillary artery might be due to a change in the source of the subclavian artery, from the usual 7th segmental artery which is between lateral and medial cords, to 6th or 8th segmental artery which will cause medial or lateral displacement of cords in relation to artery respectively [7]. However, it does not explain the formation of median nerve anteromedial to axillary artery in the present case.

As each peripheral nerve of a limb is derived from plexus, its contributing roots cannot always be traced in the routine dissection. Ulnar nerve has a root value of C7, C8 and T1. Presence of C7 (or even C6 or higher roots) in ulnar nerve is seldom realized in dissection though it is believed to be entering the nerve through the roots of median nerve [8]. It has been documented that the C7 root of ulnar nerve emerges from lateral cord, either through the roots of median nerve, or as an independent fascicle 'the lateral root of ulnar nerve' in the axilla or arm [9]. Our finding of LRM-1 on right side, contributing almost 80% of its fibers to ulnar nerve and only 20% to MN-a (Table 1, Figures 3, 4), can be conveniently considered as lateral root of ulnar nerve, which the undergraduate students seldom find in routine dissection. Hollinshead W. H. mentioned about supply to thenar group of muscles by ulnar nerve especially when it carries additional roots from cervical nerves [8]. We have carefully observed the distribution of ulnar nerve in forearm and hand but we did not find any unusual branch arising from ulnar nerve to supply a structure other than what it usually supplies.

The median nerve of right side (MN-b) was formed after receiving LRM-2 at a level slightly distal (upper part of arm) to usual location (axilla). Furthermore MN-b was formed posterior to brachial artery. The changed relationship of median nerve and brachial artery seems to be due to persistence of superficial brachial artery and regression of primitive axial artery, the former lying anterior and the latter posterior to median nerve [10]. Thus the right brachial artery seems to have developed from superficial brachial rather than primitive axial artery. Formation of median nerve posterior to brachial artery is seldom found in literature. Chitra has reported formation of median nerve behind the 3rd part of axillary artery [11].

Variant nerves, in terms of unusual beginning, course or distribution, are usually prone for injuries and entrapment neuropathies [12]. Precise knowledge of such variations helps clinicians in correct interpretation of unusual clinical findings, clinical neurophysiological tests and radiological images. It also helps anesthetist in proper planning of brachial plexus blocks [13], and orthopedists for routine and reconstructive operations in arm [14]. The close relationship of the variant lateral root of the median nerve with the axillary artery may result in arterial compression leading to ischemic pain or arterial insufficiency during certain postural maneuvers of the shoulder joint [15]. Finally it is always beneficial for the anatomist to be vigilant for encountering such variations during dissection.

Acknowledgement

Authors gratefully acknowledge the technical assistance of Mr. V. P. Kavinesan, Mr. Satish Shingare and Mr. Ashok Wahiwarkar.

References

- [1] Choi D, Rodriguez-Niedenfuhr M, Vazquez T, Parkin I, Sanudo JR. Patterns of connection between the musculocutaneous and median nerves in the axilla and arm. *Clin Anat.* 2002; 15: 11–17.
- [2] Pandey SK, Shukla VK. Anatomical variations of the cords of brachial plexus and the median nerve. *Clin Anat.* 2007; 20: 150–158.
- [3] Uyaroglu FG, Kayahoglu G, Erturk M. Anastomotic branch from the median nerve to the musculocutaneous nerve: a case report. *Anatomy.* 2008; 2: 63–66.
- [4] Aydin ME, Kale A, Edizer M, Kopuz C, Demir MT and Corumlu U. Absence of the musculocutaneous nerve together with unusual innervation of the median nerve. *Folia Morphol (Warsz).* 2006; 65: 228–231.
- [5] Moore KL, Persaud TVN. The Developing Human. Clinically Oriented Embryology. 7th Ed., Philadelphia, Saunders. 2004; 409–423.
- [6] Sinhatamby CS. Last's Anatomy. Regional and Applied. 11th Ed., New York, Churchill Livingstone Elsevier. 2006; 1–34.
- [7] Hollinshead WH. Anatomy for Surgeons. 3rd Ed., Philadelphia, Harper and Row. 1982; 259–340.
- [8] Hollinshead WH. Anatomy for Surgeons. 2nd Ed., New York, Harper and Row. 1969; 207–263.
- [9] Rosse C, Gaddum-Rosse P. Hollinshead's Textbook of Anatomy. 5th Ed., Lippincott-Raven. 1997; 193–237.
- [10] Rodriguez-Baeza A, Nebot J, Ferreira B, Reina F, Perez J, Sanudo JR, Roig M. An anatomical study and ontogenetic explanation of 23 cases with variations in the main pattern of the human brachio-antebrachial arteries. *J Anat.* 1995; 187: 473–479.
- [11] Chitra R. A rare variant formation of median nerve: a case report. *Internet Journal of Neurology.* 2007; 8(2).
- [12] Bilecenoglu B, Uz A, Karalezli N. Possible anatomic structures causing entrapment neuropathies of the median nerve: an anatomic study. *Acta Orthop Belg.* 2005; 71: 169–178.
- [13] Orebaugh SL, Pennington S. Variant location of the musculocutaneous nerve during axillary nerve block. *J Clin Anesth.* 2006; 18: 541–544.
- [14] Nayak S. Absence of musculocutaneous nerve associated with clinically important variations in the formation, course and distribution of the median nerve – a case report. *Neuroanatomy.* 2007; 6: 49–50.
- [15] Saeed M, Rufai AA. Median and musculocutaneous nerves: variant formation and distribution. *Clin Anat.* 2003; 16: 453–457.