

Case Report

An anatomical study of double brachial arteries — a case report

Published online February 23rd, 2010 © <http://www.ijav.org>

Bojana KRSTONOSIC †

Biljana SRDIC

Dusica MARIC

Radmila GUDOVIC

Sasa MIJATOV

Sinisa S. BABOVIC

Department of anatomy, Medical Faculty, University of Novi Sad, SERBIA.



† Bojana Krstonosic
Department of Anatomy
Medical Faculty
University of Novi Sad
Hajduk Veljkova 3, 21000 Novi Sad, SERBIA.
☎ +381 21 6615775
✉ bojana.80@unet.rs

Received October 12th, 2009; accepted January 21st, 2010

ABSTRACT

Superficial brachial artery is one of the major variations of the arterial pattern in the upper limb. During routine anatomical dissection in our department, we observed a case of unilateral double brachial artery in a formalin-fixed female cadaver.

Left axillary artery entered into the anterior region of the arm, where it branched into two brachial arteries – the superficial brachial artery (SBA), which was longer, tortuous and with a smaller caliber, and the brachial artery (BA), which was placed deep and medially. In the cubital fossa, covered with an aponeurosis of the biceps brachii muscle, both brachial arteries were connected with an anastomotic vessel. Under this anastomotic branch, in the forearm, SBA continued as the radial artery, whereas BA continued as the ulnar artery.

Variations of the arterial pattern in the upper limb are undoubtedly of interest to the anatomists as well as to the clinicians. © *IJAV*. 2010; 3: 6–8.

Key words [brachial artery] [superficial brachial artery] [arterial variations]

Introduction

Variations of the arterial patterns in the upper limb have been the subject of many anatomical studies due to their high incidence. Variations in the branching pattern of the major arterial trunks have been reported with an incidence of up to 20% in human adult limbs and they have been the subject of much controversy since the beginning of the nineteenth century [1].

The presence of the arterial variations in the upper limb may be due to chemical factors, hemodynamic forces, fetal position in the uterus, genetic predisposition, and developmental changes [1].

A superficial brachial artery is defined as a brachial artery which has a superficial course to the median nerve, whereas a deep brachial artery corresponds to the brachial artery, with its normal course behind the median nerve [2].

In this report we described a case of superficial brachial artery as an anatomical variation of arterial pattern in the upper extremity.

Case Report

During a routine dissection in the Department of Anatomy at Medical Faculty in Novi Sad, we found a case of the superficial brachial artery in the left upper limb of an 80-year-old white female cadaver, which was fixed in formalin.

Left axillary artery, at the level of the lower border of teres major muscle, left the axillary fossa and entered into the

anterior area of the arm, in which upper third it divided into two brachial arteries. These arteries lay next to each other in the normal path of the brachial artery. Arteria brachialis I (the superficial brachial artery – SBA) was placed superficially and laterally, compared to arteria brachialis II (brachial artery – BA), which was placed deeply and medially. SBA was longer (approximately 30 cm) and tortuous. BA was smaller (approximately 28 cm) and had the same caliber as axillary artery at the beginning, but after giving the deep brachial artery, it became narrower (Figure 1). Also, it gave off the superior

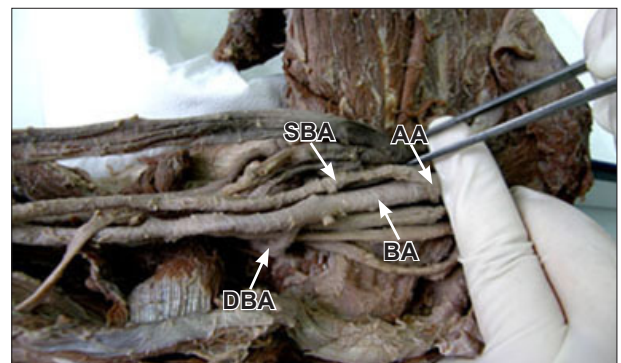


Figure 1. Photograph of the left upper limb, the axillary region, showing the origin of the superficial brachial and brachial artery from the axillary artery. (SBA: superficial brachial artery; BA: brachial artery; AA: axillary artery; DBA: deep brachial artery)

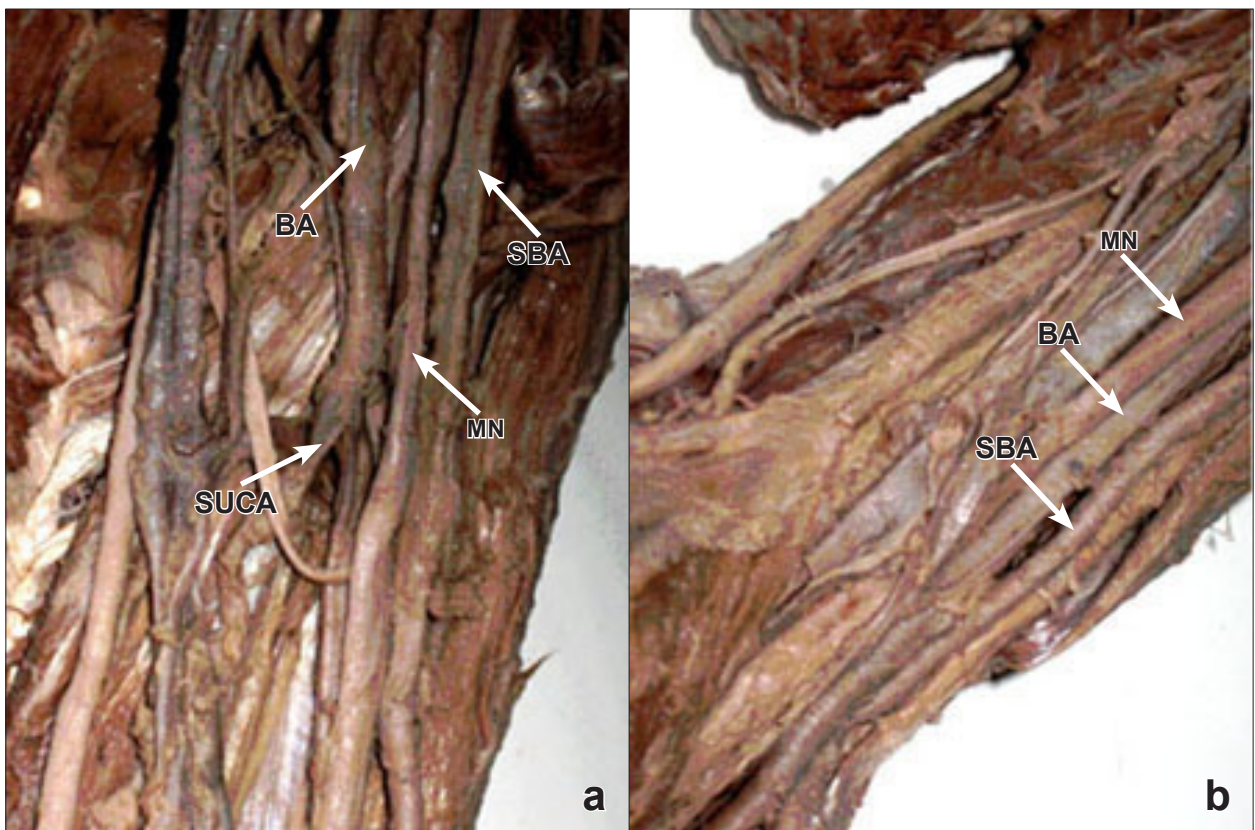


Figure 2. Photographs of the left upper limb showing the relation between double brachial artery and median nerve. **a)** Median nerve is placed between two brachial arteries in the arm. **b)** In the cubital fossa, median nerve is placed on the medial side of brachial artery. (*SBA: superficial brachial artery; BA: brachial artery; MN: median nerve; SUCA: superior ulnar collateral artery*)

ulnar collateral artery, a few muscular branches and the branch to supply the humerus. The superficial brachial artery was crossing over the medial root of the median nerve in the upper and middle thirds of the arm, descended with superficial course to the median nerve. So, the median nerve was placed between two brachial arteries (Figure 2a). In the inferior third of the arm, the median nerve crossed over the brachial artery, from its lateral to medial side (Figure 2b). In the cubital fossa, about 3 cm below the crease of the elbow, the superficial brachial artery joined the brachial artery with an anastomotic branch placed under an aponeurosis of the biceps brachii muscle. This connecting blood vessel was about 1-1.5 cm long and 0.4-0.7 cm wide (Figure 3). In the forearm, the superficial brachial artery continued as radial artery, whereas the brachial artery continued as ulnar artery.

Discussion

Variations of the arterial patterns in the human upper limb have been the subject of many anatomical studies. De Vriese mentioned the initial capillary network as an origin of the arteries in the upper limb, in human [3]. Muller thought that arterial system was developed as a common sprout of superficial and deep pathways [4]. So, both of them suggested that arterial pattern was the result of the primitive networks. Singer, on the other hand, described the sprouting process from the axial arterial trunk as a main pathway in the arterial development in

the human upper extremities [5]. According to Jurjus et al. variations in arterial blood vessels may occur as a result of: a- the choice of unusual paths in the primitive vascular plexus, b- the persistence of vessels normally obliterated, c- the disappearance of vessels normally retained, d- incomplete development, e- fusion of parts which are usually distinct [6]. Also, the presence of variations may be due to hemodynamic forces, chemical factors and genetic predisposition.

Anatomical variations of the typical arterial pattern of the human upper limb are well documented. They are considered quite common, as their incidence is up to 20% [7,8].

Axillary artery in its third part is divided into two branches [9]. One of its divisions, which passes superficial to median nerve, is named the superficial brachial artery by Adachi [10]. Keen suggested that the superficial brachial artery is in fact high origin of the radial artery [11]. In present case, there was a possibility that the superficial brachial artery was a high origin and persisting radial artery, similarly as it was described by Jurjus et al. [12]. Kodama observed the radial artery as a continuation of the superficial brachial artery and the ulnar artery as a continuation of brachial artery [13]. Rodriguez-Baeza et al. reported that the superficial brachial artery ended by anastomosing with the radial artery in the cubital fossa, and in few cases it continued as antebrachial artery [14].

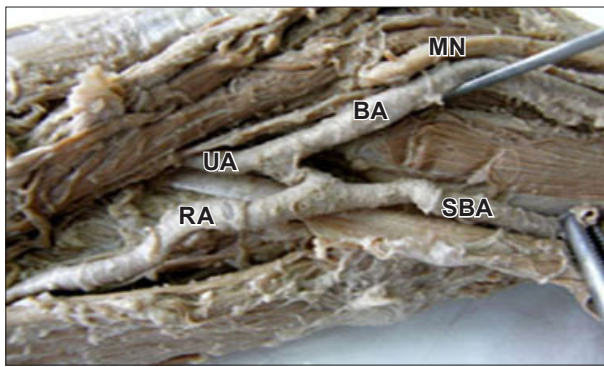


Figure 3. Photograph of the left cubital fossa showing the anastomotic artery connecting two brachial arteries. (*SBA*: superficial brachial artery; *BA*: brachial artery; *RA*: radial artery; *UA*: ulnar artery; *MN*: median nerve)

Jayakumari et al. described a case of two axillary arteries: the axillary artery I, which was superficial, tortuous and placed medial to the median nerve, continued as brachial artery I, whereas the axillary artery II, which was deeper and slender, continued as brachial artery II [15]. In the cubital fossa, the brachial artery II terminated by anastomosing with brachial artery I, where the latter is divided into radial and common interosseus arteries. In our case, we observed two branches of axillary artery: superficially placed branch, as brachial artery I, which was tortuous, longer and positioned laterally compared to deeply placed brachial artery II, which had the same position and course as a normal brachial artery.

According to Yang et al., the superficial brachial arteries were classified into three types: type I - the superficial brachial artery bifurcated into the radial and ulnar arteries in the cubital fossa; type II (i.e. superficial radial artery) – it continued as the radial artery; type III – the slender superficial brachial artery supplied the arm

musculature and ended in the arm [16]. In the present case, both brachial arteries were connected in the cubital fossa with an anastomotic blood vessel, below which the superficial brachial artery continued as radial artery and the brachial artery continued as ulnar artery. Like we did, Tohno et al. reported an anastomotic branch in the cubital fossa, by which superficial brachial artery joined brachial artery [2]. Brachioradial artery, defined as a high origin of a radial artery, anastomosed with the deep brachial artery in the cubital fossa [8]. We considered that the knowledge of the anastomotic blood vessel, particularly its position in the cubital fossa, could be of great importance to the clinicians; however, in the available literature we did not find a precise description of its position and dimensions.

The incidence of the superficial brachial artery, which originates from the axillary artery was reported as 3% by Muller [4], 0.24% by Adachi [10], 0.1% and 12.2% by Yang et al. [16].

The prevalence of persistent superficial brachial artery was observed mostly in the right upper limb [2,18]. In our case we described the superficial brachial artery in the left human arm, the same as Coskun et al. did [17].

The existence of such variation of upper extremity is clinically important. It may complicate intravenous drug administration and venipuncture in general, also percutaneous brachial catheterization. Artery may be mistaken for a vein. Its superficial course makes it more prone to injury, which may result in bleeding. Furthermore, the presence of superficial brachial artery can cause misinterpretation of incomplete angiographic images.

Doppler ultrasound provides a confident diagnosis of this anatomical variation.

Knowledge of this variation is important, not only to anatomists, but also to radiologists, orthopedists, vascular and plastic surgeons.

References

- Rodriguez-Niedenfuhr M, Burton GJ, Deu J, Sanudo JR. Development of the arterial pattern in the upper limb of staged human embryos: normal development and anatomic variations. *J Anat.* 2001; 199: 407–417.
- Tohno Y, Tohno S, Azuma C, Kido K, Moriwake Y. Superficial brachial artery continuing into the forearm as the radial artery. *J Nara Med Assoc.* 2005; 56: 189–193.
- De Vriese B. Recherches sur l'évolution des vaisseaux sanguins des membres chez l'homme. *Archives de biologie.* 1902; 18: 665–730.
- Muller E. Beiträge zur Morphologie des Gefäßsystems. I. Die Arterien des Menschen. *Anatomischer Hefte.* 1903; 22: 377–575.
- Singer E. Embryological pattern persisting in the arteries of the arm. *Anatomical Record.* 1933; 55: 403–409.
- Jurjus AR, Correa-De-Araujo R, Bohn RC. Bilateral double axillary artery: embryological basis and clinical implications. *Clin Anat.* 1999; 12: 135–140.
- Rodriguez-Niedenfuhr M, Sanudo JR, Vazquez T, Nearn L, Logan B, Parkin I. Anastomosis at the level of the elbow joint connecting the deep, or normal, brachial artery with major arterial variations of the upper limb. *J Anat.* 2000; 196: 115–119.
- Rodriguez-Niedenfuhr M, Vazquez T, Nearn L, Ferreira B, Parkin I, Sanudo JR. Variations of the arterial pattern in the upper limb revisited: a morphological and statistical study, with a review of the literature. *J Anat.* 2001; 199: 547–566.
- Patnaik VVC, Nalsey G, Singla RK. Bifurcation of axillary artery in its 3rd part – a case report. *J Anat Soc India.* 2001; 50: 166–169.
- Adachi B. Das Arteriensystem der Japaner. *Kyoto, Maruzen Press.* 1928; 1: 285–356.
- Keen JA. A study of the arterial variations in the limbs with special reference to symmetry of vascular patterns. *Am J Anat.* 1961; 108: 245–261.
- Jurjus A, Sfeir R, Bezdjrdjan R. Unusual variation of arterial pattern of human upper limb. *Anat Rec.* 1986; 215: 82–83.
- Kodama K. Arteries of the upper limb. In: Sato T, Akita T, eds. *Anatomic Variations in Japanese.* Tokyo, University of Tokyo Press. 2000; 220–237.
- Rodriguez-Bacza A, Nebot J, Ferreira B, Reina F, Perez J, Sanudo JR, Roig M. An anatomical study and ontogenetic explanation of 23 cases with variations in the main pattern of the human brachio-antebrachial arteries. *J Anat.* 1995; 187: 473–479.
- Jayakumari S, Rath G, Arora J. Unilateral double axillary and double brachial arteries. Embryological basis and clinical implications. *Int J Morphol.* 2006; 24: 463–468.
- Yang HJ, Gil YC, Jung WS, Lee HY. Variations of the superficial brachial artery in Korean cadavers. *J Korean Med Sci.* 2008; 23: 884–887.
- Coskun N, Sarikcioglu L, Donmez BD, Sinsel M. Arterial, neural and muscular variations in the upper limb. *Folia Morphol (Warsz).* 2005; 64: 347–352.
- Natsis K, Papadopoulou AL, Paraskevas G, Tottis T, Tsikaras P. High origin of a superficial ulnar artery arising from the axillary artery: anatomy, embryology, clinical significance and review of the literature. *Folia Morphol (Warsz).* 2006; 65: 400–405.