

# Amyand's hernia: "Jack in the box" - A Case report with a review of literature

Dr. Uwais Riaz Ul-Hasan M. Med\*, Dr. Khatija Hasan M. Med, Dr. Alaedin Ramadan Ph.D, Dr. Moath Abdul-Aziz Al-Masoud M.D, Dr. Ali Hussain Al-Khars M.D, Dr. Mohammed Ahmed Alobaid M.D

Ul-Hasan UR, Hasan K, Ramadan A, et al. Amyand's hernia: "Jack in the box" - A Case report with a review of literature. *Surg Case Rep.* 2020;4(1):6-9

## ABSTRACT

Inguinal hernia is one of the most common performed surgery in General Surgical practices worldwide. Amyand's hernia on the other hand is one of the rarest forms of inguinal hernia where the appendix is found as content in the hernia sac. It

has a reported incidence of 1% and this condition is named after the French Surgeon Claudius Amyand (1660-1740) to King George II, who performed the first successful appendectomy in a young male with an inguinal hernia with an inflamed appendix. We report a case of a Middle aged male with right sided inguinal hernia with intermittent pain in the abdomen along with the management of the four types of Amyand's hernia.

Key Words: *Hernia; Amyand's hernia appendix; Role of ultrasound; Hernia classification*

## INTRODUCTION

Inguinal hernia is frequently encountered in surgical practice and most often diagnosed in the preoperative clinical setting. The Amyand's hernia is often an intraoperative diagnosis. The usual contents of inguinal hernia open repairs include bladder, ovaries, fallopian tubes the finding of caecum with appendix is a rare encounter. With the availability of a bed side USG at the surgeon's disposal a preoperative diagnosis is plausible only if considered as a differential, and this aids preoperative planning. Other factors that contribute to the increase morbidity are age, comorbidities, and local factors associated with the appendix viz inflamed or not and the state of the inguinal canal posterior wall laxity, diameter of the deep ring. The Losanoff and Basson classification of Amyand's hernia [1] is discussed along with a review of literature.

## CASE REPORT

A 50-year-old Middle Eastern male presented in the clinic with a history of gradually progressive right sided groin swelling with intermittent lower abdominal pain.

On physical examination he had a right sided inguinal swelling that was reducible and tender to examination this swelling had no scrotal extension. He had no nausea or vomiting. Our initial Clinical diagnosis was an obstructed hernia. An USG of the right groin revealed a blind ended tubular appendage (The appendix) in the inguinal canal a type II Amyand's hernia that was confirmed and reported by our radiologists, using a non-contrast CT scan.

A routine lab test showed an increase in WBC and CRP. He had undergone an uneventful open repair of hernia with appendectomy and a polypropylene mesh placement. Intraoperative finding of a type II Amyand's hernia were compatible with our pre-operative diagnosis. He had an eventful recovery and is currently on follow up in clinic.

## DISCUSSION

Claudius Amyand was a French Surgeon who in 1735 was the first to operate on a young 11 year old boy with groin swelling with an enterocutaneous fistula following accidental needle ingestion and was found intraoperatively to have a vermiform appendix in the hernial sac [2,3]. There are a little over 10 cases reported worldwide. Amyand's hernia is rare and therefore impossible to diagnose in the clinical setting. In fact a right inguinal hernia swelling that is tender on examination is confidently diagnosed by the surgeon as an obstructed hernia until the hernial sac is opened intraoperatively; It is aptly called a hernia appendix. With advancing technology and the easy

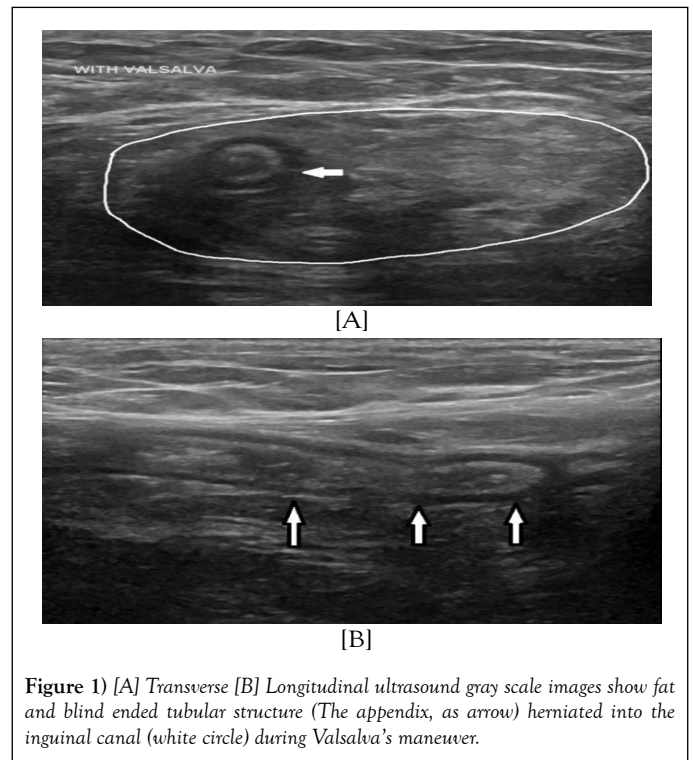


Figure 1) [A] Transverse [B] Longitudinal ultrasound gray scale images show fat and blind ended tubular structure (The appendix, as arrow) herniated into the inguinal canal (white circle) during Valsalva's maneuver.

availability of bedside tools like the Ultrasound, It should be easy to pick it up in the preoperative period provided it is considered as a differential in a right sided inguinal swelling. The reported sensitivity of the ultrasound is 93% to 100% [4]. The features of a blind ending tubular appendage that is non compressible, non-peristaltic with a diameter of 6mm and the appendix wall hyperemia on a color Doppler are characteristic findings. Obstructive and complicated cases of appendicitis are characterized by appendicoliths, pericaecal inflammation and free fluid collection in the pelvic cavity [5,6].

Amyand's hernia is more common in the pediatric age group when compared to adults and in adults it is relatively more common in males than females. Within the female age group they are relatively uncommon in the older female age group [7]. The appendix can be found in Umbilical

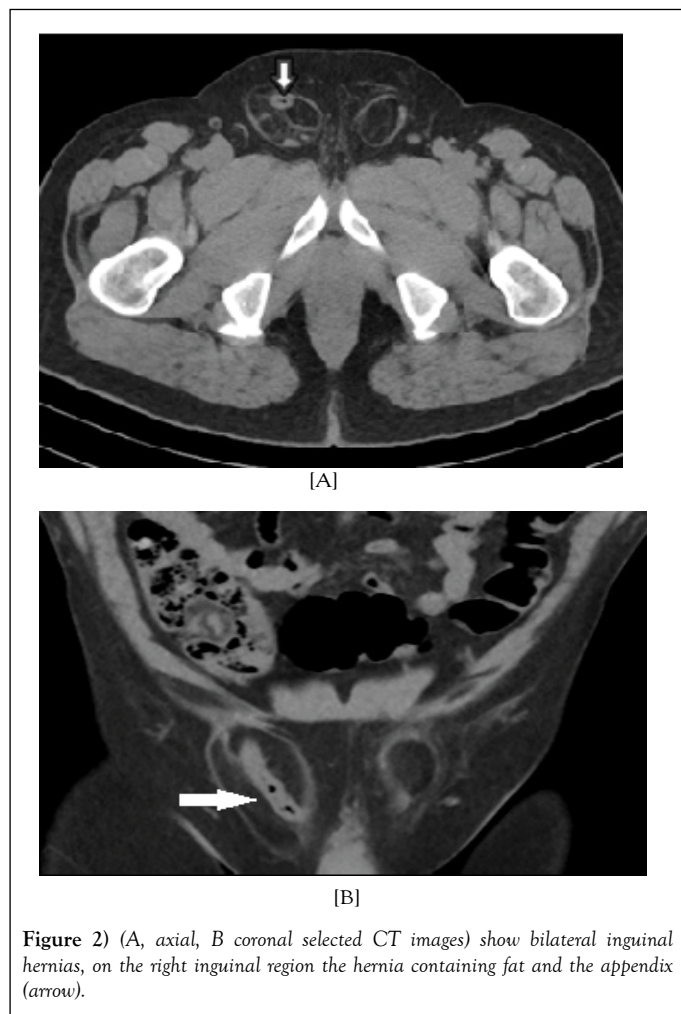Department of General Surgery and Radiology, Al-Omran General Hospital, Al-Hassa, Kingdom of Saudi Arabia

Correspondence: Dr. Uwais Riaz Ul-Hasan, Department of General Surgery and Radiology, Al-Omran General Hospital, Al-Hassa, Kingdom of Saudi Arabia, e-mail [Druwaisriazulhasan@gmail.com](mailto:Druwaisriazulhasan@gmail.com); DOI: 10.37532/pulsr.2020.12(4).6-8,

Received: September 24, 2019, Accepted: February 03, 2020, Published: February 10, 2020



This open-access article is distributed under the terms of the Creative Commons Attribution Non-Commercial License (CC BY-NC) (<http://creativecommons.org/licenses/by-nc/4.0/>), which permits reuse, distribution and reproduction of the article, provided that the original work is properly cited and the reuse is restricted to noncommercial purposes. For commercial reuse, contact [reprints@pulsus.com](mailto:reprints@pulsus.com)



hernias, femoral hernia, obturator hernias and even incisional hernias [8]. The incidence of appendicitis in an inguinal hernia is reported to be 0.1% [9,10]. It has been postulated that in an Amyand's hernia anatomically the appendix is predisposed relatively superficial in the groin and repeated abdominal muscle contractions during activity constrict the deep hernial orifice thereby inducing ischemia of the appendix, and then appendicitis, repeated contractions also induce incarceration by repeated inflammation and fibrosis. The anatomically superficial location of the appendix in an Amyand's hernia makes it susceptible to external trauma as well. The other postulated mechanism is the presence of a mobile caecum that enables the appendix to herniate into the inguinal sac [7]. The pathophysiology in an Amyand's hernia is extraluminal compression rather than an intraluminal obstruction [11] that leads to appendicitis. The complications of an inflamed appendix include abscess formation, perforation, sepsis and enterocutaneous fistula formation. The reported risk of thrombotic complications with appendicitis in patients with an Amyand's hernia is high [12]. If not operated upon complications include incarceration, strangulation, perforation, peritonitis, and the formation of an enterocutaneous fistula. It is imperative therefore to consider Amyand's hernia in the differential diagnosis for groin masses in addition to incarcerated or obstructed hernias, abscess, lymphogranuloma venerum, a Richter's hernia and a Littre's hernia.

The choice of operative treatment follows Principles of surgery and Surgeon experience. Uncomplicated Amyand's hernia can be approached by laparoscopic or open hernia repair with or without a mesh placement. If mesh placement is contraindicated a Mc Vay repair or a shouldice repair to reduce the recurrence rates [13]. Complicated cases of Amyand's hernia with inguinal abscess are preferably dealt with a laparoscopic approach. Frank peritonitis on the other hand should be approached through a conventional laparotomy.

The Nyhus classification is the most commonly employed anatomic classification for inguinal hernias. The Bendavid Classification lays emphasis on the Type, Staging, and Dimension (TSD system), the five types of groin hernias and three subtypes for each type. Losanoff and Basson in 2008 came

TABLE 1

Losanoff and Basson Classification (2008)

	Anatomical Location	Operative Procedure
Type 1	Normal appendix in inguinal canal	Hernia reduction, mesh repair, appendectomy only in young patients.
Type 2	Appendicitis in inguinal canal no abdominal sepsis	Appendectomy through hernia, primary repair sepsis hernia, no mesh placement.
Type 3	Appendicitis in inguinal canal, or abdominal wall or peritoneal sepsis	Laparotomy with appendectomy, with primary repair of hernia, no mesh placement
Type 4	Acute appendicitis In inguinal hernia, Related or un-Related abdominal Pathology	Management as for type 1-3 hernia, to investigate or treat second pathology as appropriate.

up with a classification (Table 1) of Adult Amyand's Hernia, Type I are uncomplicated Normal Appendix for which they recommend a patch repair with or without an appendectomy. A type II Amyand's hernia is a hernia with appendicitis but confined to hernial sac for which an appendectomy with a bio patch or simple repair is the procedure of choice. Type III Amyand hernias are complicated cases with peritonitis necessitating a laparotomy with on orchidectomy or even a Right hemicolectomy depending on the clinical scenario. Type IV Amyand's Hernia are also included under complicated cases in which a hernia with severe complications that require a laparotomy and to proceed with treatment as per the clinical scenario. A prosthetic patch repair is not recommended in these complicated cases of Amyand's hernia or those with abdominal infections [14]. A biological patch mesh is a feasible and recommended alternative the reason being the fibrous tissue deposition mimics normal fascia regeneration in wound healing. Bio patches if enveloped with collagen and or stromal cells have the advantage of causing delayed absorption usually after five to six months which gives ample time for inguinal hernia repair and thereby reduce recurrence rates [15]. In the pediatric age group the recommended operative procedure is to perform a High ligation with or without an appendectomy. In modern era there is a definite role for laparoscopic surgery provided it is picked up in the perioperative period both in the adults and in pediatric age groups there are instances even as early as in the neonatal period [16,17].

CONCLUSION

Amyand's hernia is an uncommon condition. A preoperative diagnosis by an ultrasound by the clinician aids in diagnosis and subsequent preoperatively surgical planning. A Doppler ultrasound confirms signs of inflammation in cases of doubt a CT scan are diagnostic. The operative procedure itself may be performed through a traditional open or laparoscopic approach depending on the institution and the individual surgeon experience.

REFERENCES

1. Lasanoff JE, Basson MD. Amyand hernia: A classification to improve management. *Hernia J Hernia Abdominal Wall Surg.* 2008;12:325-326.
2. Amyand C An inguinal hernia rupture with a pin in caeci incrustrated with stone and observations on the wounds in the gut. *Phil Trans R Soc Lond*1736;39:329-336.
3. Ghafouri A, Anbara T, Foroutankia R. A rare case report of appendix and caecum in the sac of left inguinal hernia (Left Amyland hernia). *Med J Islam Repub Iran.* 2012;26:94-95.
4. Light D, Ratnasingham K, Banergee A, et al. The role of ultrasound scans in the diagnosis of occult inguinal hernia. *Int J Surg.* 2011;9(2):169.
5. Sharma G, Shekhawat NS, Memon B, et al. Amylands hernia: A report of 18 consecutive patients over 15 year's period. *Hernia.* 2007;11:31-35.
6. Lee JH. Sonography of acute appendicitis. *USG CT and MR.* 2003;24:83-90.
7. Stone MB, Chao J. Emergency USG diagnosis of acute appendicitis. *Acad Emergency Med.* 2010;17:E5.
8. Galyna I, Amyands hernia - A review. *Med Sci Monit,* 2014;20:140-146.

9. Ravishankaran P, Mohan G, Srinivasan A, et al. Left-sided Amyand hernia: A rare occurrence: A case report. *Indian Journal of Surgery*. 2013;75:247-248.
  10. Ivashchuk G, Cesmebasi A, Sorenson EP, et al. Amyands Hernia: A review *Medical Science Monitor: International Medical Journal of Experimental and Clinical Research*. 2014;20: 140-146.
  11. Johnson CD. Appendicitis in the external hernia. *Ann Royal College Surgeon England, UK*. 1982;64:283.
  12. Wilson TD, Rao V, Podbielski FJ, et al. *In situ* Aortic thrombosis secondary to an intra-abdominal abscess. *Am J Case Rep*. 2012;13:149-152
  13. Morales CA, Ploneda VCF, Sainz EVH, et al. Amyand hernia: A case report and review of the literature. *Ann Med Surgery* 2015;4:113-115.
  14. Abu DJ, Urca I. Incarcerated inguinal hernia with a perforated appendix and periappendicular abscess: A report of a case. *Dis Colon Rectum*.1972;15:464-465.
  15. Sharma H, Gupta A, Shekhawat NS, et al. Amyand's Hernia: A report of eighteen consecutive patients over fifteen years. *Hernia* 2007;11:31-35.
  16. Vermillion JM, Abernathy SW, Snyder SK. Laproscopic reduction of Amyands hernia. *Hernia* 1999;3:159-160.
  17. Rehman MR, Panteli C, Tsang T. Laparoscopic repair of Amyands hernia in an eight year old infant. *Hernia* 2010;14:443-445.
- 
-