



## Accessory splenic artery from left gastroepiploic artery

Published online August 9th, 2010 © <http://www.ijav.org>

Padmalatha K<sup>+</sup>  
BR Ramesh  
Prakash BS  
Balachandra N  
Mamatha Y

Department of Anatomy, Dr. B.R. Ambedkar Medical College, Bengaluru, Karnataka, INDIA.



+ Dr. Padmalatha K, MD, DNB  
Assistant Professor of Anatomy  
Dr. B.R. Ambedkar Medical College  
K.G. Halli, Bengaluru, Karnataka, INDIA.  
☎ +91 988 6588482  
✉ [padma.anat@yahoo.in](mailto:padma.anat@yahoo.in)

Received November 28th, 2009; accepted July 10th, 2010

### ABSTRACT

Splenic artery is the largest branch of celiac axis and its course is among the most tortuous in the body. We describe a rare variation of accessory splenic artery originating from the left gastroepiploic artery. Knowledge of variations of splenic artery is essential to successfully accomplish surgical, oncologic or any interventional procedures. © IJAV. 2010; 3: 106–107.

**Key words** [splenic artery] [accessory splenic artery] [left gastroepiploic artery] [celiac axis] [spleen]

### Introduction

Splenic artery is the largest branch of celiac axis. It usually divides into two or three main branches before entering the hilum of spleen. As these branches enter the hilum, they divide further into four or five segmental arteries. These vessels each supply a segment of splenic tissue [1].

### Case Report

We describe a rare variation in the occurrence of accessory splenic artery, which took origin from the left gastroepiploic artery during routine educational dissection of a 50-year-old male cadaver of Asian origin in our department. Splenic artery divided into two segmental branches before reaching hilum and each segmental branch further gave two to three branches. Further an accessory splenic artery to the lateral end of spleen was noticed, which took origin from left gastroepiploic artery (Figure 1).

### Discussion

The anatomical variations of splenic artery are due to unusual embryological development of ventral splanchnic arteries [1].

There are two types of spleen associated with different types of branching of splenic artery: compact/magistral splenic (30%), and distributing/segmental splenic (70%) [2].

Michels reported two cases in which splenic artery taking the origin from celiac axis. Branching of splenic artery into two terminal divisions anywhere within 1–12 cm were described as polar arteries.

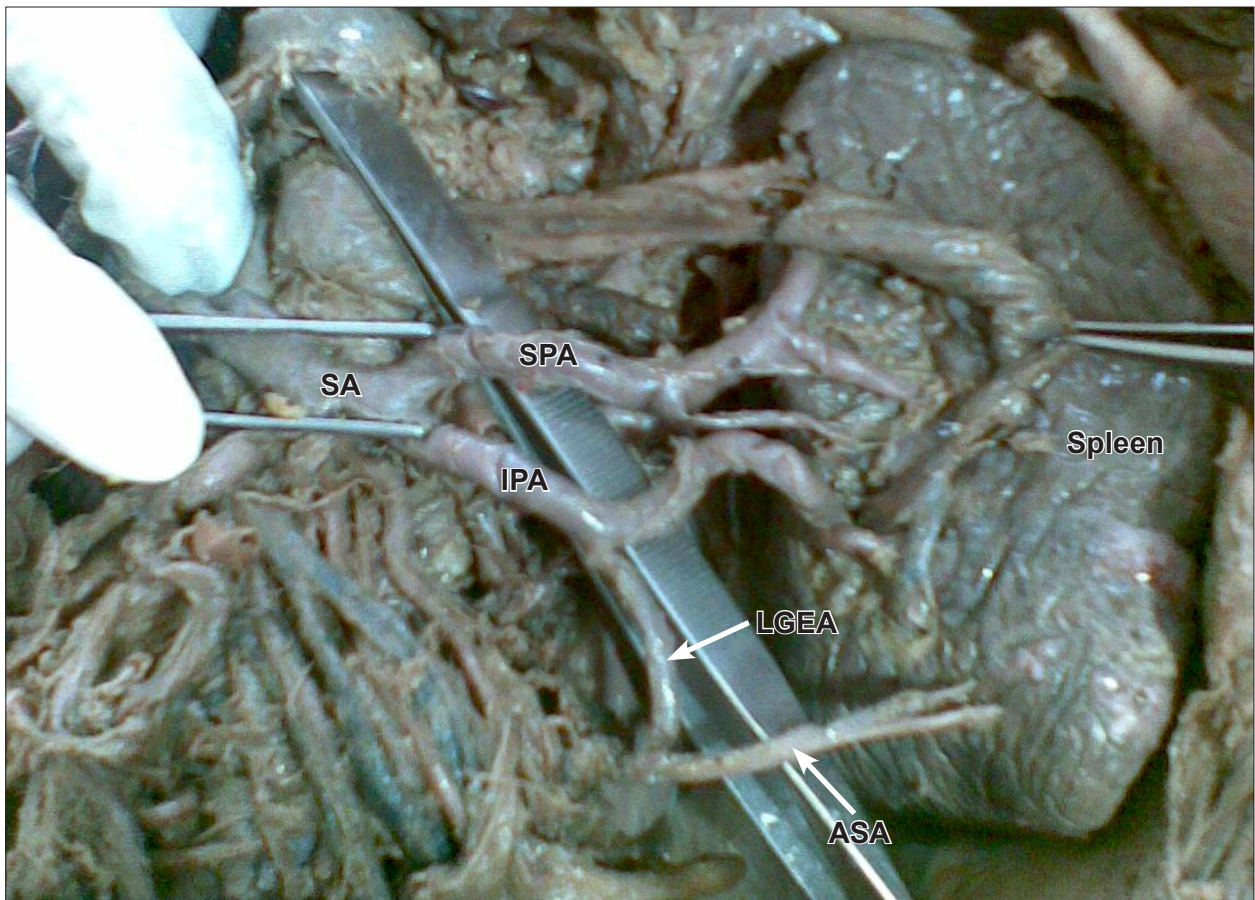
Left gastroepiploic artery took the origin from splenic trunk (72%), inferior polar artery (22%) and superior polar artery (6%) [3].

In the study of Holibkova, segmental branches of splenic artery were involved in three types of anastomosis; as hilar extraparenchymatous, intraparenchymatous and subcapsular. The embryological explanation for an accessory splenic artery is most probably due to intraparenchymatous anastomosis between the inferior polar artery of splenic artery and the splenic branches of branches of left gastroepiploic artery [4].

Knowledge of variations of splenic artery is of extreme clinical importance while performing Appleby procedure that is total pancreatectomy in case of carcinoma of pancreas body and tail [5].

Vascular anomalies are usually asymptomatic; they may become important in patients undergoing diagnostic angiography for gastrointestinal bleeding/transcatheter therapy [6].

Surgeons must have a knowledge regarding branching pattern of splenic artery or else there is a possibility of dangerous bleeding if damaged.



**Figure 1.** Accessory splenic artery arising from left gastroepiploic artery. (SA: splenic artery; SPA: superior polar artery; IPA: inferior polar artery; LGEA: left gastroepiploic artery; ASA: accessory splenic artery)

## References

- [1] Standring S, ed. *Gray's anatomy: Anatomical basis of clinical practice*. 39th Ed., London, Elsevier Churchill-Livingstone. 2005; 1241.
- [2] Hollinshead WH. *Anatomy for surgeons*. 3rd Ed., Philadelphia, Harper & Row Publishers. 1982; 444–449.
- [3] Michels NA. The variational anatomy of the spleen and splenic artery. *Am J Anat*. 1942; 70: 21–72.
- [4] Holibkova A, Machalek L, Houserkova D, Ruzicka V. A contribution to the types of branching and anastomoses of the splenic artery in human spleen. *Acta Univ Palacki Olomuc Fac Med*. 1998; 141: 49–52.
- [5] Kimura W, Han I, Furukawa Y, Sunami E, Futakawa N, Inoue T, Shinkai H, Zhao B, Muto T, Makuuchi M, Komatsu H. Appley operation for carcinoma of the body and tail of the pancreas. *Hepatogastroenterology*. 1997; 44: 387–393.
- [6] Yalcin B, Kocabiyik N, Yazar F, Ozan H, Ozdogmus O. Variations of the branches of the celiac trunk. *Gulhane Tip Dergisi*. 2004; 48: 163–165.