



## Accessory spleen supplied by gastric artery - rare case

Published online October 31st, 2015 © <http://www.ijav.org>

R. Nithiya PRIYA  
S. KALAIYARASI  
T. SIVAKAMI \*

Department of Anatomy, Thanjavur Medical College,  
Thanjavur, Tamil Nadu, INDIA.



\* Dr. T. Sivakami, MBBS, MS  
74, 6th Street, Balaji Nagar,  
Mc Road, Thanjavur  
Tamil Nadu, 613007, INDIA.  
☎ +91 9360562226  
✉ [tnjanat@gmail.com](mailto:tnjanat@gmail.com)

Received April 21st, 2014; accepted August 8th, 2014

### Abstract

Accessory spleen or splenunculus is a congenital ectopic tissue with incidence rate ranging from 10-30% in autopsy series. Most commonly situated near splenic hilum and supplied by splenic artery. Developmentally, it is due to failure of fusion of splenic nodules in the dorsal mesogastrium. Although most of the time it is an incidental finding, awareness of its presence is important since it may mimic lymphadenopathy and tumor during diagnostic procedures. We report a rare case of accessory spleen in the posterior wall of omental bursa with vascular supply from left gastric artery.

© *Int J Anat Var (IJAV)*, 2015; 8: 23–25.

**Key words** [accessory spleen] [left gastric artery]

### Introduction

The spleen is a large lymphoid organ in the left upper quadrant of the abdomen between the fundus of the stomach and diaphragm. During sixth week of development, splenic nodules appear in between leaflets of dorsal mesogastrium at the cranial end and coalesce. With the rotation of stomach, the developing spleen shifts to left and remains attached to the omental bursal wall only at the hilum by its ligaments. The left surface of dorsal mesogastrium fuses with the peritoneum covering the left kidney. Hence splenic artery, the largest branch from celiac trunk lies in front of the left kidney and behind the peritoneum [1].

Accessory spleen may be formed due to failure of fusion of splenic nodules in the dorsal mesogastrium and it may present from the midline to its final location on the left upper quadrant [2].

### Case Report

During routine dissection of a 70-year-old male cadaver in the Department of Anatomy, Thanjavur Medical College, we found an oval shaped encapsulated mass of size 5x3 cm in the posterior wall of omental bursa, in front of the left kidney medial to spleen (Figure 1). In the present case, the mass

was supplied by two small branches each of diameter 0.5 cm from the left gastric artery (Figure 2). Thin band of similar tissue connected the mass to the hilum of spleen (Figure 1). Splenic artery and its branches were normal. The histological study of the mass and thin band showed splenic architecture (Figure 3).

### Discussion

Variations of spleen include complete agenesis, polysplenia, accessory spleen and persistent lobulations. Among which the accessory spleen is more common. One or more accessory spleens may develop prenatally near the splenic hilum, embedded partly or wholly in the tail of pancreas, between the layers of gastrosplenic ligament, in the infracolic compartment, in the mesentery or in close proximity to an ovary or testes [3]. These additional collection of fully functional splenic tissue are usually present as isolated nodules but may be connected to the spleen by thin band of similar tissue.

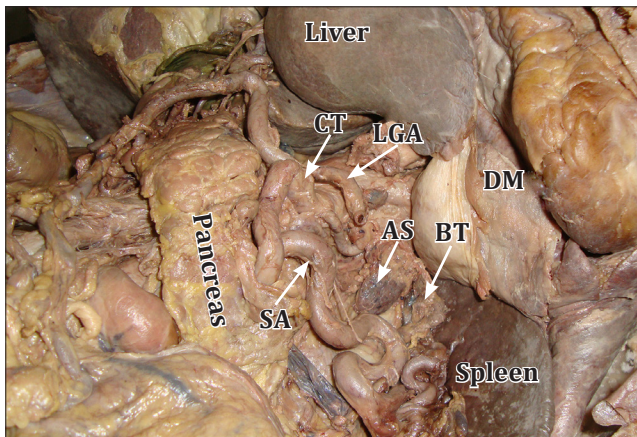
According to Dogan et al., incidence of one accessory spleen in splenic hilum is common. The diameter of accessory spleen in his study is 0.5-2.8 cm [2]. Mohan et al. reported three cases of accessory spleen, all of size lesser than 2 cm in diameter

[4]. Moretele et al. performed contrast enhanced abdominal CT scans for 1000 consecutive patients and found accessory spleen in 156 (15.6%). In CT, accessory spleen appeared as well marginated round mass <2 cm, most frequently located anterolateral to left kidney and near tail of pancreas. They were able to demonstrate the vascular supply from splenic artery in 67 patients [5]. In the present case, the size of accessory spleen is 5x3 cm which is quite large to best of our knowledge (Figure 1).

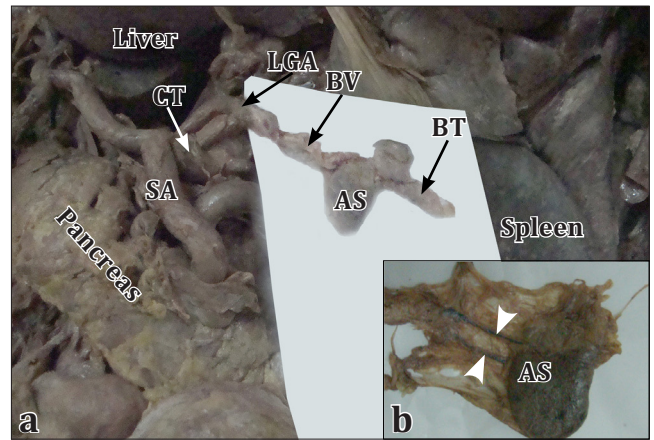
Souparis et al. reported an unusual case of retroperitoneal accessory spleen with blood supply directly from aorta [6]. Michels reported an accessory spleen in gastrophrenic ligament supplied by accessory left gastric artery from splenic artery [7]. In the present case, the accessory spleen is supplied by two small branches from left gastric artery, which is not reported in the literature (Figure 2).

This congenital ectopic splenic tissue needs to be differentiated from the acquired condition splenosis which is usually associated with splenic trauma or previous splenectomy. It presents as 100 or more splenic nodules both in intraperitoneal or extraperitoneal location deriving its blood supply from adjacent tissues and vessels. Histologically, the splenosis shows distorted splenic architecture with lack of malphigian follicles and central arteriole. In our case, it presents as mass in the posterior wall of omental bursa, in front of left kidney with a thin band of similar tissue connecting it to the spleen. The histological section of the mass and thin band of tissue shows the splenic architecture with malphigian follicle and central arteriole (Figure 3).

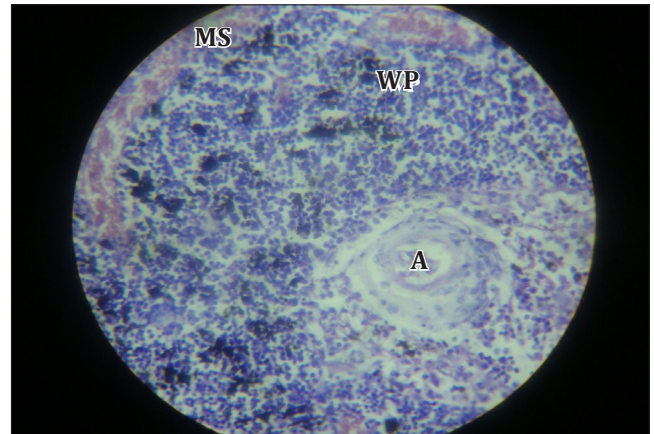
Accessory spleen is usually asymptomatic, but it may cause acute abdominal pain due to torsion and infarction especially in young children and women of reproductive age. Awareness of its presence is important, since it may mimic lymphadenopathy and tumor in other organs like pancreas,



**Figure 1.** Figure shows *accessory spleen (AS)* and *band of splenic tissue (BT)* in the posterior wall of omental bursa after the removal of stomach. (CT: celiac trunk; LGA: left gastric artery; SA: splenic artery)



**Figure 2. a)** Blood supply of *accessory spleen (AS)* from *left gastric artery (LGA)* on white background. (BT: band of splenic tissue; BV: blood vessel). **b)** Encapsulated *accessory spleen (AS)* with *tiny blood vessels (white arrowheads)*.



**Figure 3.** Hematoxylin & Eosin staining of accessory spleen in 40x view showing *white pulp (WP)*. (A: arteriole; MS: marginal sinus)

kidney and adrenal gland during diagnostic procedures. It is important to surgeon while doing splenectomy when the intension is to remove all functional splenic tissue as in hematological diseases and to preserve it when the splenectomy is done for non-hematological causes, since the accessory spleen resembles normal spleen in structure and its immunological function. Hence it is important to diagnose the accessory spleen prior to splenectomy either by CT scan or by heat-denatured erythrocyte scan [2, 4, 5].

## References

- Standring S, ed. *Gray's Anatomy. The Anatomical Basis of Clinical Practice*. 40th Ed., New York, Elsevier Churchill Livingstone. 2008; 1191–1195, 1218.
- Unver Dogan N, Uysal II, Demirci S, Dogan KH, Kolcu G. Accessory spleens at autopsy. *Clin Anat*. 2011; 24: 757–762.

- 13] Moore KL, Persaud TVN. *The Developing Human. Clinically Oriented Embryology*. Philadelphia, Elsevier Saunders. 2003; 266.
- 14] Mohan H, Amanjit, Bhardwaj S, Handa U. Splenunculi — Report of three cases. *J Anat Soc India*. 2002; 51: 70—71.
- 15] Mortele KJ, Mortele B, Silverman SG. CT features of the accessory spleen. *AJR Am J Roentgenol*. 2004; 183: 1653—1657.
- 16] Souparis A, Papaziogas B, Alexandrakis A, Koutelidakis J, Paraskevas G, Papaziogas T. An unusual case of retroperitoneal accessory spleen with vascular supply directly from aorta. *Minerva Chir*. 2002; 57: 513—515.
- 17] Michels NA. *Blood Supply and Anatomy of the Upper Abdominal Organs With a Descriptive Atlas*. Philadelphia, J.B. Lippincott. 1955; 46—47.

