



A variation of the palmaris profundus muscle

Published online February 28th, 2010 © <http://www.ijav.org>

M. Elena STARK ⁽¹⁾
 Maria M. DELL ⁽²⁾
 Jonathan J. WISCO ⁽¹⁾ +

David Geffen School of Medicine at UCLA, Department of Pathology and Laboratory Medicine, Division of Integrative Anatomy, Los Angeles ⁽¹⁾ and Santa Monica College, Department of Life Sciences, Santa Monica ⁽²⁾, California, USA.



+ Jonathan J. Wisco, Ph.D.
 David Geffen School of Medicine at UCLA
 Department of Pathology and Laboratory Medicine
 Division of Integrative Anatomy
 10833 Le Conte Ave., Room 52-060 CHS
 Los Angeles, CA 90095-1732, USA.
 ☎ +1 310 825-7880
 ✉ jjwisco@mednet.ucla.edu

Received October 16th, 2009; accepted February 26th, 2010

ABSTRACT

During routine anatomical dissection of the anterior compartment of the forearm region, a tendinous-musculo-tendinous muscle was found on the right forearm originating from the medial aspect of the radial shaft and inserting into the palmar aponeurosis. The muscle coursed deep to pronator teres muscle, parallel and lateral to the flexor digitorum superficialis muscle and deep to the tendon of the flexor carpi radialis. Distally, the muscle tendon coursed under the flexor retinaculum and it was invested with the median nerve by a common fascial sheath. The muscle was found in the presence of an intact palmaris longus muscle. Because of its attachments and course, the muscle was classified as a palmaris profundus muscle. Several subtypes of palmaris profundus muscles have been reported. To our knowledge this is the first case of a palmaris profundus with a tendon originating from the medial aspect of the radial diaphysis, a muscular portion and a distal tendon inserting in the palmar aponeurosis. Anatomical variations of muscles in the flexor compartment of the forearm may have functional, diagnostic, and surgical implications. © *IJAV*. 2010; 3: 36–38.

Key words [palmaris profundus muscle] [flexor compartment of the forearm] [variant of musculus comitans nervi mediani] [anatomical variation]

Introduction

Palmaris profundus has been described as a muscle arising from the lateral edge of the radius, coursing lateral to flexor digitorum superficialis and deep to pronator teres, and having a tendon that passes beneath the flexor retinaculum and broadens in the palm of the hand to insert into the deep side of the palmar aponeurosis [1]. Palmaris profundus has also been called musculus comitans nervi mediani because the tendon of palmaris profundus and the median nerve are often invested in a common sheath of connective tissue. Palmaris profundus was first described by Frohse and Fraenkel in 1908 [2]. Palmaris profundus has been found in the presence and in the absence of palmaris longus, and multiple variations have been described in the literature. A recent review by Pirola et al. [3] proposed three main subtypes of palmaris profundus based on its origin from (1) the radius, (2) the flexor digitorum superficialis fascia, and (3) from the ulna. Other origins are reported in the literature including a common flexor origin [4], the epymisium of the flexor pollicis longus [5,6] and the palmaris longus [7]. All of these subtypes are described as consisting of a muscular portion and a distal tendon, which may be reversed, except for Sanchez-Lorenzo's report [7] which describes a variation of palmaris profundus with a proximal, a distal tendon and a belly in the center. In Sanchez-Lorenzo's variation the proximal tendon attaches to the palmaris longus and the distal tendon attaches to the palmar aponeurosis. This paper describes a case of a variation of

the palmaris profundus muscle with a proximal tendon attached to the antero-medial shaft of the radius and a musculo-tendinous unit with the course and attachment of a typical palmaris profundus. A brief discussion of the clinical significance of this variant muscle is included.

Case Report

During routine anatomical dissection at the David Geffen School of Medicine at UCLA, a palmaris profundus muscle variation was found in a 78-year-old Caucasian male cadaver. This report describes this muscle.

On the right forearm, the cadaver exhibited a typical palmaris longus, pronator teres, flexor digitorum superficialis, flexor carpi radialis and flexor carpi ulnaris muscles. The other flexor muscles (of the deep anterior compartment) were also typical. The muscle described in this case report had a proximal and a distal tendon, with a fusiform-shaped belly in the center. The proximal tendon measured 2.9 cm and attached to the antero-medial aspect of the radial diaphysis. The belly measured 10.5 cm and was lateral and deep to the tendon of the flexor carpi radialis and lateral to flexor digitorum superficialis muscle. The distal tendon started at the level of the flexor retinaculum, it measured 5 cm and it was invested with the median nerve by a common fascial sheath. Otherwise, the median nerve did not differ from its typical presentation. The distal tendon coursed, with the median nerve, deep to the flexor retinaculum and inserted into the palmar aponeurosis, deep to the insertion of palmaris longus. Because of its attachments

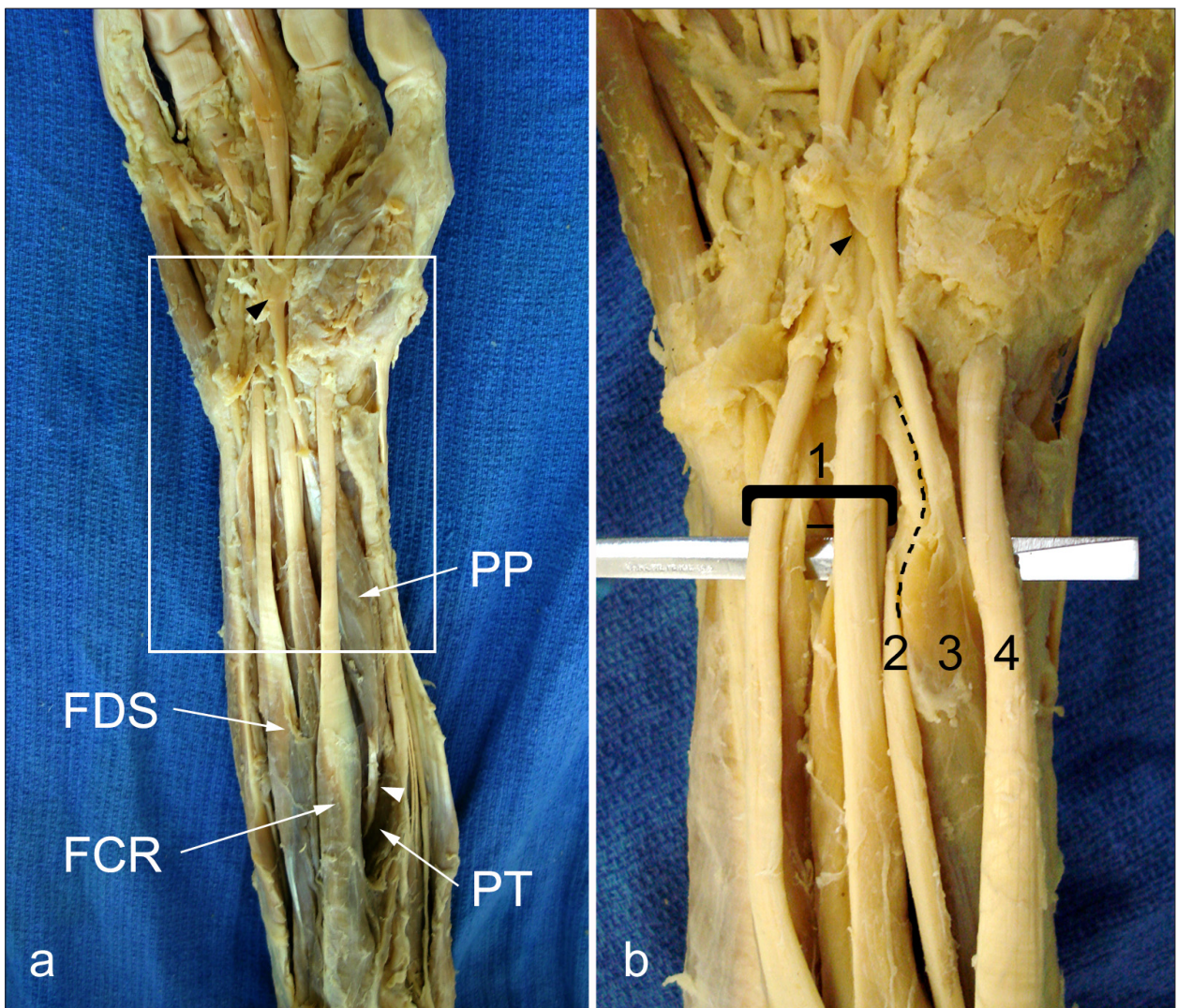


Figure 1. Palmaris profundus muscle variation. Enlarged picture of box in (a) is shown in (b). Note the proximal tendon [white arrowhead (a)] attaching to the medial aspect of the radius deep to the pronator teres muscle and the distal tendon [black arrowhead (a and b)] investing with the palmar aponeurosis. After removal of the flexor retinaculum, the palmaris profundus muscle was observed to be ensheathed with the median nerve. In (b), the fascia surrounding tendons has been removed and the tendons and median nerve are lifted anteriorly for visualization. (FDS: flexor digitorum superficialis muscle; 1: flexor digitorum superficialis tendons; 2: median nerve; PP: palmaris profundus muscle; 3: palmaris profundus tendon; FCR: flexor carpi radialis muscle; 4: flexor carpi radialis tendon; PT: pronator teres muscle). Dotted line demarcates the median nerve from the palmaris profundus muscle tendon.

and course this muscle was classified as a palmaris profundus and because of its tendinous origin attached to the antero-medial radial shaft, it constitutes a variation, to our knowledge, previously not described in the literature (Figure 1). No other muscular or neurovascular abnormalities were observed.

Discussion

Multiple variations of palmaris profundus muscle have been described. We describe a case of a variation with a proximal tendon originating in the antero-medial diaphysis of the radius. To our knowledge, this is the first reported case of such a variation. The radial shaft has been described as one of the possible origins of palmaris profundus, however variations with such origin found in the literature refer to a muscular origin. The

muscle described in this paper mostly resembles the one by Sanchez-Lorenzo [7], as it has a proximal and a distal tendon with a small belly in between. However the muscle described by Sanchez-Lorenzo originated by a tendon from the palmaris longus, whereas the variation described here had its origin in the antero-lateral shaft of the radius.

Variations of the muscles in the flexor compartment of the forearm, including variations of the palmaris profundus have been implicated, in the proximal forearm, as a cause of compressive neuropathy of the anterior interosseous nerve syndrome and, in the distal forearm and wrist, as a cause of compression of the median nerve and/or its branches which may present as carpal tunnel syndrome. Knowledge of potential abnormalities in the region is important for any physician or hand and wrist surgeon.

Acknowledgments

Our thanks to the generosity of the whole body donors provided by the UCLA Donated Body Program.

References

- [1] Bergman RA, Thompson SA, Afifi AK, Saadeh FA. *Compendium of human anatomical variation: text, atlas and world literature*. Baltimore, Urban and Schwarzenberg. 1988; 282–288.
- [2] Reimann AF, Daseler EH, Anson BJ, Beaton LE. The palmaris longus muscle and tendon. A study of 1600 extremities. *Anat Rec*. 1944; 89: 495–505.
- [3] Pirola E, Hébert-Blouin MN, Amador N, Amrami KK, Spinner RJ. Palmaris profundus: one name, several sybtotypes, and a shared potential for nerve compression. *Clin Anat*. 2009; 22: 643–648.
- [4] Sahinoglu K, Cassell MD, Miyauchi R, Bergman RA. Musculus comitans nervi mediani (M. palmaris profundus). *Ann Anat*. 1994; 176: 229–232.
- [5] Yoshida Y, Yasutaka S, Seki Y. Flexor radialis profundus and palmaris profundus muscles in man. *Kaihogaku Zasshi*. 1983; 58: 59–67. (Japanese)
- [6] Chou HC, Jeng H, Ko TL, Pai MH, Chang CY, Wu CH. Variant palmaris profundus enclosed by an unusual loop of the median nerve. *J Anat*. 2001; 198: 499–500.
- [7] Sanchez Lorenzo J, Canada M, Diaz L, Sarasua G. Compression of the median nerve by an anomalous palmaris longus tendon: a case report. *J Hand Surg Am*. 1996; 21: 858–860.