



A tubercle at the anterior margin of foramen magnum

Published online June 27th, 2011 © <http://www.ijav.org>

Prakash BS ⁺
Padma Latha K
Jagdish L. MENDA
Ramesh BR

Department of Anatomy, Dr. B. R. Ambedkar Medical College, Bengaluru, Karnataka, INDIA.



⁺ Dr. Prakash BS, MD
Associate Professor
Department of Anatomy
Dr. B.R. Ambedkar Medical College
Bengaluru, Karnataka, INDIA.
☎ +91 944 8782573
✉ prakash.drbsp@yahoo.in

Received August 18th, 2010; accepted May 24th, 2011

ABSTRACT

Anomalies around the foramen magnum are of clinical importance, closely related to nervous and vascular structures. In one of the skull, a tubercle was found at the anterior margin of foramen magnum projecting into foramen magnum, formed of exostoses in the apical ligament of dens. Could be one of the “manifestation of occipital vertebra”. This tubercle is not comparable from a phylogenetic point of view, to the medial condyle of birds and reptiles, as it does not participate as an articular surface in cranio-vertebral joint. Position of this tubercle may be related to traumatic medullar lesions of occipito-vertebral region. © IJAV. 2011; 4: 118–119.

Key words [foramen magnum] [tubercle]

Introduction

Skull is the bony skeleton of the head and is the most complex osseous structure in the body. It is the modified part of the axial skeleton. The skull is supported by articulation with the vertebral column [1].

Case Report

We describe a variation in the anterior margin of foramen magnum. A single median tubercle situated at the anterior margin of foramen magnum (basion), with the apex facing backwards into the foramen magnum. The tubercle measured, 5 mm antero-posteriorly and 3 mm transversely (Figure 1).

Discussion

The basilar process of occipital bone is formed by fusion of the first three primitive vertebrae (or occipitoblasts), the most caudal of which is so-called occipital vertebra or pro-atlas [2].

The failure of distal occipitoblasts to fuse with others gives rise to abnormal bone formations on the external surface of skull around foramen magnum, phenomenon called as “manifestation of occipital vertebra” [2].

Manifestation of occipital vertebra, ossified fragments which, when imbedded in the ligamentous tissue, appear on radiologic examination as an isolated foci between the atlas and the occipital bone [2].

The separate bone elements are only partly attributable to the occipital vertebra, because findings due to secondary ossification in the ligaments have been observed [2].

Tubercles are formed by exostoses. Albrecht designates – all elements of cranio-vertebral articulation including intraligamentous ossification as “pro-atlas” vertebra. The apical ligament of dens, which forms part of this pro-atlas region, occasionally contains rudiments of notochord within it [3].

Manifestation of an occipital vertebra is a regressive in contradistinction, to a progressive change represented by an assimilation of the atlas into the base of skull. The junction of skull and spinal column is not an absolutely fixed point in ontogeny any more than a phylogeny [4].

An anomaly at the foramen magnum has been attributed to occipitalization of the atlas or assimilation of the atlas to the occipital bone. Assimilation seemed to be bony continuity between the anterior arch of atlas and the anterior lip of the foramen magnum [5].

Failure of complete disappearance of the hypochondral bridge during development may manifest as osseous formations in this craniocervical transition region. These include the condylus tertius, enlarged lateral masses, labia foraminis magni anteriora, third condyle, basilar processes,

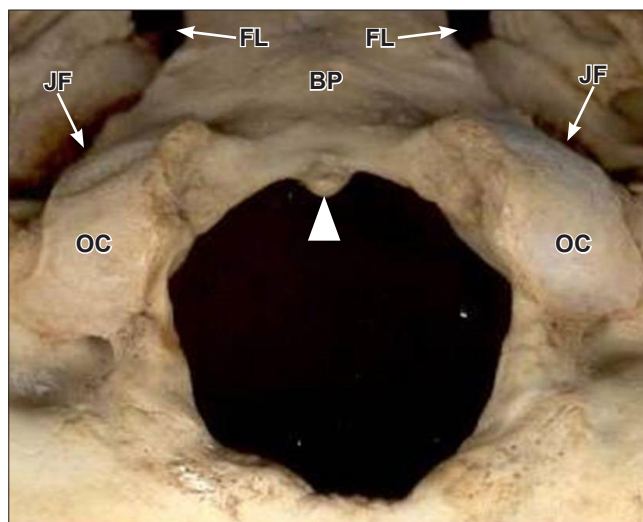


Figure 1. Photograph showing the tubercle at anterior margin of foramen magnum. (*BP*: basilar part occipital bone; *OC*: occipital condyle; *JF*: jugular foramen; *FL*: foramen lacerum; *white arrowhead*: the tubercle)

accessory bone elements separate or fused to the foramen magnum [6].

This tubercle is not comparable from a phylogenetic point of view, to the medial condyle of birds and reptiles, as it does not participate as an articular surface in cranio-vertebral joint [3].

References

- [1] Standring S. *Gray's Anatomy: Anatomical Basis of Clinical Practice*. 39th Ed., London, Elsevier Churchill-Livingstone, 2005; 455–465.
- [2] Lombardi G. The occipital vertebra. *Am J Roentgenol Radium Ther Nucl Med*. 1961; 86: 260–269.
- [3] Vazquez JF, Verona JA, Balbas JA, Porrero MG, Ayucar EB. Tubercle at the foramen magnum. *Skull Base Surg*. 1996; 6: 169–170.
- [4] Shehata R. Occipitalisation of the atlas. *J Anat Soc India*. 1964; 13; 97–99.
- [5] McRae DL, Barnum AS. Occipitalization of the atlas. *Am J Roentgenol Radium Ther Nucl Med*. 1953; 70: 23–46.
- [6] Vasudeva N, Choudhry R. Precondylar tubercles on the basiocciput of adult human skulls. *J Anat*. 1996; 188; 207–210.
- [7] Berry AC. Factors affecting the incidence of non-metrical skeletal variants. *J Anat*. 1975; 120; 519–535.
- [8] Lakhtakia PK, Preamsagar IC, Bisaria KK, Bisaria SD. A tubercle at the anterior margin of foramen magnum. *J Anat*. 1981; 177: 208–210.
- [9] Stoessiger, Morant. *Hythe crania*. *Biometrika*. 1932; 13; 13.

The chief factor governing the expressions of these variants was the genetic make-up of the individual and the minor skeletal variants were under complex multigenic control [7]. Bony tubercle occurring at the margins of foramen magnum can cause compression of the spinal medulla, because of close relation of bony, vascular and nervous elements of cranio-vertebral junction, any malformation of one tissue may produce a variety of signs and symptoms of neurological deficits.

Small bony tubercle on the anterior margin of the foramen magnum indicates the position of the apical ligament of dens. Tubercles directed posteriorly into the foramen magnum are, perhaps, liable to injure the pyramidal fibers in extreme flexion of the head [8]. The frequency of tubercles at foramen magnum has been reported as 0.8 to 1.5% by numerous authors [3, 8, 9].

Position of tubercle may be related to traumatic medullar lesions of occipito-vertebral region. Existence of these types of tubercles in Albright's osteodystrophy [5].

Tubercle on the anterior margin of the foramen magnum indicates the position of the apical ligament of dens formed of exostoses. Could be one of the "Manifestation of occipital vertebra", this tubercle is not comparable from a phylogenetic point of view, to the medial condyle of birds and reptiles, as it does not participate as an articular surface in cranio-vertebral joint. Position of this tubercle may lead to traumatic medullar lesions of occipito-vertebral region.