



## A report of unusual origin of right renal artery

Published online May 11th, 2011 © <http://www.ijav.org>Belgin BAMAC<sup>(1)</sup>Tuncay COLAK<sup>(1)</sup> +Aydın OZBEK<sup>(1)</sup>Umit Naci GUNDOGMUS<sup>(2)</sup>

Departments of Anatomy [1] and Forensic Medicine [2], Kocaeli University, Kocaeli, TURKEY.



+ Dr. Tuncay Colak  
Associate Professor  
Kocaeli University  
School of Medicine  
Department of Anatomy  
Umuttepe, 41380, Kocaeli, TURKEY.  
☎ +90 262 3037251  
✉ [tuncayc@kocaeli.edu.tr](mailto:tuncayc@kocaeli.edu.tr)

Received December 27th, 2010; accepted May 3rd, 2011

### ABSTRACT

During evaluation of abdominal aorta in the serial forensic autopsy cases in the Istanbul Forensic Medicine Institute Morgue, we observed a variation in the origin of the right renal artery in a 49-year-old woman who died of external cause. In this case the right renal artery originated from the superior mesenteric artery. On the left side, the left renal artery arose from the aorta. Clinical significance and embryonic development of this variation have been discussed briefly and a short overview of the literature was given. © IJAV. 2011; 4: 95–97.

**Key words** [renal artery] [variation]

### Introduction

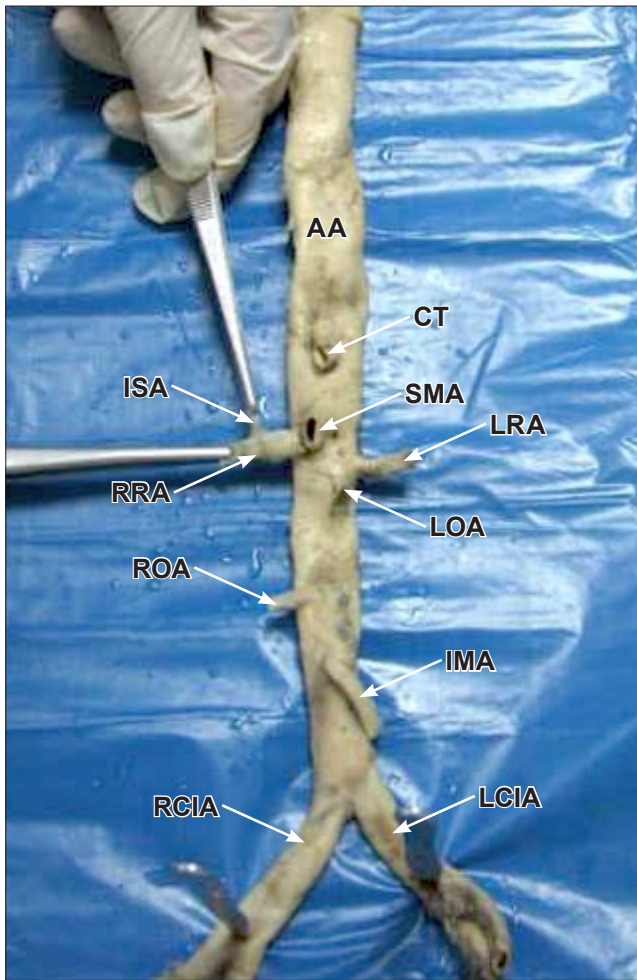
Variations of morphology of the aorta and its branches are of considerable interest as vessel geometry not only determines flow dynamics, but is also crucial in the pathogenesis of vascular diseases, e.g., atherosclerosis and aneurysm formation [1]. The relationship between the anterior visceral and renal arteries is important when undertaking diagnostic arteriography and endovascular interventions [2]. The superior mesenteric artery (SMA) usually arises below the celiac artery with its ostium being inferior and right lateral. The most common variant of the SMA is associated with a right hepatic artery originating from the SMA [3]. A single renal artery to each kidney is present in about 70% of individuals but they vary in their level of origin (the right often being superior) and in their caliber, obliquity and precise relations [4]. Accessory renal arteries are the most common renal vascular variant (30% of individuals). Unusual origin of the renal arteries and its clinical importance has been reported before. We encountered a rare variation of the right renal artery (RRA) originating from the SMA. Clinical significance and embryonic development of this variation have been discussed briefly and a short overview of the literature was given.

### Case Report

During evaluation of abdominal aorta in the serial forensic autopsy cases in the Istanbul Forensic Medicine Institute Morgue, we observed a variation in the origin of the right renal artery in a 49-year-old woman who died of external cause. The abdominal aorta was dissected above the coeliac trunk and below the aortic bifurcation and removed from the body. In this case, the right renal artery originated from the superior mesenteric artery. On the left side, the left renal artery arose from the aorta. The distance between the superior margin of the left renal artery (LRA) and SMA was 6.10 mm. The internal diameters of each renal artery were measured as close to its origin as possible. Measurements were taken using a digital caliper. The diameters of the left and right renal artery were 3.42 mm and 5.26 mm, respectively. The diameter of the superior mesenteric artery was 8.21 mm. Internal aortic diameter decreased from 16.44 mm at the level of the 0.5 cm above the SMA to 12.08 mm at the level of the 0.5 cm below the SMA (Figure 1). The other body structures were unremarkable and the right and left kidneys were in their usual position, relations and appearance.

### Discussion

We could not find any paper, concerning this variation, where a single RRA arising as a branch from the SMA.



**Figure 1.** Dissection showing the right renal artery originating from the superior mesenteric artery. (AA: abdominal aorta; CT: celiac trunk; SMA: superior mesenteric artery; ISA: inferior suprarenal artery; RRA: right renal artery; LRA: left renal artery; LOA: left ovarian artery; ROA: right ovarian artery; IMA: inferior mesenteric artery; LCIA: left common iliac artery; RCIA: right common iliac artery)

Unusual origins of renal arteries include single RRA arising in a common trunk with the SMA [5], origin of the RRA from the iliac artery in horseshoe kidney [6], a LRA arising from the splenic artery [7], a single supernumerary left polar artery from the inferior mesenteric artery (IMA)[8], a common origin of the IMA and anomalous left lower polar renal artery with horseshoe kidney [9], a right accessory renal artery originating as a common trunk with the IMA [10], an accessory renal artery arising from the left common iliac artery supplied the lower end of the left kidney [11] and an accessory renal artery sharing its origin with the IMA supplied the left kidney [12].

The SMA is the vessel of the midgut and has not been described to give rise into a renal artery. The possible embryonic development of this branching can be explained by the growth of ventral and lateral splanchnic arteries.

Each primitive dorsal aorta gives off ventral splanchnic arteries (paired segmental branches to the digestive tube), lateral splanchnic arteries (paired segmental branches to the mesonephric ridge) and somatic arteries. Ventral splanchnic arteries are reduced to three: the coeliac trunk and superior and inferior mesenteric arteries. The renal artery arises from the most caudal of the lateral splanchnic arteries [4]. The kidneys begin to develop in the pelvic cavity and during this time they receive blood from the neighboring vessels and therefore their blood supply changes sequentially as they ascend to occupy the adult position in the abdomen [8, 13]. It is possible that during embryonic development the right kidney received a branch from the superior mesenteric artery and it persisted as the main artery of the right kidney.

The observed diameters of the renal artery and SMA in this case were similar to that reported by Pennington and Soames [2] and Turba et al. [14]. A number of studies have shown that the diameter of the abdominal aorta decreased progressively from proximal to distal along its length [1, 2]. The present observation is comparable with these reports and the diameter of the aorta at the level of the SMA in our case was similar to that reported by Fleischmann et al. [1]. In our case, the diameters of both right and left renal arteries were within the normal range, in spite of the right one arose from the SMA.

The relationship between the SMA and the renal ostia, as well as variations in renal artery morphology and morphometry are important when undertaking diagnostic renal arteriography and endovascular interventions, such as balloon angioplasty and endoluminal stenting [15]. The successful implantation of a renal stent requires precise knowledge of the orientation of the origin of the renal arteries from the aorta in order to position the stent perpendicular to the ostium of the artery to facilitate its introduction [15].

Injury to the SMA during nephrectomy is a rare but potentially catastrophic complication. Failure to recognize and repair an SMA injury will result in ischemic bowel and death for most patients [16]. If a single main renal artery originates from the SMA, it is likely to increase the risk of a sudden occlusion of artery after surgery. This kind of variation may affect the blood circulation of the kidney, and may cause damage to the tissues of the kidney, and/or high blood pressure.

Detailed knowledge of the presence of potential variations in renal arterial anatomy is important for successful surgical management during renal transplantation, repair of renal artery aneurysm, angiographic interventions and endovascular repair of isolated superior mesenteric artery dissection.

## References

- [1] Fleischmann D, Hastie TJ, Danneberg FC, Paik DS, Tillich M, Zarins CK, Rubin GD. Quantitative determination of age-related geometric changes in the normal abdominal aorta. *J Vasc Surg.* 2001; 33: 97–105.
- [2] Pennington N, Soames RW. The anterior visceral branches of the abdominal aorta and their relationship to the renal arteries. *Surg Radiol Anat.* 2005; 27: 395–403.

- [3] Baden JG, Racey DJ, Grist TM. Contrast-enhanced three-dimensional angiography of the mesenteric vasculature. *J Magn Reson Imaging*. 1999; 10: 369–375.
- [4] Williams PL, Bannister LH, Berry MM, Collins P, Dyson M, Dussek JE, Ferguson MWJ. *Gray's Anatomy*. 38th Ed., New York, Churchill Livingstone. 1995; 318,1826.
- [5] Dalcik C, Colak T, Ozbek A, Dalcik H. Unusual origin of the right renal artery: a case report. *Surg Radiol Anat*. 2000; 22: 117–118.
- [6] Degani S, Leibovitz Z, Shapiro I, Ohel G. Variations of the origin of renal arteries in the fetus identified on power Doppler and 3D sonography. *J Clin Ultrasound*. 2010; 38: 59–65.
- [7] Kruyt RH. Vascularization of left kidney by single vessel originating from splenic artery. *Urology*. 1992; 39: 487–489.
- [8] Cesaze AP. Rare origin of supernumerary renal vessels supplying the lower pole of left kidney. *Ann Anat*. 2007; 189: 53–58.
- [9] Armstrong BG, Hunt TH, Price CW, Resnick MI. Common origin of inferior mesenteric and accessory renal artery. *Urology*. 1979; 14: 298–299.
- [10] Loukas M, Aparicio S, Beck A, Calderon R, Kennedy M. Rare case of right accessory renal artery originating as a common trunk with the inferior mesenteric artery: a case report. *Clin Anat*. 2005; 18: 530–535.
- [11] Jetti R, Jevoor P, Vollala VR, Potu BK, Ravishankar M, Virupaxi R. Multiple variations of the urogenital vascular system in a single cadaver: a case report. *Cases J*. 2008; 1: 344.
- [12] Tisnado J, Amendola MA, Beachley MC. Renal artery originating from the inferior mesenteric artery. *Br J Radiol*. 1970; 52: 752–754.
- [13] Moore KL, Persaud TVN. *The Developing Human: Clinically Oriented Embryology*. 8th Ed., Philadelphia, Saunders. 2008; 243–283.
- [14] Turba UC, Uflacker R, Bozlar U, Hagspiel KD. Normal renal arterial anatomy assessed by multidetector CT angiography: are there differences between men and women? *Clin Anat*. 2009; 22: 236–242.
- [15] Beregi JP, Mauroy B, Willoteaux S, Mounier-Vehier C, Remy-Jardin M, Francke J. Anatomic variation in the origin of the main renal arteries: spiral CTA evaluation. *Eur Radiol*. 1999; 9: 1330–1334.
- [16] Blunt LW Jr, Matsumura J, Carter MF, Gonzalez CM, Smith ND. Repair of superior mesenteric artery ligation during left nephrectomy with a native renal vein patch. *Urology*. 2004; 64: 377–378.